Curr Cardiol Rep (2017) 19: 108
DOI 10.1007/s11886-017-0922-2

VALVULAR HEART DISEASE (T KIEFER, SECTION EDITOR)

Pulmonic Valve Disease: Review of Pathology and Current Treatment Options

Mouhammad Fathallah[1] · **Richard A. Krasuski**[1]

Published online: 16 September 2017

Abstract
Purpose of Review Our review is intended to provide readers with an overview of disease processes involving the pulmonic valve, highlighting recent outcome studies and guideline-based recommendations; with focus on the two most common interventions for treating pulmonic valve disease, balloon pulmonary valvuloplasty and pulmonic valve replacement.
Recent Findings The main long-term sequelae of balloon pulmonary valvuloplasty, the gold standard treatment for pulmonic stenosis, remain pulmonic regurgitation and valvular restenosis. The balloon:annulus ratio is a major contributor to both, with high ratios resulting in greater degrees of regurgitation, and small ratios increasing risk for restenosis. Recent studies suggest that a ratio of approximately 1.2 may provide the most optimal results. Pulmonic valve replacement is currently the procedure of choice for patients with severe pulmonic regurgitation and hemodynamic sequelae or symptoms, yet it remains uncertain how it impacts long-term survival. Transcatheter pulmonic valve replacement is a rapidly evolving field and recent outcome studies suggest short and mid-term results at least equivalent to surgery. The Melody valve® was FDA approved for failing pulmonary surgical conduits in 2010 and for failing bioprosthetic surgical pulmonic valves in 2017 and has been extensively studied, whereas the Sapien XT valve®, offering larger diameters, was approved for failing pulmonary conduits in 2016 and has been less extensively studied.
Summary Patients with pulmonic valve disease deserve lifelong surveillance for complications. Transcatheter pulmonic valve replacement is a novel and attractive therapeutic option, but is currently only FDA approved for patients with failing pulmonary conduits or dysfunctional surgical bioprosthetic valves. New advances will undoubtedly increase the utilization of this rapidly expanding technology.

Keywords Pulmonic valve (PV) · Pulmonic stenosis (PS) · Pulmonic regurgitation (PR) · Balloon pulmonary valvuloplasty (BPV) · Pulmonic valve replacement (PVR) · Transcatheter pulmonic valve replacement (TPVR)

Introduction

The pulmonic valve (PV) is probably the least appreciated and most poorly studied cardiac valve. Its retrosternal location renders it challenging to assess by standard transthoracic echocardiography, the most common modality utilized for its assessment. This aspect is particularly worrisome for younger patients, among whom early diagnosis of right ventricular outflow tract (RVOT) abnormalities can be life-saving. It is well established that the incidence of congenital PV disease significantly exceeds that of acquired cases. With increasing numbers of congenital heart disease patients surviving and thriving into adulthood, it behooves clinicians to have a robust understanding of the pathophysiology of PV disease and be able to recognize when problems occur.

Disorders of the RVOT, PV and suprapulmonic region can disrupt the normal process of PV function and lead to significant hemodynamic compromise. These disorders can present as isolated problems or as part of multi-systemic/multi-

This article is part of the Topical Collection on *Valvular Heart Disease*

✉ Richard A. Krasuski
richard.krasuski@duke.edu

[1] Duke University Hospital, 2301 Erwin Road, Durham, NC 27710, USA

Table 1 Classification of the major diseases that affect the pulmonic valve and their associated lesions

Pulmonary Atresia	Pulmonic Stenosis	Pulmonic Regurgitation	Pulmonic Stenosis or Regurgitation
With an intact ventricular septum; associated with: • Hypoplastic right ventricle and/or hypoplastic tricuspid valve • Atrial septal defect • Coronary anomalies	Valvular: • Dome-shaped Dysplastic (part of Noonan syndrome) • Bicuspid/quadricuspid • Acquired causes	Physiologic (trivial to mild)	Carcinoid heart disease
With a ventricular septal defect (a form of tetralogy of Fallot); associated with: • Major aortopulmonary collateral arteries	Supravalvular (pulmonary arterial stenosis): I) Congenital; associated with: • Alagille syndrome • Keutel syndrome • Congenital rubella • Tetralogy of Fallot • William syndrome	Primary: • Some forms of tetralogy of Fallot (e.g. with absent pulmonic valve) • Acquired causes	Rheumatic heart disease
	II) Acquired/iatrogenic Subvalvular: • Primary infundibular stenosis (part of double chambered right ventricle) • Secondary infundibular hypertrophy (long-standing increase in right ventricular afterload)	Secondary: • Idiopathic pulmonary arterial dilatation • Pulmonary arterial hypertension	Infectious endocarditis Iatrogenic

chamber heart diseases. They are divided into three main categories: atresia, stenosis, and regurgitation. Table 1 lists the various conditions under each category.

Congenital heart diseases can involve the PV either directly or indirectly, the latter being consequent to hemodynamic perturbations or surgical/transcatheter interventions. PV intervention often leaves behind a partly stenotic and/or regurgitant PV that necessitates regular follow up and, not uncommonly, future interventions [1,2••]. While heart surgery has long been the gold standard for treating PV disease, transcatheter approaches are growing in availability and offer less invasive approaches to increasingly complicated patients. In this review, we will focus mainly on pulmonic valve stenosis (PS) and pulmonic valve regurgitation (PR) and review the pathophysiology, diagnosis, and up-to-date treatment options.

Pulmonic Stenosis

PS is primarily a congenital condition. Acquired cases can also occur, but are considerably less common. The latter etiologies include infectious endocarditis, carcinoid heart disease, rheumatic heart disease and iatrogenic causes [1, 3]. Stenosis can occur at the level of the PV, above the PV or below it. Typically, PS occurs as an isolated lesion, but it can also coexist with other congenital heart lesions. Importantly, it is one of the four cardinal features of tetralogy of Fallot (TOF). PS is also part of many syndromes that affect the in-utero development of the PV, including Noonan, 22q11 deletion and Williams syndromes [4–6].

Valvular stenosis is the most common form of PS, accounting for 80 to 90% of cases of right ventricular outflow tract (RVOT) obstruction [7]. It is further divided into three clinically significant morphologies: domed, dysplastic, and bicuspid/multicuspid. All three morphologies are characterized by a narrowed valvular orifice, resulting in the development of a pressure gradient across the valve and a pressure load on the RV.

Dome-shaped PV morphology accounts for 40–60% of valvular PS. It is characterized by bowing of the PV leaflets into the pulmonary trunk caused by incomplete separation of valve cusps, coupled with preserved valvular motion. The leaflets have varying degrees of fibrous thickening and are fused along their commissures. Dilation of the pulmonary artery is frequently present due to the eccentric flow resulting from the stenosis, as well as possible intrinsic connective tissue abnormalities within the pulmonary trunk itself. In fact, many cases of isolated valvular PS are incidentally detected after chest radiography or computed tomography scanning (CT) demonstrate an enlarged main and/or left pulmonary arteries, as most patients remain asymptomatic until narrowing is significant. The predilection for left pulmonary artery dilatation results from its less acute takeoff from the pulmonary trunk.

Dysplastic PV morphology accounts for 20% of valvular PS, and is most commonly seen in patients with Noonan syndrome. PV leaflets are prominently thickened with little or no commissural fusion and limited mobility [8, 9]. Other segments along the RVOT may also be narrowed. PV stenosis in such cases is often severe, requiring intervention during

early childhood. Bicuspid PV is thought to be rare [10] and often associated with other congenital heart anomalies such as TOF [11]. Quadricuspid PV is more likely to be asymptomatic than bicuspid PV, yet pulmonary regurgitation does frequently occur with this morphology [12, 13].

Supravalvular PS can involve single or multiple sites along the main pulmonary artery or any of its branches [14], and lesions vary from focal narrowing to diffuse pulmonary hypoplasia. It is usually associated with variety of different congenital diseases including Alagille and Keutel syndromes, congenital rubella, TOF and Williams syndrome [6, 15–17]. Other causes include prior pulmonary banding and post-surgical complications of Blalock-Taussig, Pott's, Waterston or central shunts, as well as Jatene arterial switch for surgical treatment of d-transposition of the great arteries (d-TGA) [18].

Primary subvalvular (infundibular) PS is caused by diffuse fibromuscular narrowing of the RVOT, and is commonly considered part of the spectrum of double-chambered right ventricle [19]. Isolated cases account for 0.4% of patients with congenital heart disease [20]. More commonly, this condition is found in association with TOF or d-TGA [18, 21]. It is important to note that primary infundibular PS can occasionally be confused with secondary RVOT narrowing resulting from compensatory RV hypertrophy. The latter results from a long-standing increase in RV afterload, and often regresses following afterload normalization [22].

Patients with isolated, mild PS are usually asymptomatic and their probability of long-term survival is similar to the general population [23]. Also, stenosis rarely progresses rapidly, with patients typically maintaining normal functional status through adulthood. With greater degrees of stenosis, symptoms may begin to appear resulting from the decrease in cardiac output. Symptoms most commonly include dyspnea on exertion and fatigue. Since the RV adapts poorly to hemodynamic burden, it usually hypertrophies with more than mild stenosis, and RV diastolic and eventually systolic dysfunction results if stenosis is not relieved [24]. Patients with severe PS most often present during childhood with RV failure and cyanosis, with the latter more common in the presence of interatrial shunting. However, if PS is successfully treated, prognosis is generally excellent [23].

Despite its limitations, echocardiography remains the primary diagnostic test for evaluation of PS [25]. Two- and three-dimensional echo can be helpful in assessing the morphology and location of the stenosis, and in evaluating the size and function of the RV. Continuous wave Doppler velocity measurements estimate the gradient across the PV, with calculations demonstrating close correlation with values simultaneously obtained at cardiac catheterization [26, 27]. Finally, color Doppler can detect and quantify pulmonary regurgitation, which is a common complication in patients having undergone surgical valvotomy or percutaneous balloon valvuloplasty [22, 28, 29]. Newer imaging modalities such as CT and magnetic resonance imaging (MRI) can also provide valuable information about the morphology, location, and grade of the stenosis. CT angiography is additionally useful for assessing the pulmonary arteries and the proximity of the coronary arteries to the valve annulus, whereas MRI can accurately assess degree of regurgitation (regurgitant fraction, regurgitant volume), velocity of flow across the valve, quantitate right ventricular size and systolic function and help to distinguish valvular from dynamic subvalvular stenosis resulting from infundibular hypertrophy [30].

Pulmonic Regurgitation

Incomplete apposition of the PV leaflets results in backflow into the RVOT early in diastole [31]. Trivial or mild PR is a common finding in normal individuals (30% of normal hearts) [32, 33]. Pathologic PR can be classified into primary and secondary causes. Primary causes have considerable overlap with etiologies of PS, including iatrogenic regurgitation, congenital anomalies, infectious endocarditis, rheumatic disease and carcinoid heart disease [25, 34, 35]. While iatrogenic PS itself is not a very common condition, iatrogenic PR is the most common cause of severe regurgitation, occurring after surgical valvotomy, percutaneous valvuloplasty or TOF-related RVOT repair [2, 36, 37]. Congenital PR is most likely to be a component of complex diseases such as TOF with an absent PV [38, 39]. In this case, PR tends to occur with concomitant PS. Secondary causes of PR are the result of pulmonary arterial dilation, either idiopathic or resulting from pulmonary arterial hypertension in patients who have morphologically normal valves [40, 41].

PR is generally better tolerated than aortic regurgitation, and patients can be asymptomatic for years [42]. This can partly be attributed to the low resistance of the pulmonary vasculature, which favors systolic upstream flow of blood towards the pulmonary capillary bed. Moreover, in patients with severe PR and restrictive RV physiology, echo or MRI often show late diastolic forward flow in the pulmonary trunk concomitant with each atrial contraction [30]. This suggests that right atrial contraction helps maintain forward blood flow in these patients. Consequently, even in patients with severe PR, the percentage of regurgitant flow is often less than 50% [43]. This can be further influenced by RV afterload, RV compliance, regurgitant orifice size and duration of diastole [44]. As time passes, however, the RV eventually succumbs to the excess volume load and dilates in an effort to preserve cardiac output [45]. Progressive RV dilation ultimately results in RV dysfunction, decreased exercise tolerance, generation of atrial and/or ventricular arrhythmias and can potentially result in sudden cardiac death [46–49]. As such, the presence of ≥ moderate PR in patients with TOF or in patients post-PV

repair/replacement is the strongest predictor of short- and long-term adverse outcomes [50, 51].

MRI is considered the most accurate method for quantifying PR and assessing its secondary hemodynamic sequelae, including RV dilation and dysfunction [52–55]. Since it does not expose patients to ionizing radiation, MRI can be ideal for regular follow-up of patients at high-risk for disease progression. Additionally, MRI can assess regional wall motion abnormalities, myocardial scar and fibrosis and the function of conduits [56–58]. However, the limited availability of cardiac MRI and its relatively high cost remain limiting factors to its widespread application. Therefore, patients with suspected PR should first be evaluated by echocardiography, which generally confirms the diagnosis, assesses severity and provides information regarding etiology. The reliability of echo as a longitudinal screening tool in patients following TOF repair or valvotomy has nonetheless been challenged by conflicting results [40, 59, 60]. Recently, Zdradzinski and colleagues found cardiac MRI superior to echo in assessing patients at risk for PR [61•]. PR severity by MRI closely correlated with indexed right ventricular end-systolic volume, while echo-assessed PR did not. This suggests that in these patients, cardiac MRI should be a featured modality for surveillance.

Pulmonic Valve Interventions

The first operative attempt to treat PS occurred in Paris in 1913. A tenatome was introduced into the RV to excise the stenotic PV, but unfortunately the patient died on the day following surgery. It then took three decades to reintroduce new techniques to dilate the PV. The first pulmonic valvuloplasty via cardiac catheterization occurred in 1979. The main procedures currently available for treatment of PS are surgical valvotomy, balloon pulmonary valvuloplasty (BPV), and pulmonary valve replacement. For the vast majority of patients, BPV is the procedure of choice, as it is less invasive and has a very high success rate (>90% of patients) [62]. Furthermore, a recent study suggested that BPV can be safely and effectively performed solely under echocardiographic guidance, thus avoiding the risks of radiation and contrast media if needed [63]. This can be particularly useful when a pregnant patient presents with hemodynamically significant PS.

BPV is currently recommended for asymptomatic patients with domed valve morphology and peak echo gradient >60 mmHg (mean > 40) with ≤moderate PR and for symptomatic patients with peak echo gradient >50 mmHg (mean > 30) with ≤moderate PR [64]. Figure 1 demonstrates

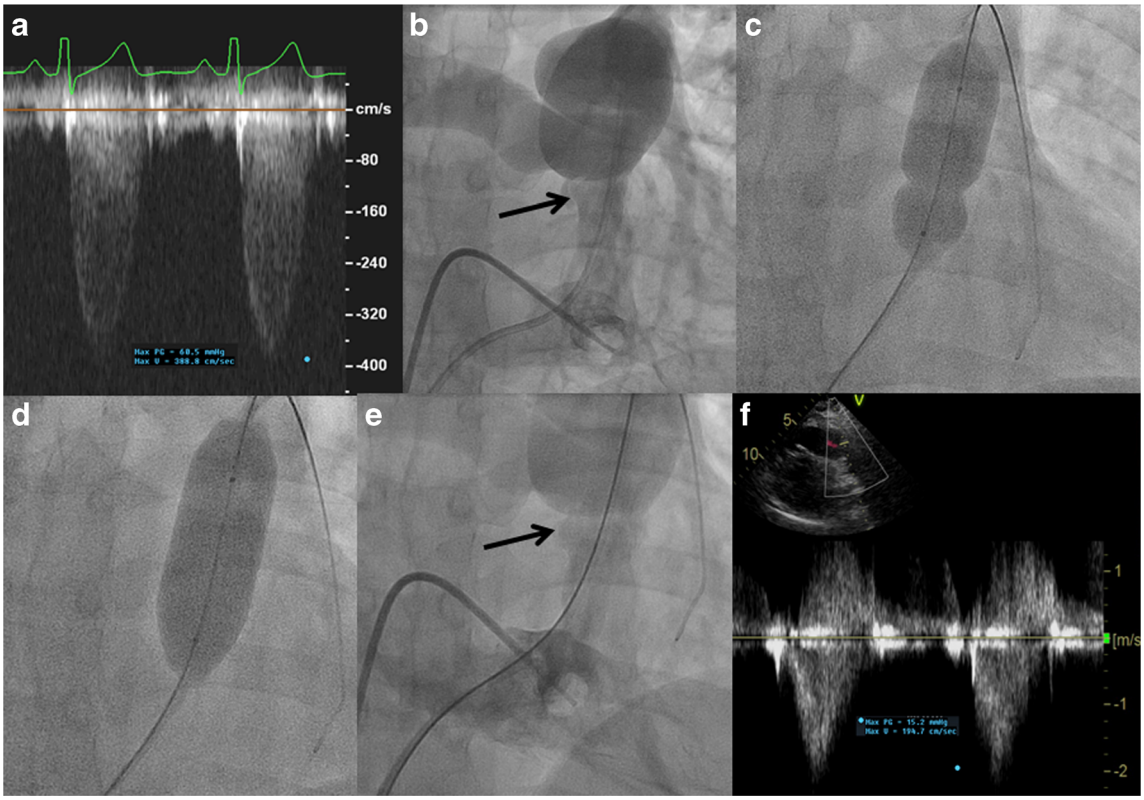

Fig. 1 33-year-old woman who presented with progressive fatigue and dyspnea on exertion. Continuous wave Doppler (A) showed a peak velocity of 3.9 m/s (61 mmHg gradient) and anteroposterior right ventriculography (B) demonstrated a doming pulmonic valve *(first arrow)* with valvular and mild subvalvular narrowing. The annulus measured 20 mm. A 24 mm Vida balloon (Bard; Murray Hill, NJ) was used to dilate the valve (initial phase of inflation, C, and full inflation, D). Full leaflet excursion (E; *second arrow*) was seen on post dilatation right ventriculography. A 15 mmHg gradient was seen on follow-up echo 6 months later (F) and the patient's symptoms had resolved completely

a case of PS that was successfully treated percutaneously. Surgical intervention is typically reserved for patients with hemodynamically significant PS accompanied by a hypoplastic pulmonary annulus or by severe PR [64]. It is also performed in the majority of cases of dysplastic valvular PS, subvalvular PS and supravalvular PS.

BPV has several immediate effects on the PV and RV [65–67]. First, the transvalvular pressure gradient and the RV systolic pressure drop significantly, with little or no increase in PA pressure. Second, doming of the PV decreases and its leaflets become more mobile. Finally, RV function can improve with a concomitant decrease in tricuspid regurgitation, even though the cardiac output may only minimally increase. Recently, Mahfouz and colleagues demonstrated that BPV improved the longitudinal right ventricular motion, as well as inter- and intraventricular dyssynchrony in pediatric patients [68]. Dyssynchrony was significantly increased in PS patients compared to controls, and returned to near normal following BPV. Acute complications of BPV are usually benign, with major complications occurring in 0.6% of cases and mortality in 0.2% [69]. An important major acute complication is transient, severe RVOT obstruction (aka "suicide right ventricle"), which can occur immediately after valvular stenosis is relieved [70, 71]. This is similar to the pathophysiology responsible for left ventricular obstruction in patients with hypertrophic obstructive cardiomyopathy. Increased RV afterload secondary to PS results in RV infundibular hypertrophy, which narrows the RVOT. When the RV end systolic pressure decreases dramatically after BPV and contractility increases, the narrowing gets acutely exacerbated. It can be treated with intravascular volume expansion and beta blockers, and fully resolves as contractility returns to normal and hypertrophy regresses [72]. Infundibular obstruction can be implicated in many cases when a residual gradient is immediately present following BPV, with progressive decline occurring over several months as RV hypertrophy progressively diminishes [69].

The long-term outcomes of BPV have been studied in children and adults, although the duration of follow-up remains shorter than that described for valvotomy. The two most common long-term complications following BPV are progressive PR and restenosis. Until recently, only one study in the pediatric population has reported outcomes at >10 years [73]. All 48 patients in this study developed late PR, but none had significant RV dysfunction or required PV replacement (PVR). In the largest study reporting pediatric PBV outcomes over >10 years, Devanagondi and colleagues noted at least moderate PR in 60% of the 103 patients with echocardiographic follow-up data [2••]. Interestingly, PR was well tolerated in the majority of patients. Only 5% had RV dysfunction and only 3% required PVR. In accordance with another study [74], small BSA at the time of BPV was an independent risk factor for ≥moderate PR. In general, PR that develops following BPV tends to be progressive in the pediatric population; however, significant RV dilation and dysfunction rarely develop [2••,73–76]. Fawzy and colleagues followed 85 adults up to 17 years after BPV (mean follow-up 10 years) and found that PR increased from mild (prior to BPV) to moderate (after BPV) in 2%, and that new mild PR developed in 28% [65]. No case of PR progressed over follow-up, and no RV dilation resulted. On the other hand, other studies have shown progression of PR and consequent RV dysfunction in a small number of patients [77, 78]. In a recent, retrospective study of 41 adults with mean follow up of 11.3 years, 26.8% of patients had mild PR and 7.3% moderate PR at the last follow-up [79], yet none required PVR. Notably, the balloon:annulus ratio was between 1.2 and 1.4 in many of the aforementioned studies [65, 74, 76] and a balloon:annulus ratio higher than this appeared to be a significant risk factor for PR [75, 80].

Assessing long-term impact of chronic PR following BPV will require studies with longer durations of follow-up. Since no such studies currently exist, surgical valvotomy or valvectomy studies provide important surrogate data. They suggest that chronic PR following surgical intervention is generally well tolerated for the first several decades before the RV function starts to deteriorate and symptoms begin to appear. Earing and colleagues examined patients for a mean of 33 years after surgery [36]. Although the rate of surgical reintervention was relatively low during the first 25 years, 40% of patients eventually required PVR for severe PR, which was the most common indication for reintervention. Furthermore, of the patients who did not require PVR, all had PR at the latest follow-up, with half having moderate or severe PR. Most importantly, patients who did not undergo PVR had shorter follow-up, suggesting that many will still require PVR in the future, highlighting the need for continued monitoring for PR progression and RV compromise after BPV.

The other common long-term complication of BPV is restenosis. In the largest published cohort of BPV, McCrindle and colleagues found that 23% of the 533 patients in the Valvuloplasty and Angioplasty of Congenital Anomalies registry developed restenosis (gradient ≥36 mmHg) after median follow-up of 33 months [66]. Sixteen percent of patients required reintervention; half of whom underwent surgical valvotomy/valvectomy and half repeat BPV. Risk factors for restenosis included dysplastic valve morphology, small pulmonary annulus diameter, high residual gradient immediately following BPV and small balloon:annulus ratio (< 1.2). In a study published by Rao and colleagues, 11% of the 82 children and adolescents followed at a 2 year interval had restenosis (gradient ≥50 mmHg) [76]. Again, high residual gradient immediately after dilation and small balloon:annulus ratio (< 1.2) were predictors of restenosis.

After a thorough analysis of available data, Rao recommended a balloon to annulus ratio of 1.2 to 1.25 [70].

Recently, Pathak and colleagues examined the effectiveness of a more conservative balloon:annulus ratio of ≤1.2 compared to >1.2 [81] and found significantly less PR, but no significant difference in gradient reduction. Reintervention rates were also not statistically different between groups.

Surgical Pulmonic Valve Replacement

Patients with ≥moderate PR or those who have undergone an intervention known to increase the risk for chronic PR (RVOT repair, BPV, etc.) require regular follow up with echocardiography and/or cardiac MRI to monitor for PR progression and changes in RV size and function, even if the patient remains asymptomatic. Waiting for symptoms to develop can result in RVs that can remain markedly dilated and/or dysfunctional after correction. PVR is the treatment of choice in most patients, as it has been shown to improve pulmonary blood flow, reduce tricuspid regurgitation and improve RV mechanics, resulting in clinical improvement [82–84, 85••]. It is noteworthy that evidence supporting timing of PVR is mostly derived from patients with repaired TOF, and whether it can be applied to PR from other etiologies remains uncertain.

Indications for PVR in TOF include severe PR and either the presence of cardiac MRI-derived RV end-diastolic indexed volume > 150 mL/m^2 or RV end-systolic indexed volume > 80 mL/m^2, QRS duration >180 ms or prolongation >3.5 ms/year, residual shunt defects, RVOT obstruction (RV systolic pressure > 2/3 systemic pressure), symptoms of exercise intolerance or heart failure and sustained arrhythmia [86–88]. PVR should ideally take place prior to the onset of PR-related symptoms and before RV dysfunction occurs, with the hope that earlier intervention will facilitate more efficient reverse remodeling and improve long-term outcomes [89–91]. However, it remains uncertain whether PVR improves long-term survival and several studies have now shown reduction in RV volumes after PVR without concomitant improvement in RV ejection fraction [92,93••]. As such the decision to proceed with PVR should also consider the likelihood of eventual valve failure and the need for multiple, repeated interventions.

Surgical PVR is currently pursued in most patients with native RVOTs. Although mechanical valves offer higher durability, bioprosthetic valves are preferred in this anatomical position due to lower risk for thrombosis (no need for systemic anticoagulation) and the ease of access to the pulmonary vascular bed for future interventions. Aortic and pulmonary homografts were historically the most commonly utilized valves, though accelerated degradation was a major pitfall, especially in younger patients who may have an enhanced immune response [94–96]. Current bioprosthetic valve options include homografts, porcine, or bovine tissue valves, with or without stents. Stented valves typically mimic the anatomy of the native valve and are mounted inside or outside of a supporting stent, whereas stentless valves offer a bigger valve orifice perhaps at the expense of less structural support [97]. There does not appear to be a single best valve option for all patients; and the choice should be influenced by several factors including primary diagnosis, RVOT anatomy, age and size of the patient, previous surgical history and patient choice. Short- and mid-term outcomes for bioprosthetic PVR appear encouraging [98–101]. Calcium deposition and subsequent valve thickening is a major cause of late bioprosthetic valve failure, often requiring reintervention within 10 years [102]. Recently, Nomoto and colleagues published results of 611 congenital heart patients who underwent bioprosthetic PVR over an 18-year period [103]. Shorter time to reintervention was seen in younger patients, patients with lower BMI and those receiving the Sorin Mitroflow LXE valve.

Transcatheter Pulmonic Valve Replacement

Transcatheter pulmonic valve replacement (TPVR) emerged in 2000 as a less invasive treatment option for PR and PS [104]. It initially found use in patients with RV-to-PA conduit dysfunction, given the need for an adequate landing zone [105]. Conduits are implanted during surgical management of certain congenital heart diseases such as pulmonary atresia and truncus arteriosus, and as part of the Rastelli repair for d-TGA. All RVOT conduits eventually become dysfunctional (either obstructive or regurgitant) and require further intervention. TPVR has additionally become utilized as the procedure of choice in patients with failed bioprostheses via valve-in-valve implantation [106, 107].

The first transcatheter valve to be developed was the Melody® valve (Medtronic, Minneapolis, MN), made of bovine jugular vein. It offers diameters between 18 and 22 mm, limiting its use to delivery zones that are ≤24 mm in diameter [108, 109]. Short-term studies have shown excellent results, with decrease in RV size and ECG QRS duration following valve implantation [110–112], and mid-term studies up to 9 years demonstrating good hemodynamic and clinical outcomes [113, 114, 115•]. Moreover, the 5-year freedom from re-intervention after Melody implantation exceeded 90% in two of the main clinical trials [116, 117]. A major cause of Melody valve dysfunction appears to be restenosis due to stent fracture. The incidence of this problem has decreased dramatically after pre-stenting has become widely adopted [115•,117]. The Melody was FDA approved for failing conduits in 2010 and for failing bioprostheses (valve-in-valve) in 2017.

In 2016, the Edwards Sapien XT valve (Edwards Lifesciences, Irvine, CA) received FDA approval for use in failing pulmonary conduits. It is a bovine pericardial tissue valve that offers diameters from 23 to 29 mm [118]. This is extremely helpful for select patients who have larger native

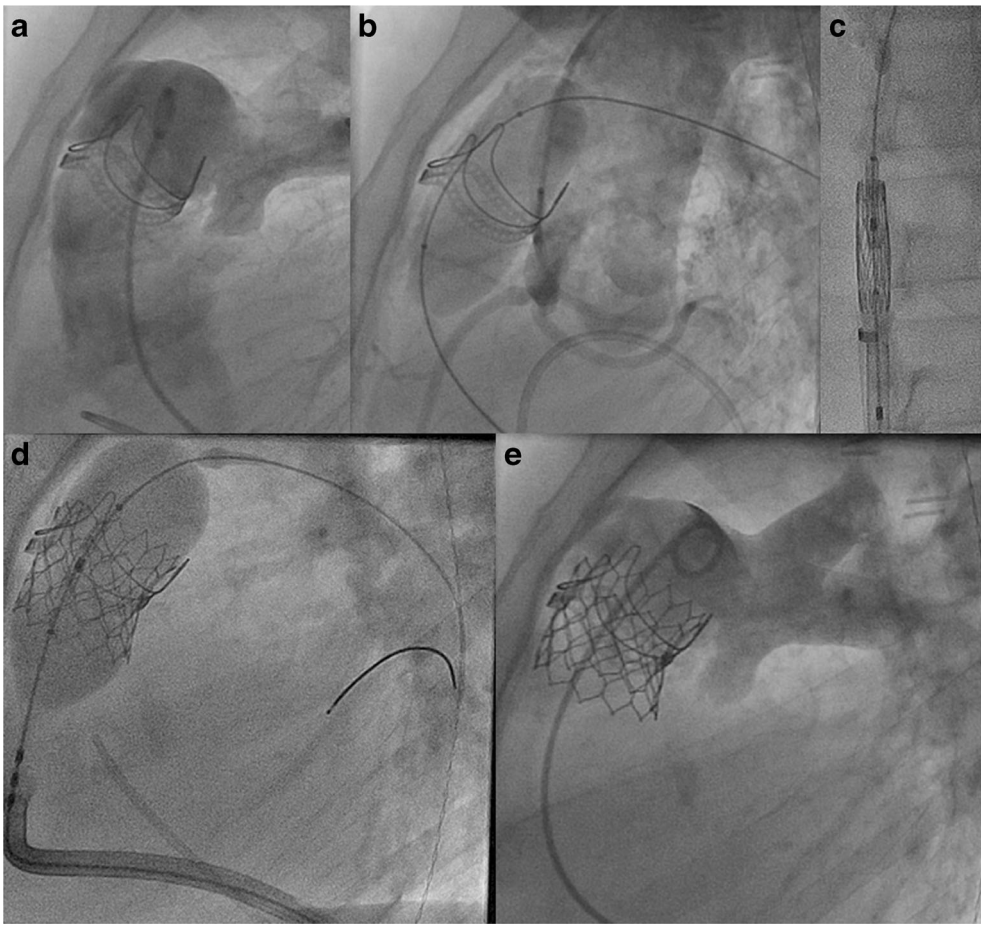

Fig. 2 A 38-year-old woman with tetralogy of Fallot and near pulmonary atresia who had undergone a right ventricular to pulmonary artery conduit at age 6 and then a pulmonic valve replacement at age 25 presented with dyspnea on exertion, palpitations and fatigue and her echocardiogram revealed severe pulmonic regurgitation and moderate right ventricular dilatation. There was a question of an outflow tract aneurysm, but pulmonary angiography (A) revealed this to be the original, native outflow tract before the conduit. Aortography with balloon inflation (B) showed no coronary artery compression. A Sapien S3 valve (Edwards Lifesciences; Irvine, CA) was unsheathed in the inferior vena cava (C) and delivered into the orifice of the bioprosthesis (D). Post intervention pulmonary angiography (E) showed trivial to no pulmonic regurgitation

RVOTs, transannular-patched RVOTs, larger RV-to-PA conduits [119] as well as larger bioprostheses. Figure 2 illustrates transcatheter implantation of the newest Sapien valve, the S3, into a patient with failed RV-to-PA conduit. Studies using the Sapien valves in the pulmonary position are few to date, with little long-term data available. Wilson and colleagues recently followed 25 patients for a mean of 3.5 years after Sapien TPVR [120]. Only one patient required reintervention for severe PR; no other patient had clinically significant PR, and valve function was preserved during follow up. Table 2 compares the structural characteristics of the two currently approved valves for TPVR.

Several limitations currently preclude widespread use of TPVR. Asymmetric RVOTs form poor landing zones and result in incomplete apposition or resultant paravalvular leaks. Furthermore, the majority patients who may be the best candidates for TPVR have native RVOTs that are too dilated for available prostheses. Gaining proper delivery sheath position for deploying transcatheter valves can be particularly challenging in some patients, as the delivery systems are generally not engineered to follow the many twists and bends of the pathway from the venous circulation to the pulmonary outflow tract. Because of these issues, only 15% of patients initially eligible to receive a transcatheter pulmonic valve are currently able to be treated in this fashion. In patients who undergo an attempt at transcatheter replacement, two major intraprocedural complications are important to recognize and prevent: coronary artery compression and aortic root compression. Coronary compression is a potentially life-threatening complication that occurs in 5–6% of patients [121, 122], whereas aortic root compression can lead to aortic cusp distortion and aortic valve regurgitation, affecting 10% of patients [123•]. To anticipate and prevent such complications, 3D modeling and printing

Table 2 Comparison of the 2 currently FDA approved valves for transcatheter delivery into dysfunctional pulmonary conduits. On the left is the Melody (Medtronic; Minneapolis, MN) and on the right the Sapien XT (Edwards Lifesciences; Irvine, CA)

	Melody Valve	Sapien XT Valve
Valve material	Bovine jugular vein	Bovine pericardium
Stent materials	Platinum 90% Iridium 10%	Stainless steel
Stent height	34 mm	14.5 mm, 16 mm
Available sizes	18-22 mm	20, 23, 26, 29 mm
Delivery sheath size	22 French	16, 18, 20 French

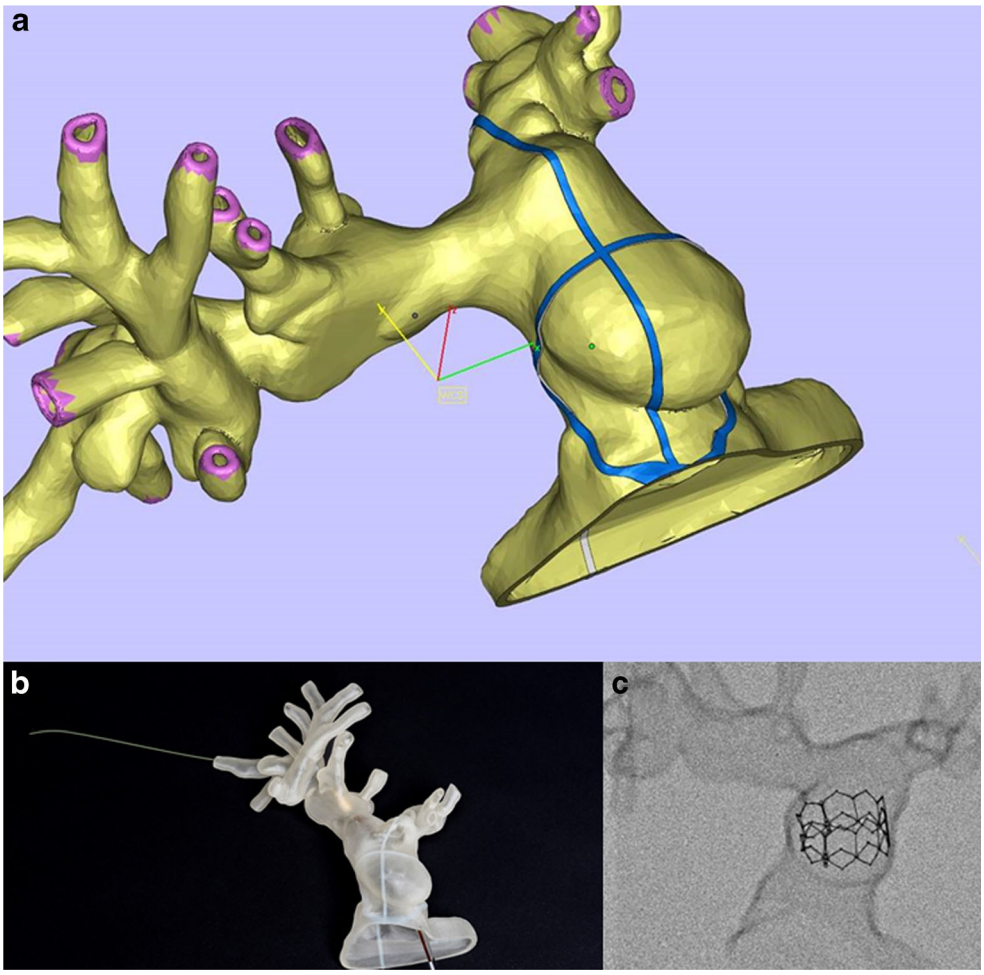

Fig. 3 A modeling PDF file (A) derived from a high-resolution CT scan, permitting the user to manipulate the image in multiple dimensions. This can be printed on a 3D printer and then utilized to rehearse valve implantation (B, shows the model with delivery catheter and valve inside and C is the representative fluoroscopic image after valve delivery)

derived from high resolution pre-procedural CT or cardiac MRI imaging can be utilized (Fig. 3).

Other new techniques are also being developed to help overcome current limitations of TPVR. Levi and colleagues recently devised a new method for delivering the 29 mm Sapien XT valve into the pulmonary position by mounting it on a larger and more flexible (Nucleus) balloon platform [124], allowing oversizing of the valve. Hybrid approaches for PVR, which combine the vascular access and landing zone modification of surgery with less-invasive transcatheter valve delivery are already being utilized at many institutions. They allow for off-pump PVR in patients with dilated RVOTs, who may otherwise be unsuitable for transcatheter intervention. Procedural success appears comparable to standard surgical PVR while potentially reducing perioperative morbidity and mortality [125, 126]. Other techniques that are currently under development include RVOT reducers/fillers to create smaller landing zones [127•], use of self-expanding valve platforms that can cover larger RVOT diameters [128,129•], and finally tissue engineered self-expanding stent platforms populated with autologous cells which may prevent the long-term sclerosis and calcification that plagues xenograft implants [130]. The majority of these advancements, however, remain experimental.

Conclusion

Congenital PV disease far outnumbers acquired cases, with vavular PS being the most common. PBV is well established as the gold standard intervention, with excellent short- and long-term outcomes. Recent studies suggest more conservative balloon:annulus ratios (1.2 and below) to reduce complications, with PR being the most common. Significant PR, initially considered benign, inevitably leads to RV dilatation and failure. While surgical PVR remains the intervention of choice for most patients, TPVR offers a less invasive approach with short- and mid-term results comparable to surgery. At this point TPVR is approved for failing conduits and bioprotheses, and off-label use remains greatly limited by anatomic and device design issues. New technological advances will undoubtedly increase the number of patients who can be successfully treated with this less invasive approach in the future.

Compliance with Ethical Standards

Conflict of Interest Mouhammad Fathallah declares no conflict of interest.

Richard A. Krasuski reports grants and personal fees from Actelion, grants from Abbott Laboratories, and grants from Edwards Life Sciences.

Human and Animal Rights and Informed Consent This article does not contain any studies with human or animal subjects performed by any of the authors.

References

Papers of particular interest, published recently, have been highlighted as:
- • Of importance
- •• Of major importance

1. Lloyd TR, Marvin WJ, Mahoney LT, Lauer RM. Balloon dilation valvuloplasty of bioprosthetic valves in extracardiac conduits. Am Heart J. 1987;114(2):268–74.
2.•• Devanagondi R, Peck D, Sagi J, Donohue J, Yu S, Pasquali SK, et al. Long-term outcomes of balloon Valvuloplasty for isolated pulmonary valve stenosis. Pediatr Cardiol. 2017;38(2):247–54. https://doi.org/10.1007/s00246-016-1506-4. **The largest study to date providing BPV outcome data in the pediatric population over a period of >10 years. 103 patients were followed for a mean of 14.4 years. 60% developed ≥moderate PR, 5% had systolic RV dysfunction, and 3% underwent PVR for symptomatic severe PR and RV enlargement. Small body surface area and increased baseline RV-PA systolic ejection gradient at time of initial BPV were risk factors for developing PR**
3. Waller BF, Howard J, Fess S. Pathology of pulmonic valve stenosis and pure regurgitation. Clin Cardiol. 1995;18(1):45–50.
4. Shaw AC, Kalidas K, Crosby AH, Jeffery S, Patton MA. The natural history of Noonan syndrome: a long-term follow-up study. Arch Dis Child. 2007;92(2):128–32.
5. Lin AE, Basson CT, Goldmuntz E, Magoulas PL, McDermott DA, McDonald-McGinn DM, et al. Adults with genetic syndromes and cardiovascular abnormalities: clinical history and management. Genet Med. 2008;10(7):469–94.
6. Kumar A, Stalker HJ, Williams CA. Concurrence of supravalvular aortic stenosis and peripheral pulmonary stenosis in three generations of a family: a form of arterial dysplasia. Am J Med Genet. 1993;45(6):739–42.
7. Driscoll DJ, Michels VV, Gersony WM, Hayes CJ, Keane JF, Kidd L, et al. Occurrence risk for congenital heart defects in relatives of patients with aortic stenosis, pulmonary stenosis, or ventricular septal defect. Circulation. 1993;87(2 Suppl):I114–20.
8. Bashore TM. Adult congenital heart disease: right ventricular outflow tract lesions. Circulation. 2007;115(14):1933–47.
9. Stamm C, Anderson RH, Ho SY. Clinical anatomy of the normal pulmonary root compared with that in isolated pulmonary valvular stenosis. J Am Coll Cardiol. 1998;31(6):1420–5.
10. Vedanthan R, Sanz J, Halperin J. Bicuspid pulmonic valve. J Am Coll Cardiol. 2009;54(8):e5.
11. Rao BN, Anderson RC, Edwards JE. Anatomic variations in the tetralogy of Fallot. Am Heart J. 1971;81(3):361–71.
12. Ascione L, Lengo R, Tuccillo B, D'Andrea A, De Michele M, Porto A, et al. Quadricuspid pulmonary valve diagnosed by cardiac magnetic resonance. J Cardiovasc Med (Hagerstown). 2009;10(12):944–5.
13. Shah R, Shriki J, Shinbane JS. Cardiovascular magnetic resonance depiction of quadricuspid pulmonary valve with associated pulmonary regurgitation and pulmonary artery aneurysm. Tex Heart Inst J. 2014;41(3):349–50.
14. Watson GH, Miller V. Arteriohepatic dysplasia: familial pulmonary arterial stenosis with neonatal liver disease. Arch Dis Child. 1973;48(6):459–66.
15. Abbas JR, Hoschtitzky JA. Which is the best tissue valve used in the pulmonary position, late after previous repair of tetralogy of Fallot? Interact Cardiovasc Thorac Surg. 2013;17(5):854–60.
16. Rowe RD. Cardiovascular disease in the rubella syndrome. Cardiovasc Clin. 1973;5(1):61–80.
17. Cormode EJ, Dawson M, Lowry RB. Keutel syndrome: clinical report and literature review. Am J Med Genet. 1986;24(2):289–94.
18. Prifti E, Crucean A, Bonacchi M, Bernabei M, Murzi B, Luisi SV, et al. Early and long term outcome of the arterial switch operation for transposition of the great arteries: predictors and functional evaluation. Eur J Cardiothorac Surg. 2002;22(6):864–73.
19. Cabrera A, Martinez P, Rumoroso JR, Alcibar J, Arriola J, Pastor E, et al. Double-chambered right ventricle. Eur Heart J. 1995;16(5):682–6.
20. Shyu KG, Tseng CD, Chiu IS, Hung CR, Chu SH, Lue HC, et al. Infundibular pulmonic stenosis with intact ventricular septum: a report of 15 surgically corrected patients. Int J Cardiol. 1993;41(2):115–21.
21. Fox D, Devendra GP, Hart SA, Krasuski RA. When 'blue babies' grow up: what you need to know about tetralogy of Fallot. Cleve Clin J Med. 2010;77(11):821–8.
22. Robertson M, Benson LN, Smallhorn JS, Musewe N, Freedom RM, Moes CA, et al. The morphology of the right ventricular outflow tract after percutaneous pulmonary valvotomy: long term follow up. Br Heart J. 1987;58(3):239–44.
23. Hayes CJ, Gersony WM, Driscoll DJ, Keane JF, Kidd L, O'Fallon WM, et al. Second natural history study of congenital heart defects. Results of treatment of patients with pulmonary valvar stenosis. Circulation. 1993;87(2 Suppl):I28–37.
24. Jonsson B, Lee SJ. Haemodynamic effects of exercise in isolated pulmonary stenosis before and after surgery. Br Heart J. 1968;30(1):60–6.
25. Nishimura RA, Otto CM, Bonow RO, Carabello BA, Erwin JP, Guyton RA, et al. 2014 AHA/ACC guideline for the management of patients with valvular heart disease: a report of the American College of Cardiology/American Heart Association task force on practice guidelines. J Am Coll Cardiol. 2014;63(22):e57–185.
26. Lima CO, Sahn DJ, Valdes-Cruz LM, Goldberg SJ, Barron JV, Allen HD, et al. Noninvasive prediction of transvalvular pressure gradient in patients with pulmonary stenosis by quantitative two-dimensional echocardiographic Doppler studies. Circulation. 1983;67(4):866–71.
27. Johnson GL, Kwan OL, Handshoe S, Noonan JA, DeMaria AN. Accuracy of combined two-dimensional echocardiography and continuous wave Doppler recordings in the estimation of pressure gradient in right ventricular outlet obstruction. J Am Coll Cardiol. 1984;3(4):1013–8.
28. Takao S, Miyatake K, Izumi S, Okamoto M, Kinoshita N, Nakagawa H, et al. Clinical implications of pulmonary regurgitation in healthy individuals: detection by cross sectional pulsed Doppler echocardiography. Br Heart J. 1988;59(5):542–50.
29. Rocchini AP, Beekman RH. Balloon angioplasty in the treatment of pulmonary valve stenosis and coarctation of the aorta. Tex Heart Inst J. 1986;13(4):377–85.
30. Saremi F, Gera A, Ho SY, Hijazi ZM, Sánchez-Quintana D. CT and MR imaging of the pulmonary valve. Radiographics. 2014;34(1):51–71.

31. Haddad F, Hunt SA, Rosenthal DN, Murphy DJ. Right ventricular function in cardiovascular disease, part I: anatomy, physiology, aging, and functional assessment of the right ventricle. Circulation. 2008;117(11):1436–48.
32. Klein AL, Burstow DJ, Tajik AJ, Zachariah PK, Taliercio CP, Taylor CL, et al. Age-related prevalence of valvular regurgitation in normal subjects: a comprehensive color flow examination of 118 volunteers. J Am Soc Echocardiogr. 1990;3(1):54–63.
33. Ansari A. Isolated pulmonary valvular regurgitation: current perspectives. Prog Cardiovasc Dis. 1991;33(5):329–44.
34. Hamza N, Ortiz J, Bonomo RA. Isolated pulmonic valve infective endocarditis: a persistent challenge. Infection. 2004;32(3):170–5.
35. Pellikka PA, Tajik AJ, Khandheria BK, Seward JB, Callahan JA, Pitot HC, et al. Carcinoid heart disease. Clinical and echocardiographic spectrum in 74 patients. Circulation. 1993;87(4):1188–96.
36. Earing MG, Connolly HM, Dearani JA, Ammash NM, Grogan M, Warnes CA. Long-term follow-up of patients after surgical treatment for isolated pulmonary valve stenosis. Mayo Clin Proc. 2005;80(7):871–6.
37. Rebergen SA, Chin JG, Ottenkamp J, van der Wall EE, de Roos A. Pulmonary regurgitation in the late postoperative follow-up of tetralogy of Fallot. Volumetric quantitation by nuclear magnetic resonance velocity mapping. Circulation. 1993;88(5 Pt 1):2257–66.
38. Miller RA, Lev M, Paul MH. Congenital absence of the pulmonary valve. The clinical syndrome of tetralogy of Fallot with pulmonary regurgitation. Circulation. 1962;26:266–78.
39. Zucker N, Rozin I, Levitas A, Zalzstein E. Clinical presentation, natural history, and outcome of patients with the absent pulmonary valve syndrome. Cardiol Young. 2004;14(4):402–8.
40. Renella P, Aboulhosn J, Lohan DG, Jonnala P, Finn JP, Satou GM, et al. Two-dimensional and Doppler echocardiography reliably predict severe pulmonary regurgitation as quantified by cardiac magnetic resonance. J Am Soc Echocardiogr. 2010;23(8):880–6.
41. Ristow B, Ahmed S, Wang L, Liu H, Angeja BG, Whooley MA, et al. Pulmonary regurgitation end-diastolic gradient is a Doppler marker of cardiac status: data from the heart and soul study. J Am Soc Echocardiogr. 2005;18(9):885–91.
42. Shimazaki Y, Blackstone EH, Kirklin JW. The natural history of isolated congenital pulmonary valve incompetence: surgical implications. Thorac Cardiovasc Surg. 1984;32(4):257–9.
43. Davlouros PA, Kilner PJ, Hornung TS, Li W, Francis JM, Moon JC, et al. Right ventricular function in adults with repaired tetralogy of Fallot assessed with cardiovascular magnetic resonance imaging: detrimental role of right ventricular outflow aneurysms or akinesia and adverse right-to-left ventricular interaction. J Am Coll Cardiol. 2002;40(11):2044–52.
44. Bigdelian H, Mardani D, Sedighi M. The effect of pulmonary valve replacement (PVR) surgery on hemodynamics of patients who underwent repair of tetralogy of Fallot (TOF). J Cardiovasc Thorac Res. 2015;7(3):122–5.
45. Frigiola A, Giardini A, Taylor A, Tsang V, Derrick G, Khambadkone S, et al. Echocardiographic assessment of diastolic biventricular properties in patients operated for severe pulmonary regurgitation and association with exercise capacity. Eur Heart J Cardiovasc Imaging. 2012;13(8):697–702.
46. Frigiola A, Redington AN, Cullen S, Vogel M. Pulmonary regurgitation is an important determinant of right ventricular contractile dysfunction in patients with surgically repaired tetralogy of Fallot. Circulation. 2004;110(11 Suppl 1):II153–7.
47. Bouzas B, Kilner PJ, Gatzoulis MA. Pulmonary regurgitation: not a benign lesion. Eur Heart J. 2005;26(5):433–9.
48. Gatzoulis MA, Balaji S, Webber SA, Siu SC, Hokanson JS, Poile C, et al. Risk factors for arrhythmia and sudden cardiac death late after repair of tetralogy of Fallot: a multicentre study. Lancet. 2000;356(9234):975–81.
49. Knauth AL, Gauvreau K, Powell AJ, Landzberg MJ, Walsh EP, Lock JE, et al. Ventricular size and function assessed by cardiac MRI predict major adverse clinical outcomes late after tetralogy of Fallot repair. Heart. 2008;94(2):211–6.
50. Redington AN. Determinants and assessment of pulmonary regurgitation in tetralogy of Fallot: practice and pitfalls. Cardiol Clin. 2006;24(4):631–9. **vii**
51. Joynt MR, Yu S, Dorfman AL, Ghadimi Mahani M, Agarwal PP, Lu JC. Differential impact of pulmonary regurgitation on patients with surgically repaired pulmonary stenosis versus tetralogy of Fallot. Am J Cardiol. 2016;117(2):289–94.
52. Rajiah P, Nazarian J, Vogelius E, Gilkeson RC. CT and MRI of pulmonary valvular abnormalities. Clin Radiol. 2014;69(6):630–8.
53. Jonas SN, Kligerman SJ, Burke AP, Frazier AA, White CS. Pulmonary valve anatomy and abnormalities: a pictorial essay of radiography, computed tomography (CT), and magnetic resonance imaging (MRI). J Thorac Imaging. 2016;31(1):W4–12.
54. Geva T. Repaired tetralogy of Fallot: the roles of cardiovascular magnetic resonance in evaluating pathophysiology and for pulmonary valve replacement decision support. J Cardiovasc Magn Reson. 2011;13:9.
55. Mooij CF, de Wit CJ, Graham DA, Powell AJ, Geva T. Reproducibility of MRI measurements of right ventricular size and function in patients with normal and dilated ventricles. J Magn Reson Imaging. 2008;28(1):67–73.
56. Wald RM, Haber I, Wald R, Valente AM, Powell AJ, Geva T. Effects of regional dysfunction and late gadolinium enhancement on global right ventricular function and exercise capacity in patients with repaired tetralogy of Fallot. Circulation. 2009;119(10):1370–7.
57. Babu-Narayan SV, Kilner PJ, Li W, Moon JC, Goktekin O, Davlouros PA, et al. Ventricular fibrosis suggested by cardiovascular magnetic resonance in adults with repaired tetralogy of fallot and its relationship to adverse markers of clinical outcome. Circulation. 2006;113(3):405–13.
58. Samyn MM, Powell AJ, Garg R, Sena L, Geva T. Range of ventricular dimensions and function by steady-state free precession cine MRI in repaired tetralogy of Fallot: right ventricular outflow tract patch vs. conduit repair. J Magn Reson Imaging. 2007;26(4):934–40.
59. Crean AM, Maredia N, Ballard G, Menezes R, Wharton G, Forster J, et al. 3D Echo systematically underestimates right ventricular volumes compared to cardiovascular magnetic resonance in adult congenital heart disease patients with moderate or severe RV dilatation. J Cardiovasc Magn Reson. 2011;13:78.
60. Mercer-Rosa L, Yang W, Kutty S, Rychik J, Fogel M, Goldmuntz E. Quantifying pulmonary regurgitation and right ventricular function in surgically repaired tetralogy of Fallot: a comparative analysis of echocardiography and magnetic resonance imaging. Circ Cardiovasc Imaging. 2012;5(5):637–43.
61.• Zdradzinski M, Elkin R, Flamm S, Krasuski R. Incremenal value of cardiac magnetic resonance for assessing pulmonic valve regurgitation. J Heart Valve Dis. 2015;24(4):502–7. **This study compares cardiac MRI to echo in assessment of PR severity in patients with TOF following complete repair and PS following valvotomy. Cardiac MRI-derived measures of PR closely correlated to right ventricular end systolic volume index, while echo-derived measures did not. This suggests that cardiac MRI should play a vital role in the assessment of patients at risk for PR**
62. Kan JS, White RI, Mitchell SE, Gardner TJ. Percutaneous balloon valvuloplasty: a new method for treating congenital pulmonary-valve stenosis. N Engl J Med. 1982;307(9):540–2.
63. Wang SZ, Ou-Yang WB, Hu SS, Pang KJ, Liu Y, Zhang FW, et al. First-in-human percutaneous balloon pulmonary Valvuloplasty under echocardiographic guidance only. Congenit Heart Dis. 2016;11(6):716–20.

64. Warnes CA, Williams RG, Bashore TM, Child JS, Connolly HM, Dearani JA, et al. ACC/AHA 2008 guidelines for the Management of Adults with congenital heart disease: a report of the American College of Cardiology/American Heart Association task force on practice guidelines (writing committee to develop guidelines on the management of adults with congenital heart disease). Circulation. 2008;118(23):e714–833.
65. Fawzy ME, Hassan W, Fadel BM, Sergani H, El Shaer F, El Widaa H, et al. Long-term results (up to 17 years) of pulmonary balloon valvuloplasty in adults and its effects on concomitant severe infundibular stenosis and tricuspid regurgitation. Am Heart J. 2007;153(3):433–8.
66. McCrindle BW. Independent predictors of long-term results after balloon pulmonary valvuloplasty. Valvuloplasty and angioplasty of congenital anomalies (VACA) registry investigators. Circulation. 1994;89(4):1751–9.
67. McCrindle BW, Kan JS. Long-term results after balloon pulmonary valvuloplasty. Circulation. 1991;83(6):1915–22.
68. Mahfouz RA, Moustafa TM, Gouda M, Gad M. Longitudinal function and ventricular dyssynchrony are restored in children with pulmonary stenosis after percutaneous balloon pulmonary valvuloplasty. Int J Cardiovasc Imaging. 2017;33(4):533–8.
69. Stanger P, Cassidy SC, Girod DA, Kan JS, Lababidi Z, Shapiro SR. Balloon pulmonary valvuloplasty: results of the Valvuloplasty and angioplasty of congenital anomalies registry. Am J Cardiol. 1990;65(11):775–83.
70. Rao PS. Percutaneous balloon pulmonary valvuloplasty: state of the art. Catheter Cardiovasc Interv. 2007;69(5):747–63.
71. Ben-Shachar G, Cohen MH, Sivakoff MC, Portman MA, Riemenschneider TA, Van Heeckeren DW. Development of infundibular obstruction after percutaneous pulmonary balloon valvuloplasty. J Am Coll Cardiol. 1985;5(3):754–6.
72. Fawzy ME, Galal O, Dunn B, Shaikh A, Sriram R, Duran CM. Regression of infundibular pulmonary stenosis after successful balloon pulmonary valvuloplasty in adults. Catheter Cardiovasc Diagn. 1990;21(2):77–81.
73. Merino-Ingelmo R, Santos-de Soto J, Coserria-Sánchez F, Descalzo-Señoran A, Valverde-Pérez I. Long-term results of percutaneous balloon valvuloplasty in pulmonary valve stenosis in the pediatric population. Rev Esp Cardiol (Engl Ed). 2014;67(5):374–9.
74. Garty Y, Veldtman G, Lee K, Benson L. Late outcomes after pulmonary valve balloon dilatation in neonates, infants and children. J Invasive Cardiol. 2005;17(6):318–22.
75. Harrild DM, Powell AJ, Tran TX, Trang TX, Geva T, Lock JE, et al. Long-term pulmonary regurgitation following balloon valvuloplasty for pulmonary stenosis risk factors and relationship to exercise capacity and ventricular volume and function. J Am Coll Cardiol. 2010;55(10):1041–7.
76. Rao PS, Galal O, Patnana M, Buck SH, Wilson AD. Results of three to 10 year follow up of balloon dilatation of the pulmonary valve. Heart. 1998;80(6):591–5.
77. Sadr-Ameli MA, Sheikholeslami F, Firoozi I, Azarnik H. Late results of balloon pulmonary valvuloplasty in adults. Am J Cardiol. 1998;82(3):398–400.
78. Taggart NW, Cetta F, Cabalka AK, Hagler DJ. Outcomes for balloon pulmonary valvuloplasty in adults: comparison with a concurrent pediatric cohort. Catheter Cardiovasc Interv. 2013;82(5):811–5.
79. Qian X, Qian Y, Zhou Y, Yang X. Percutaneous pulmonary balloon Valvuloplasty provides good long-term outcomes in adults with pulmonary valve stenosis. J Invasive Cardiol. 2015;27(12):E291–6.
80. Berman W, Fripp RR, Raisher BD, Yabek SM. Significant pulmonary valve incompetence following oversize balloon pulmonary valveplasty in small infants: a long-term follow-up study. Catheter Cardiovasc Interv. 1999;48(1):61–5.
81. Pathak SJ, Pockett CR, Moore JW, El-Said HG. Effect of balloon: annulus ratio on incidence of pulmonary insufficiency following Valvuloplasty. Congenit Heart Dis. 2016;11(5):415–9.
82. Geva T, Sandweiss BM, Gauvreau K, Lock JE, Powell AJ. Factors associated with impaired clinical status in long-term survivors of tetralogy of Fallot repair evaluated by magnetic resonance imaging. J Am Coll Cardiol. 2004;43(6):1068–74.
83. Frigiola A, Tsang V, Bull C, Coats L, Khambadkone S, Derrick G, et al. Biventricular response after pulmonary valve replacement for right ventricular outflow tract dysfunction: is age a predictor of outcome? Circulation. 2008;118(14 Suppl):S182–90.
84. Geva T, Gauvreau K, Powell AJ, Cecchin F, Rhodes J, Geva J, et al. Randomized trial of pulmonary valve replacement with and without right ventricular remodeling surgery. Circulation. 2010;122(11 Suppl):S201–8.
85.•• Bokma JP, Winter MM, Oosterhof T, Vliegen HW, van Dijk AP, Hazekamp MG, et al. Preoperative thresholds for mid-to-late haemodynamic and clinical outcomes after pulmonary valve replacement in tetralogy of Fallot. Eur Heart J. 2016;37(10):829–35. **A multi-center study that compared cardiac MRI values in 65 patients with TOF before and 3 years after pulmonic valve replacement. Pre-operative RV end-systolic volume index <80 mL/m^2 was found to be the best threshold to achieve mid- to late- RV normalization. The risk for suboptimal outcomes and adverse events was increased in patients whose pre-operative RVESi exceeded 95 mL/m^2**
86. Lee C, Kim YM, Lee CH, Kwak JG, Park CS, Song JY, et al. Outcomes of pulmonary valve replacement in 170 patients with chronic pulmonary regurgitation after relief of right ventricular outflow tract obstruction: implications for optimal timing of pulmonary valve replacement. J Am Coll Cardiol. 2012;60(11):1005–14.
87. Ammash NM, Dearani JA, Burkhart HM, Connolly HM. Pulmonary regurgitation after tetralogy of Fallot repair: clinical features, sequelae, and timing of pulmonary valve replacement. Congenit Heart Dis. 2007;2(6):386–403.
88. Oosterhof T, van Straten A, Vliegen HW, Meijboom FJ, van Dijk AP, Spijkerboer AM, et al. Preoperative thresholds for pulmonary valve replacement in patients with corrected tetralogy of Fallot using cardiovascular magnetic resonance. Circulation. 2007;116(5):545–51.
89. Ferraz Cavalcanti PE, Sá MP, Santos CA, Esmeraldo IM, de Escobar RR, de Menezes AM, et al. Pulmonary valve replacement after operative repair of tetralogy of Fallot: meta-analysis and meta-regression of 3,118 patients from 48 studies. J Am Coll Cardiol. 2013;62(23):2227–43.
90. van der Wall EE, Mulder BJ. Pulmonary valve replacement in patients with tetralogy of Fallot and pulmonary regurgitation: early surgery similar to optimal timing of surgery? Eur Heart J. 2005;26(24):2614–5.
91. Therrien J, Provost Y, Merchant N, Williams W, Colman J, Webb G. Optimal timing for pulmonary valve replacement in adults after tetralogy of Fallot repair. Am J Cardiol. 2005;95(6):779–82.
92. Cheung EW, Wong WH, Cheung YF. Meta-analysis of pulmonary valve replacement after operative repair of tetralogy of fallot. Am J Cardiol. 2010;106(4):552–7.
93.•• Hallbergson A, Gauvreau K, Powell AJ, Geva T. Right ventricular remodeling after pulmonary valve replacement: early gains, late losses. Ann Thorac Surg. 2015;99(2):660–6. **In this study, serial cardiac MRI was done in 101 patients with TOF before and after surgical PVR. Although indexed RV end-systolic and end-diastolic volumes initially decreased after PVR, they progressively increased back to pre-operative values after 7-10 years, and RV ejection fraction progressively declined. This suggests that PVR is simply palliative, and that continued surveillance afterwards is critical**

94. Caldarone CA, McCrindle BW, Van Arsdell GS, Coles JG, Webb G, Freedom RM, et al. Independent factors associated with longevity of prosthetic pulmonary valves and valved conduits. J Thorac Cardiovasc Surg. 2000;120(6):1022–30.
95. Albert JD, Bishop DA, Fullerton DA, Campbell DN, Clarke DR. Conduit reconstruction of the right ventricular outflow tract. Lessons learned in a twelve-year experience. J Thorac Cardiovasc Surg. 1993;106(2):228–35.
96. Baskett RJ, Ross DB, Nanton MA, Murphy DA. Factors in the early failure of cryopreserved homograft pulmonary valves in children: preserved immunogenicity? J Thorac Cardiovasc Surg. 1996;112(5):1170–8.
97. Pibarot P, Dumesnil JG. Prosthetic heart valves: selection of the optimal prosthesis and long-term management. Circulation. 2009;119(7):1034–48.
98. Lee C, Park CS, Lee CH, Kwak JG, Kim SJ, Shim WS, et al. Durability of bioprosthetic valves in the pulmonary position: long-term follow-up of 181 implants in patients with congenital heart disease. J Thorac Cardiovasc Surg. 2011;142(2):351–8.
99. Shinkawa T, Anagnostopoulos PV, Johnson NC, Watanabe N, Sapru A, Azakie A. Performance of bovine pericardial valves in the pulmonary position. Ann Thorac Surg. 2010;90(4):1295–300.
100. Chen PC, Sager MS, Zurakowski D, Pigula FA, Baird CW, Mayer JE, et al. Younger age and valve oversizing are predictors of structural valve deterioration after pulmonary valve replacement in patients with tetralogy of Fallot. J Thorac Cardiovasc Surg. 2012;143(2):352–60.
101. McKenzie ED, Khan MS, Dietzman TW, Guzmán-Pruneda FA, Samayoa AX, Liou A, et al. Surgical pulmonary valve replacement: a benchmark for outcomes comparisons. J Thorac Cardiovasc Surg. 2014;148(4):1450–3.
102. Butany J, Feng T, Luk A, Law K, Suri R, Nair V. Modes of failure in explanted mitroflow pericardial valves. Ann Thorac Surg. 2011;92(5):1621–7.
103. Nomoto R, Sleeper LA, Borisuk MJ, Bergerson L, Pigula FA, Emani S, et al. Outcome and performance of bioprosthetic pulmonary valve replacement in patients with congenital heart disease. J Thorac Cardiovasc Surg. 2016;152(5):1333–42.e3.
104. Bonhoeffer P, Boudjemline Y, Saliba Z, Merckx J, Aggoun Y, Bonnet D, et al. Percutaneous replacement of pulmonary valve in a right-ventricle to pulmonary-artery prosthetic conduit with valve dysfunction. Lancet. 2000;356(9239):1403–5.
105. Feltes TF, Bacha E, Beekman RH, Cheatham JP, Feinstein JA, Gomes AS, et al. Indications for cardiac catheterization and intervention in pediatric cardiac disease: a scientific statement from the American Heart Association. Circulation. 2011;123(22):2607–52.
106. Gillespie MJ, Rome JJ, Levi DS, Williams RJ, Rhodes JF, Cheatham JP, et al. Melody valve implant within failed bioprosthetic valves in the pulmonary position: a multicenter experience. Circ Cardiovasc Interv. 2012;5(6):862–70.
107. Webb JG, Wood DA, Ye J, Gurvitch R, Masson JB, Rodés-Cabau J, et al. Transcatheter valve-in-valve implantation for failed bioprosthetic heart valves. Circulation. 2010;121(16):1848–57.
108. Cheatham SL, Holzer RJ, Chisolm JL, Cheatham JP. The Medtronic melody® transcatheter pulmonary valve implanted at 24-mm diameter–it works. Catheter Cardiovasc Interv. 2013;82(5):816–23.
109. Meadows JJ, Moore PM, Berman DP, Cheatham JP, Cheatham SL, Porras D, et al. Use and performance of the melody Transcatheter pulmonary valve in native and postsurgical, nonconduit right ventricular outflow tracts. Circ Cardiovasc Interv. 2014;7(3):374–80.
110. Coats L, Khambadkone S, Derrick G, Sridharan S, Schievano S, Mist B, et al. Physiological and clinical consequences of relief of right ventricular outflow tract obstruction late after repair of congenital heart defects. Circulation. 2006;113(17):2037–44.
111. Plymen CM, Bolger AP, Lurz P, Nordmeyer J, Lee TY, Kabir A, et al. Electrical remodeling following percutaneous pulmonary valve implantation. Am J Cardiol. 2011;107(2):309–14.
112. Khambadkone S, Coats L, Taylor A, Boudjemline Y, Derrick G, Tsang V, et al. Percutaneous pulmonary valve implantation in humans: results in 59 consecutive patients. Circulation. 2005;112(8):1189–97.
113. Morray BH, McElhinney DB, Boudjemline Y, Gewillig M, Kim DW, Grant EK, et al. Multicenter Experience Evaluating Transcatheter Pulmonary Valve Replacement in Bovine Jugular Vein (Contegra) Right Ventricle to Pulmonary Artery Conduits. Circ Cardiovasc Interv. 2017;10(6).
114. Lurz P, Nordmeyer J, Giardini A, Khambadkone S, Muthurangu V, Schievano S, et al. Early versus late functional outcome after successful percutaneous pulmonary valve implantation: are the acute effects of altered right ventricular loading all we can expect? J Am Coll Cardiol. 2011;57(6):724–31.
115.• Cheatham JP, Hellenbrand WE, Zahn EM, Jones TK, Berman DP, Vincent JA, et al. Clinical and hemodynamic outcomes up to 7 years after transcatheter pulmonary valve replacement in the US melody valve investigational device exemption trial. Circulation. 2015;131(22):1960–70. **One of the three main trials that provided follow-up data in patients receiving the Melody valve. Good clinical and hemodynamic outcomes were demonstrated up to 7 years following implantation. The main cause for valve failure was stenosis due to stent fracture**
116. McElhinney DB, Cheatham JP, Jones TK, Lock JE, Vincent JA, Zahn EM, et al. Stent fracture, valve dysfunction, and right ventricular outflow tract reintervention after transcatheter pulmonary valve implantation: patient-related and procedural risk factors in the US melody valve trial. Circ Cardiovasc Interv. 2011;4(6):602–14.
117. McElhinney DB, Hellenbrand WE, Zahn EM, Jones TK, Cheatham JP, Lock JE, et al. Short- and medium-term outcomes after transcatheter pulmonary valve placement in the expanded multicenter US melody valve trial. Circulation. 2010;122(5):507–16.
118. Ewert P, Horlick E, Berger F. First implantation of the CE-marked transcatheter Sapien pulmonic valve in Europe. Clin Res Cardiol. 2011;100(1):85–7.
119. Haas NA, Moysich A, Neudorf U, Mortezaeian H, Abdel-Wahab M, Schneider H, et al. Percutaneous implantation of the Edwards SAPIEN(™) pulmonic valve: initial results in the first 22 patients. Clin Res Cardiol. 2013;102(2):119–28.
120. Wilson WM, Benson LN, Osten MD, Shah A, Horlick EM. Transcatheter pulmonary valve replacement with the Edwards Sapien system: the Toronto experience. JACC Cardiovasc Interv. 2015;8(14):1819–27.
121. Fraisse A, Assaidi A, Mauri L, Malekzadeh-Milani S, Thambo JB, Bonnet D, et al. Coronary artery compression during intention to treat right ventricle outflow with percutaneous pulmonary valve implantation: incidence, diagnosis, and outcome. Catheter Cardiovasc Interv. 2014;83(7):E260–8.
122. Morray BH, McElhinney DB, Cheatham JP, Zahn EM, Berman DP, Sullivan PM, et al. Risk of coronary artery compression among patients referred for transcatheter pulmonary valve implantation: a multicenter experience. Circ Cardiovasc Interv. 2013;6(5):535–42.
123.• Lindsay I, Aboulhosn J, Salem M, Levi D. Aortic root compression during transcatheter pulmonary valve replacement. Catheter Cardiovasc Interv. 2016;88(5):814–21. **A retrospective study of 174 patients who underwent transcatheter pulmonic valve replacement. Intra-procedural aortic root compression occurred in 9% of the patients, and 31% of those had concomitant coronary compression. Most of cases of aortic root compression occurred in TOF with native or transannular-patched RVOT**

124. Levi DS, Sinha S, Salem MM, Aboulhosn JA. Transcatheter native pulmonary valve and tricuspid valve replacement with the sapien XT: initial experience and development of a new delivery platform. Catheter Cardiovasc Interv. 2016;88(3):434–43.
125. Porras D, Gurvitz M, Marshall AC, Emani SM. Hybrid approach for off-pump pulmonary valve replacement in patients with a dilated right ventricular outflow tract. Ann Thorac Surg. 2015;100(5):e99–101.
126. Chen Q, Turner M, Caputo M, Stoica S, Marianeschi S, Parry A. Pulmonary valve implantation using self-expanding tissue valve without cardiopulmonary bypass reduces operation time and blood product use. J Thorac Cardiovasc Surg. 2013;145(4): 1040–5.
127.• Sizarov A, Boudjemline Y. Novel materials and devices in the transcatheter management of congenital heart diseases-the future comes slowly (part 3). Arch Cardiovasc Dis. 2016;109(5):348–58. **An excellent review providing insight into the future advancements in transcatheter interventions. One of the techniques described involves placing RVOT reducers/fillers to create smaller landing zones for implanting transcatheter pulmonic valves**
128. Schoonbeek RC, Takebayashi S, Aoki C, Shimaoka T, Harris MA, Fu GL, et al. Implantation of the Medtronic Harmony Transcatheter Pulmonary Valve Improves Right Ventricular Size and Function in an Ovine Model of Postoperative Chronic Pulmonary Insufficiency. Circ Cardiovasc Interv. 2016;9(10).
129.• Promphan W, Prachasilchai P, Siripornpitak S, Qureshi SA, Layangool T. Percutaneous pulmonary valve implantation with the Venus P-valve: clinical experience and early results. Cardiol Young. 2016;26(4):698–710. **This study reports early experience with a new self-expanding transcatheter valve, the Venus P-valve. All 6 patients described had severe PR with large RVOTs (range 24-32mm). The valve was successfully implanted in all patients, but unexpected mild proximal valve migration occurred in one patient and resulted in mild paravalvar leak and significant tricuspid regurgitation**
130. Schlegel F, Salameh A, Oelmann K, Halling M, Dhein S, Mohr FW, et al. Injectable tissue engineered pulmonary heart valve implantation into the pig model: a feasibility study. Med Sci Monit Basic Res. 2015;21:135–40.