



# Cervical, Thoracic, and Spinopelvic Compensation After Proximal Junctional Kyphosis (PJK): Does Location of PJK Matter?

Global Spine Journal  
2020, Vol. 10(1) 6-12  
© The Author(s) 2019  
Article reuse guidelines:  
sagepub.com/journals-permissions  
DOI: 10.1177/2192568219879085  
journals.sagepub.com/home/gsj



Han Jo Kim<sup>1</sup> , Philip J. York<sup>1</sup>, Jonathan C. Elysee<sup>1</sup>, Christopher Shaffrey<sup>2</sup>, Douglas C. Burton<sup>3</sup>, Christopher P. Ames<sup>4</sup>, Gregory M. Mundis Jr<sup>5</sup>, Richard Hostin<sup>6</sup>, Shay Bess<sup>7</sup>, Eric Klineberg<sup>8</sup>, Justin S. Smith<sup>9</sup>, Peter Passias<sup>10</sup>, Frank Schwab<sup>1</sup>, Renaud Lafage<sup>1</sup> , and the International Spine Study Group(ISSG)

## Abstract

**Study Design:** Retrospective case series.

**Objective:** Compensatory changes above a proximal junctional kyphosis (PJK) have not been defined. Understanding these mechanisms may help determine optimal level selection when performing revision for PJK. This study investigates how varying PJK location changes proximal spinal alignment.

**Methods:** Patients were grouped by upper instrumented vertebrae (UIV): lower thoracic (LT; T8-L1) or upper thoracic (UT; T1-7). Alignment parameters were compared. Correlation analysis was performed between PJK magnitude and global/cervical alignment.

**Results:** A total of 369 patients were included; mean age of 63 years, body mass index 28, and 81% female, LT (n = 193) versus UT (n = 176). The rate of radiographic PJK was 49%, higher in the LT group (55% vs 42%,  $P = .01$ ). The UT group displayed significant differences in all cervical radiographic parameters ( $P < .05$ ) between PJK versus non-PJK patients, while the LT group displayed significant differences in T1S and C2-T3 sagittal vertical axis (SVA) (CTS). In comparing UT versus LT patients, UT had more posterior global alignment (smaller TPA [T1 pelvic angle], SVA, and larger PT [pelvic tilt]) and larger anterior cervical alignment (greater cSVA [cervical SVA], TIS-CL [T1 slope–cervical lordosis] mismatch, CTS) compared to LT. Correlation analysis of PJK magnitude and location demonstrated a correlation with increases in CL, TIS, and CTS in the UT group. In the LT group, PT increased with PJK angle ( $r = 0.17$ ) and no significant correlations were noted to SVA, cSVA, or TIS-CL.

**Conclusions:** PJK location influences compensation mechanisms of the cervical and thoracic spine. LT PJK results in increased PT and CL with decreased CTS. UT PJK increases CL to counter increases in TIS with continued TIS-CL mismatch and elevated cSVA.

<sup>1</sup> Hospital for Special Surgery, New York, NY, USA

<sup>2</sup> Duke University, Raleigh, NC, USA

<sup>3</sup> University of Kansas Medical Center, Kansas City, KS, USA

<sup>4</sup> University of California San Francisco, CA, USA

<sup>5</sup> San Diego Center for Spinal Disorders, La Jolla, CA, USA

<sup>6</sup> Baylor Scoliosis Center, Plano, TX, USA

<sup>7</sup> Rocky Mountain Hospital for Children, Presbyterian/St Luke's Medical Center, Denver, CO, USA

<sup>8</sup> University of California Davis, Sacramento, CA, USA

<sup>9</sup> University of Virginia, Charlottesville, VA, USA

<sup>10</sup> New York University School of Medicine, New York, NY, USA

## Corresponding Author:

Han Jo Kim, Department of Orthopaedics, Hospital for Special Surgery, New York, NY 10021, USA.

Email: KimH@hss.edu



Creative Commons Non Commercial No Derivs CC BY-NC-ND: This article is distributed under the terms of the Creative Commons Attribution-NonCommercial-NoDerivs 4.0 License (<https://creativecommons.org/licenses/by-nc-nd/4.0/>) which permits non-commercial use, reproduction and distribution of the work as published without adaptation or alteration, without further permission provided the original work is attributed as specified on the SAGE and Open Access pages (<https://us.sagepub.com/en-us/nam/open-access-at-sage>).

## Keywords

cervical deformity, thoracic compensation, spinopelvic compensation, proximal junctional kyphosis, complications, radiographic evaluation

## Introduction

Proximal junctional kyphosis (PJK) is a frequent challenge for the deformity surgeon, and numerous recent scientific efforts have resulted in an increase in the general understanding of its etiology and its long-term effects.<sup>1-4</sup> In a sense, much of the current research in this arena began at the base of the spine with defining normal versus abnormal lumbopelvic parameters and subsequently identifying primary deformities from compensatory changes. Building on that framework has allowed for a more robust understanding of the global analysis of spinal alignment and compensation. Understanding compensatory mechanisms and the effect that they have on patient's quality of life and functional abilities is paramount in the growing field of deformity surgery. Previous efforts, in terms of identifying lumbopelvic and full body compensation, have resulted in improved surgical alignment goals built around obtaining superior patient outcomes.<sup>5-9</sup> As the cumulative data has grown, some authors have hypothesized that the development of PJK itself could be seen as a compensatory mechanism in the setting of overcorrection.<sup>5,10</sup>

In terms of interplay between thoracolumbar alignment and cervical spine, a number of reciprocal adjacent level and regional changes in cervical alignment following deformity correction have been described.<sup>8,11,12</sup> For example, patients with thoracolumbar (TL) sagittal malalignment have been found to have a high incidence of cervical hyperlordosis, which tends to correct following correction of the TL deformity.<sup>13</sup> As such, patients with a preoperative sagittal vertical axis (SVA) >9 cm exhibit a decrease in cervical lordosis (CL) following thoracolumbar deformity correction.<sup>14</sup> Additionally, there has been recent evidence that there is varying impact on proximal spinal compensatory mechanisms based on upper instrumented vertebrae (UIV). It was recently observed that PJK patients with upper thoracic (UT) UIV tend to have greater cervical sagittal deformity with greater C2-C7 plumbline (CPL) and cervicothoracic pelvic angle (CTPA) compared with patients with lower thoracic (LT) UIV who develop PJK.<sup>15</sup> When comparing patients that developed PJK to non-PJK patients, Passias et al<sup>16</sup> reported an incidence of new-onset cervical deformity (CD) in 15% of patients that had developed PJK and that patients with greater preoperative T1S and C2-T3 Cobb angles had increased risk for PJK development. However, our understanding of the effect that PJK has on sagittal compensatory changes proximal to the focal deformity remains limited.

Compensatory mechanisms that are seen both preoperatively in primary adult spinal deformities or postoperatively following limited or long fusion provide a great deal of information for the treating surgeon. The mechanisms and goals of the compensation can provide information regarding the degree of disability that a patient might have and, in some cases, has

been shown to correlate to quality of life and patient-reported outcomes.<sup>11,17,18</sup> Furthermore, compensatory changes versus intrinsic deformities can influence decision making regarding the required degree of deformity correction if surgery is ultimately undertaken to correct it.<sup>6</sup> While it is increasingly evident that there is a relationship between PJK and the development of radiographically apparent CD, the expected cervical and cervicothoracic compensatory mechanisms following PJK have not been characterized. Understanding these mechanisms might be particularly helpful in planning for revision surgeries in the setting of PJK, especially if particular radiographic features could provide predictive markers for PJK or CD. The purpose of the current study was to delineate patterns of reciprocal change and global and regional compensatory mechanisms in adult spinal deformity (ASD) patients following deformity correction based on the development and location of PJK.

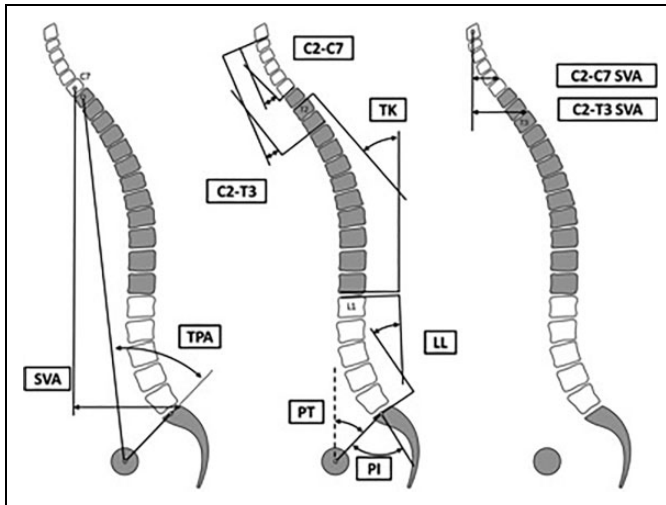
## Method

### Study Sample

This study was a retrospective review of a multicenter database of ASD patients. Patients were enrolled into the ongoing database through an institutional review board–approved protocol across all centers. Inclusion criteria for the database were age >18 years and radiographic criteria for ASD defined as having at least one of the following: coronal Cobb angle  $\geq 20^\circ$ , SVA  $\geq 5$  cm, pelvic tilt (PT)  $\geq 25^\circ$ , or thoracic kyphosis (TK)  $\geq 60^\circ$ . Inclusion criteria specific for the study were patients eligible for 2-year follow-up that had fusions >5 levels with the LIV being S1/Ilium. We then compared those patients with and without PJK for a general analysis of the cohort. The PJK cohort was then further subdivided and analyzed based on the location of the PJK. The location was designated as being either an UT or a LT PJK. Then, alignment parameters cranial to the area of PJK were compared between the PJK location cohorts. The radiographic measurements collected are specified below.

### Data Collection

The database, compiled from demographic and radiographic data collected at each site, includes demographic data such as age, gender, and BMI (body mass index). All patients had full-length, free-standing spine radiographs including the femoral heads (ie, conventional 36" shoulder to pelvis, full-length EOS, etc). Radiographic parameters were obtained utilizing a dedicated and validated software<sup>19</sup> (Spineview, ENSAM Laboratory of Biomechanics, Paris), and post-treated with Matlab software (Version R2015b; MathWorks, Inc, Natick, MA).



**Figure 1.** Radiographic parameters collected: sagittal vertical axis (SVA), T1 pelvic angle (TPA), pelvic incidence (PI), pelvic tilt (PT), PI minus LL, T2-T12 thoracic kyphosis (TK), C2-T3 cervicothoracic curvature (C2-T3), C2-T3 plumbline (C2-T3 SVA), C2-C7 cervical curvature (C2-C7), and C2-C7 plumbline (C2-C7 SVA).

Classic spinopelvic parameters were evaluated including pelvic incidence (PI), sacral slope (SS), lumbar lordosis (LL), PI – LL, T1 pelvic angle (TPA), and SVA (Figure 1). Additionally, cervical and cervicothoracic parameters were obtained including T1 slope (TS), both C2-C7 and C2-T3 Cobb angles and SVA, T1S-CL, and C2 slope. Proximal junctional angle (PJA) was defined as a sagittal Cobb angle between the inferior endplate of the UIV and the superior endplate of UIV+2.

Radiographic PJK was defined according to Glattes definition<sup>20</sup>: kyphotic PJK angle greater than 10° associated with a kyphotic change greater than 10° between preoperative and postoperative alignment.

### Statistical Analysis

Analysis began by evaluating preoperative demographic data and radiographic alignment. Postoperative alignment and evaluation of the degree of surgical correction and the proximal reciprocal change were determined. The overall rate of PJK was calculated. Comparisons of demographic information and pre- and postoperative alignment were conducted between PJK and non-PJK patients.

The cohorts were further stratified into lower thoracic UIV (LT UIV = T7-L1) or upper thoracic UIV (UP UIV = T1-T7). Alignment parameters were compared between PJK and non-PJK within UIV groups as well as between UT and LT within PJK group utilizing ANOVA and Fisher's least significant difference post hoc analysis.

Association between sagittal alignment and magnitude of the focal deformity was investigated using bivariate Pearson's correlations for the entire cohort as well as within both UIV groups.

**Table 1.** Pre-operative SRS-Schwab Classification for the entire cohort

	0	+	++
PT modifier	25.80%	42.00%	32.20%
PI – LL modifier	27.90%	25.50%	46.60%
SVA modifier	32.00%	31.20%	36.80%

Abbreviations: SRS, Scoliosis Research Society; PT, pelvic tilt; PI, pelvic incidence; LL, lumbar lordosis; SVA, sagittal vertical axis.

**Table 2.** Pre-to-Post Analysis of the Classic Spinopelvic Parameters for the Entire Cohort

	Pre	Post	Δ	P
PI	54.5 ± 14.9	54 ± 17.7		.374
PT	26.1 ± 10.1	22.5 ± 9.9	3.5 ± 8.4°	<.001
PI – LL	20.4 ± 21.2	2.7 ± 19.3	17.6 ± 18.4°	<.001
TK	-33.8 ± 17.6	-52.7 ± 17.5	18.9 ± 14.0°	<.001
TPA	25.8 ± 12.5	18.6 ± 10.7	7.2 ± 10.8°	<.001
SVA	79.8 ± 72.8	33.3 ± 53.9	47 + 66	<.001

Abbreviations: PI, pelvic incidence; PT, pelvic tilt; LL, lumbar lordosis; TK, thoracic kyphosis; TPA, T1 pelvic angle; SVA, sagittal vertical axis.

Finally, rate of development of radiographic alignment meeting the criteria for cervical deformity (CD), defined based on classic definitions including C2-C7 SVA (cSVA) greater than 4 cm, or kyphotic C2-C7 lordosis (CL), was reported for the entire cohort as well as within each PJK group and by UIV position (UT vs LT).

## Results

### Cohort Description

Of 496 eligible patients, 363 had sufficient data to be included on the analysis (73.2%; mean age 62.66 ± 10.1, mean BMI 28.05 ± 5.6, 80.9% female). While bone mineral density (BMD) data was not available, 15.8% of patients had a preoperative diagnosis of osteoporosis. On average, the cohort demonstrated preoperative alignment categorized as moderate to severe sagittal deformity based on the Scoliosis Research Society (SRS) Schwab classification (Table 1). All patients underwent a posterior approach while 117 (32%) also underwent some form of anterior fusion as well.

At 2 years postoperatively, there were significant improvements seen in the preoperative to postoperative alignment parameters (Table 2). On average, PT decreased by 3.5 ± 8.4°, PI – LL by 17.6 ± 18.4°, TPA by 7.2 ± 10.8°, SVA by 47 ± 66 mm, while TK increased by 18.9 ± 14.0°.

At the 2-year follow-up, 193 patients (52.3%) had a LT UIV (T10: 115 [59.6%]; T11: 40 [20.7%]; T9: 21 [10.9%]) and 176 (47.7%) had an UT UIV (T4: 70 [39.8%]; T3: 67 [38.1%]; T2: 15 [8.5%]). The rate of radiographic PJK at 2 years was 49.1% (181 patients) with a significant higher rate on LT UIV patients (55.4% vs 42%;  $P = .010$ ).

**Table 3.** Comparison of Postoperative Cervical and Cervicothoracic Alignment Between Patients With and Without Development of Radiographic PJK

	PJK	No-PJK	P
TS	30.8 ± 13.2	36.8 ± 13.0	<.001
CL	10.2 ± 15.9	14.4 ± 15.7	<.012
C2-7 SVA	29 ± 15	34 ± 14	<.001
C2-T3 SVA	61 ± 25	73 ± 23	<.001
C2 Slope	18.0 ± 11.9	20.8 ± 11.7	<.001
TS-CL	20.2 ± 11.9	22.5 ± 11.2	.066
C2-T3 Cobb	7.1 ± 16.8	7.5 ± 17.5	.86

Abbreviations: PJK, proximal junctional kyphosis; TS, T1 slope; CL, cervical lordosis; SVA, sagittal vertical axis.

### Comparison Between PJK and No PJK Patients

Patients who were identified as having developed radiographic PJK at their final follow-up were significantly older than those who did not (no-PJK;  $61.1 \pm 10.9$  vs  $64.3 \pm 8.9$ ,  $P = .002$ ). There were no significant differences in BMI (27.6 vs 28.6), gender (79% females vs 82.9% females), osteoporosis (13.3% vs 18.3%), or any preoperative alignment parameters (all  $P > .05$ ).

At the latest follow-up, the PJK patients had larger TK ( $-57.5 \pm 16.3$  vs  $-48.1 \pm 17.4$ ,  $P < .001$ ) with no significant differences in any other thoracolumbar parameters (PI, PT, PI – LL, SVA, and TPA). The PJK patients, however, were found to exhibit significant differences in a number of cervical and cervicothoracic alignment parameters including TS, CL, C2-7 SVA, C2-T3 SVA, and C2 Slope (Table 3).

### Stratification by UIV Position

**Upper Thoracic.** Within patients in the UT group, the only postoperative significant difference in thoracolumbar parameters was seen in a significantly larger TK and associated smaller TPA in PJK patients. These patients, however, exhibited significantly larger T1 slope, a more anterior cervical spine alignment with increased C2-C7 SVA, which was associated with a more lordotic C2-C7 Cobb (Table 4).

**Lower Thoracic.** There were no postoperative significant differences seen in thoracolumbar alignment between LT patients who did and who did not develop PJK with the exception of a larger TK for PJK patients. Unlike the UT group, in terms of cervical and cervicothoracic parameters there were significant differences only in T1S and C2-T3 SVA with no significant differences in any of the other parameters (Table 4).

**Comparison LT PJK and UT PJK.** When comparing LT PJK and UT PJK patients, there were several findings. The UT PJK group demonstrated more posterior sagittal alignment with a smaller TPA ( $15.4 \pm 11.2$  vs  $20.3 \pm 9.6$ ,  $P = .002$ ) and smaller SVA ( $17 \pm 53$  vs  $42 \pm 49$ ,  $P = .002$ ). Greater pelvic retroversion was seen in the LT PJK group (PT:  $20.9 \pm 11.0$  vs  $23.9 \pm 9.5$ ,  $P = .043$ ). Overall, the UT group demonstrated greater cervical

compensation in every parameter compared to the LT PJK patients.

### Association Between Focal Deformity and Post-operative Alignment

In the cohort as a whole, an association was seen between the postoperative PJA and the overall postoperative sagittal alignment. Specifically, increasing PJA was associated with smaller PI – LL, higher T1S, and greater CL with a higher cSVA (cervical SVA). After stratifying by UIV position, increased PJA in UT UIV was associated with more posterior global alignment (higher PI – LL, TK, TPA, and SVA), whereas in the LT UIV there was a negative correlation between increasing PJA and PT, TK, and TPA.

The relationship between PJA and cervical and cervicothoracic parameters was similar between groups with a positive correlation between PJA and higher CL. In the UT UIV group, there was a significant negative correlation between T1S-CL, C2 slope, and C2-C7 SVA, not seen in the LT group, and conversely the LT exhibited a negative correlation between increased PJA and C2-T3 Cobb, not seen in the UT group (Table 5).

### Criteria for Cervical Deformity and PJK Location

Overall, 141 patients (38.2%) could be radiographically classified as having CD based on classic definitions either by exhibiting an overall kyphotic cervical alignment ( $CL \leq 0$ ; 50 patients, 13.6%), cSVA of greater than 4 cm (69 patients, 18.7%), or patients that met both criteria (22 patients, 6%). PJK patients exhibited a greater rate of meeting one or both of these criteria overall, a rate that was highest among patients with UT UIV and most commonly demonstrated in a greater cSVA compared with patients with LT UIV (Figure 2).

### Discussion

The present study evaluates the overall rate of patients that meet classic radiographic criteria of CD and cervicothoracic malalignment in ASD patients following deformity correction in an attempt to delineate and define compensatory mechanisms that occur following PJK. Additionally, we focused on determining the changes based on PJK location (UT vs LT UIV) in order to better understand the variations in compensation that occur. The present analysis revealed an overall rate of PJK of 49%, similar to reported values in the current literature<sup>2,5</sup> with a significantly higher rate seen in LT UIV patients (55.4% vs 42%;  $P = .01$ ). The importance of our findings was in better defining the compensatory changes that occur following PJK at different levels of UIV (Figure 3). Our data suggests that UT PJK patients exhibit compensatory changes in cervical alignment with significant differences noted in all cervical radiographic parameters between PJK and non-PJK patients. In these patients, there is a tendency to utilize cervical and

**Table 4.** Postoperative Comparison Between PJK and No-PJK Patient by UIV Position as Well as the Comparison Between UT PJK and LT PJK Postoperative Alignment<sup>a</sup>.

		Upper Thoracic			Lower Thoracic			UT PJK vs LT PJK
		No-PJK	PJK	P	No-PJK	PJK	P	
Thoracolumbar alignment	PI	55.9 ± 12.9	51.6 ± 24.7	.111	54.2 ± 21.5	53.7 ± 11.6	.837	.430
	PT	23 ± 10.3	20.9 ± 11	.160	21.7 ± 8.6	23.9 ± 9.5	.123	<b>.043</b>
	PI-LL	5.5 ± 17.7	-0.1 ± 23.7	.058	2.5 ± 22.7	2.2 ± 13.6	.902	.442
	TK	-49.4 ± 17.8	-59 ± 17.1	<b>.000</b>	-46.5 ± 16.8	-56.4 ± 15.8	<b>.000</b>	.306
	TPA	18.8 ± 11.7	15.4 ± 11.2	<b>.034</b>	18.8 ± 9.8	20.3 ± 9.6	.336	<b>.002</b>
	SVA	31.1 ± 58.7	16.9 ± 52.6	.083	39.7 ± 52.8	41.8 ± 48.6	.791	<b>.002</b>
Cervical/cervicothoracic alignment	T1 slope	32 ± 13.7	42 ± 13.5	<b>.000</b>	29.4 ± 12.4	33.2 ± 11.4	<b>.039</b>	<b>.000</b>
	C2-C7 Cobb	11 ± 15.6	16.6 ± 16.3	<b>.023</b>	9.3 ± 16.3	13 ± 15.1	.111	.134
	C2-C7 SVA	30.6 ± 14.4	38.4 ± 13.8	<b>.000</b>	27.1 ± 15.2	30.8 ± 12.8	.074	<b>.000</b>
	C2-T3 Cobb	7.7 ± 15.5	1.6 ± 18	<b>.022</b>	6.6 ± 18.3	11.5 ± 16.1	.050	<b>.000</b>
	C2-T3 SVA	64 ± 24.6	82.4 ± 22.7	<b>.000</b>	57.6 ± 24.5	66.5 ± 20.7	<b>.009</b>	<b>.000</b>
	TS-CL	20.5 ± 11.5	25.6 ± 10	<b>.004</b>	19.9 ± 11.9	20.4 ± 11.5	.781	<b>.003</b>
	C2 slope	18.3 ± 11.7	24 ± 10.5	<b>.002</b>	17.6 ± 12.3	18.6 ± 12	.579	<b>.002</b>

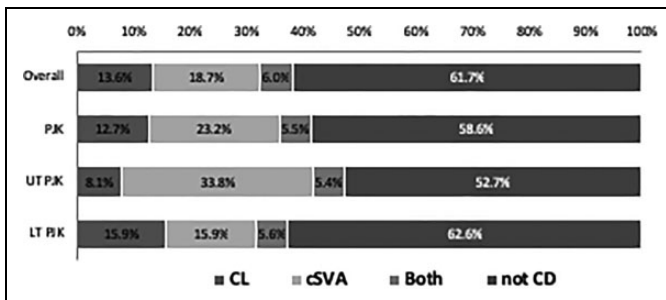Abbreviations: PJK, proximal junctional kyphosis; UT, upper thoracic; LT, lower thoracic; PI, pelvic incidence; PT, pelvic tilt; LL, lumbar lordosis; TK, thoracic kyphosis; TPA, T1 pelvic angle; SVA, sagittal vertical axis; TS, T1 slope; CL, cervical lordosis.

<sup>a</sup>Comparison in bold denoted a significant difference.

**Table 5.** Correlation Coefficient Between Proximal Junctional Angle (PJA) and Sagittal Parameters for the Entire Cohort as Well as by Upper Instrumented Vertebrae (UIV) Position.

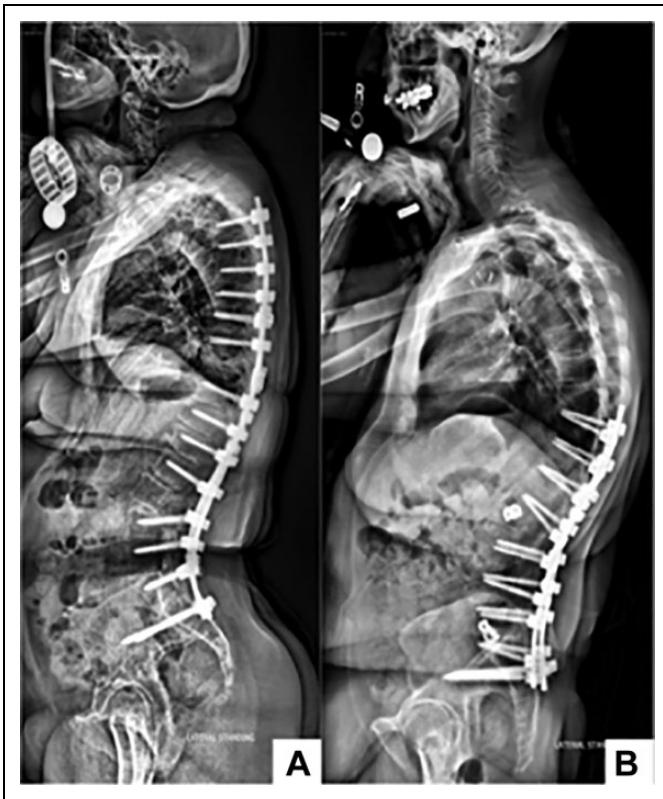		All		Upper Thoracic		Lower Thoracic	
		r	P	r	P	r	P
Thoracolumbar alignment	PT	ns	.396	ns	.232	-0.167	.021
	PI – LL	0.146	.005	0.214	.004	ns	.283
	TK	0.562	.000	0.534	.000	0.616	.000
	TPA	ns	.892	0.172	.022	-0.157	.029
	SVA	ns	.919	0.183	.015	ns	.098
Cervical/cervicothoracic alignment	T1 slope	-0.420	.000	-0.587	.000	-0.335	.000
	C2-C7 Cobb	-0.348	.000	-0.436	.000	-0.301	.000
	C2-C7 SVA	-0.179	.001	-0.353	.000	ns	.244
	C2-T3 Cobb	-0.227	.000	ns	.964	-0.388	.000
	C2-T3 SVA	-0.354	.000	-0.546	.000	-0.257	.000
	TS-CL	ns	.659	-0.153	.047	ns	.513
	C2 slope	ns	.422	-0.174	.024	ns	.697

Abbreviations: PT, pelvic tilt; PI, pelvic incidence; LL, lumbar lordosis; TK, thoracic kyphosis; TPA, T1 pelvic angle; SVA, sagittal vertical axis; TS, T1 slope; CL, cervical lordosis.



**Figure 2.** Proportion of patients with cervical deformity according to classic radiographic definition.

cervicothoracic motion to keep their head level and to maintain horizontal gaze. As might be expected, patients who had an UT PJK exhibited significantly lower SVA compared with patients in the LT group, and thus, the recruitment of distal compensatory changes such as increases in pelvic tilt via pelvic retroversion were not commonly displayed. Overall, this analysis suggests that UT UIV patients tend to exhibit improved thoracolumbar sagittal alignment (ie, SVA) although the narrower proximal segment available for compensatory change increases the likelihood that subsequent PJK might result in compensatory cervicothoracic compensation that falls within the radiographic criteria of CD.



**Figure 3.** Radiographic case examples of patients recruiting different compensatory mechanisms depending on the location of PJK (proximal junctional kyphosis). (A) Upper thoracic PJK with maximal extension of cervical lordosis. (B) Lower thoracic PJK with increased pelvic tilt, decreased thoracic kyphosis, and increased cervical lordosis.

Conversely, PJK patients in the LT UIV group exhibited significantly greater values only in 2 cervicothoracic parameters (T1S and C2-T3 SVA) but had more anterior global alignment (ie, SVA, TPA), which requires greater spinopelvic compensation with greater pelvic retroversion (increased pelvic tilt) in an attempt to maintain overall sagittal alignment. In these patients, with the primary compensation requirement being to move the center of gravity more posterior, a distal compensatory effort provides a much greater lever arm and decreases the proximal compensatory requirements that are seen in the UT patients. With their overall more posterior global alignment, an increase in CL is not required to maintain horizontal gaze as is the case in the UT group.

In terms of proximal alignment, T1S has been shown previously to be a predictor of overall cervical sagittal alignment.<sup>21,22</sup> The results of the present study support these previous findings and further suggest that among patients with PJK, there is a significant correlation between the degree of focal deformity (ie, PJA) and the T1S with an associated positive correlation with CL and anterior cervical or cervicothoracic sagittal alignment. This was irrespective of UT or LT UIV (Table 5).

There are a number of limitations to the present study. First, the factors considered for choosing an UT versus a LT UIV

could not be determined, which might influence a patient's compensatory abilities and could confound the results as various concomitant medical and functional considerations have been shown to influence the rate and presentation of PJK.<sup>23</sup> However, this information does provide additional groundwork going forward for efforts aimed to determine specific methods of surgical planning and intraoperative techniques to prevent deleterious postoperative compensatory changes based on risk stratification for PJK and the likelihood of untoward proximal changes. Additionally, factors such as osteoporosis could not be controlled for as BMD data was not available. Although we found no significant difference in the preoperative diagnosis of osteoporosis, this certainly may have been underreported. Associating these findings with the effect that they might have on patient reported outcomes would be the next step.

## Conclusions

PJK location has an effect on global and regional compensatory mechanisms throughout the spine and spinopelvic segments. Patients that develop PJK after ASD correction with a LT PJK exhibit both distal spinopelvic and proximal cervicothoracic compensation with an increase in PT and increases in T1S and CTS, respectively. This differs from the compensatory changes seen following ASD correction with a more proximal UIV which exhibits primarily proximal changes requiring significant compensatory increase in CL to counter an increase in T1S with resultant T1S-CL mismatch and an elevated cSVA. These patterns of compensation can provide insight into the methods utilized by these patients in order to compensate for PJK in the unfused segments above. Patients who do not exhibit these expected patterns may need special consideration when a revision surgery is necessary.


## Declaration of Conflicting Interests


The author(s) declared no potential conflicts of interest with respect to the research, authorship, and/or publication of this article.

## Funding

The author(s) disclosed receipt of the following financial support for the research, authorship, and/or publication of this article: Research funding provided by ISSG Foundation.

## ORCID iD

Han Jo Kim  <https://orcid.org/0000-0003-2170-3592>

Renaud Lafage  <https://orcid.org/0000-0002-4820-1835>

## References

1. Kim HJ, Bridwell KH, Lenke LG, et al. Proximal junctional kyphosis results in inferior SRS pain subscores in adult deformity patients. *Spine (Phila Pa 1976)*. 2013;38:896-901. doi:10.1097/BRS.0b013e3182815b42
2. Kim YJ, Bridwell KH, Lenke LG, Glattes CR, Rhim S, Cheh G. Proximal junctional kyphosis in adult spinal deformity after segmental posterior spinal instrumentation and fusion: minimum

- five-year follow-up. *Spine (Phila Pa 1976)*. 2008;33:2179-2184. doi:10.1097/BRS.0b013e31817c0428
3. Wang J, Zhao Y, Shen B, Wang C, Li M. Risk factor analysis of proximal junctional kyphosis after posterior fusion in patients with idiopathic scoliosis. *Injury*. 2010;41:415-420. doi:10.1016/j.injury.2010.01.001
  4. Kim HJ, Bridwell KH, Lenke LG, et al. Patients with proximal junctional kyphosis requiring revision surgery have higher postoperative lumbar lordosis and larger sagittal balance corrections. *Spine (Phila Pa 1976)*. 2014;39:E576-E580. doi:10.1097/BRS.0000000000000246
  5. Lafage R, Schwab F, Glassman S, et al; International Spine Study Group. Age-adjusted alignment goals have the potential to reduce PJK. *Spine (Phila Pa 1976)*. 2017;(17):1275-1282. doi:10.1097/BRS.00000000000002146
  6. Lafage V, Schwab F, Patel A, Hawkinson N, Farcy JP. Pelvic tilt and truncal inclination: two key radiographic parameters in the setting of adults with spinal deformity. *Spine (Phila Pa 1976)*. 2009;34: E599-E606. doi:10.1097/BRS.0b013e3181aad219
  7. Diebo BG, Ferrero E, Lafage R, et al. Recruitment of compensatory mechanisms in sagittal spinal malalignment is age and regional deformity dependent. *Spine (Phila Pa 1976)*. 2015;40: 642-649. doi:10.1097/BRS.0000000000000844
  8. Obeid I, Hauger O, Aunoble S, Bourghli A, Pellet N, Vital JM. Global analysis of sagittal spinal alignment in major deformities: correlation between lack of lumbar lordosis and flexion of the knee. *Eur Spine J*. 2011;20(suppl 5):681-685. doi:10.1007/s00586-011-1936-x
  9. Protopsaltis TS, Diebo BG, Lafage R, et al; International Spine Study Group. Identifying thoracic compensation and predicting reciprocal thoracic kyphosis and proximal junctional kyphosis in adult spinal deformity surgery. *Spine (Phila Pa 1976)*. 2018;43: 1479-1486. doi:10.1097/BRS.00000000000002843
  10. Lafage R, Bess S, Glassman S, et al; International Spine Study Group. Virtual modeling of postoperative alignment following adult spinal deformity (ASD) surgery helps predict associations between compensatory spinopelvic alignment changes, overcorrection and proximal junctional kyphosis (PJK). *Spine (Phila Pa 1976)*. 2017;42:E119-E125. doi:10.1097/BRS.00000000000002116
  11. Lafage R, Schwab F, Challier V, et al; International Spine Study Group. Defining spino-pelvic alignment thresholds: should operative goals in adult spinal deformity surgery account for age? *Spine (Phila Pa 1976)*. 2016;41:62-68. doi:10.1097/BRS.00000000000001171
  12. Qiao M, Qian BP, Mao SH, Qiu Y, Wang B. The patterns of loss of correction after posterior wedge osteotomy in ankylosing spondylitis-related thoracolumbar kyphosis: a minimum of five-year follow-up. *BMC Musculoskelet Disord*. 2017;18:465. doi:10.1186/s12891-017-1834-4
  13. Smith JS, Shaffrey CI, Lafage V, et al; International Spine Study Group. Spontaneous improvement of cervical alignment after correction of global sagittal balance following pedicle subtraction osteotomy. *J Neurosurg Spine*. 2012;17:300-307. doi:10.3171/2012.6.SPINE1250
  14. Ha Y, Maruo K, Racine L, et al. Proximal junctional kyphosis and clinical outcomes in adult spinal deformity surgery with fusion from the thoracic spine to the sacrum: a comparison of proximal and distal upper instrumented vertebrae. *J Neurosurg Spine*. 2013; 19:360-369. doi:10.3171/2013.5.SPINE12737
  15. Protopsaltis T, Bronsard N, Soroceanu A, et al; International Spine Study Group. Cervical sagittal deformity develops after PJK in adult thoracolumbar deformity correction: radiographic analysis utilizing a novel global sagittal angular parameter, the CTPA. *Eur Spine J*. 2017;26:1111-1120. doi:10.1007/s00586-016-4653-7
  16. Passias PG, Horn SR, Jalai CM, et al. Cervical alignment changes in patients developing proximal junctional kyphosis following surgical correction of adult spinal deformity. *Neurosurgery*. 2018;83:675-682. doi:10.1093/neuros/nyx479
  17. Lau D, Funao H, Clark AJ, et al; International Spine Study Group. The clinical correlation of the Hart-ISSG Proximal Junctional Kyphosis Severity Scale with health-related quality-of-life outcomes and need for revision surgery. *Spine (Phila Pa 1976)*. 2016;41:213-223. doi:10.1097/BRS.0000000000001326
  18. Smith JS, Shaffrey CI, Lafage V, et al; International Spine Study Group. Comparison of best versus worst clinical outcomes for adult spinal deformity surgery: a retrospective review of a prospectively collected, multicenter database with 2-year follow-up. *J Neurosurg Spine*. 2015;23:349-359. doi:10.3171/2014.12.SPINE14777
  19. Champain S, Benchikh K, Nogier A, Mazel C, Guise JD, Skalli W. Validation of new clinical quantitative analysis software applicable in spine orthopaedic studies. *Eur Spine J*. 2006;15: 982-991. doi:10.1007/s00586-005-0927-1
  20. Glattes RC, Bridwell KH, Lenke LG, Kim YJ, Rinella A, Edwards C 2nd. Proximal junctional kyphosis in adult spinal deformity following long instrumented posterior spinal fusion: incidence, outcomes, and risk factor analysis. *Spine (Phila Pa 1976)*. 2005;30:1643-1649. doi:10.1097/01.brs.0000169451.76359.49
  21. Nasto LA, Shalabi ST, Perez-Romera AB, Muquit S, Ghasemi AR, Mehdian H. Analysis of cervical sagittal alignment change following correction of thoracic and thoracolumbar Scheuermann's kyphosis. *Eur Spine J*. 2017;26:2187-2197. doi:10.1007/s00586-017-5069-8
  22. Ames CP, Blondel B, Scheer JK, et al. Cervical radiographical alignment: comprehensive assessment techniques and potential importance in cervical myelopathy. *Spine (Phila Pa 1976)*. 2013;38(22 suppl 1):S149-S160. doi:10.1097/BRS.0b013e3182a7f449
  23. Glassman SD, Coseo MP, Carreon LY. Sagittal balance is more than just alignment: why PJK remains an unresolved problem. *Scoliosis Spinal Disord*. 2016;11:1. doi:10.1186/s13013-016-0064-0