

A Novel Classification System for Spinal Instability in Neoplastic Disease

An Evidence-Based Approach and Expert Consensus From the Spine Oncology Study Group

Charles G. Fisher, MD, MHSc, FRCSC,* Christian P. DiPaola, MD,*
Timothy C. Ryken, MD, MS,† Mark H. Bilsky, MD,‡ Christopher I. Shaffrey, MD,§
Sigurd H. Berven, MD,¶ James S. Harrop, MD,|| Michael G. Fehlings, MD, PhD,**
Stefano Boriani, MD,†† Dean Chou, MD,‡‡ Meic H. Schmidt, MD,§§ David W. Polly, MD,¶¶
Roberto Biagini, MD,||| Shane Burch, MD,¶ Mark B. Dekutoski, MD,*** Aruna Ganju, MD,†††
Peter C. Gerszten, MD,‡‡‡ Ziya L. Gokaslan, MD,§§§ Michael W. Groff, MD,¶¶¶
Norbert J. Liebsch, MD,||||| Ehud Mendel, MD,***** Scott H. Okuno, MD,††††
Shreyaskumar Patel, MD,‡‡‡‡ Laurence D. Rhines, MD,§§§§ Peter S. Rose, MD,***
Daniel M. Sciubba, MD,§§§§ Narayan Sundaresan, MD,¶¶¶¶ Katsuro Tomita, MD,|||||||
Peter P. Varga, MD,***** Luiz R. Vialle, MD,††††† Frank D. Vrionis, MD, MPH, PhD,‡‡‡‡‡
Yoshiya Yamada, MD,§§§§§ and Daryl R. Fourney, MD,¶¶¶¶¶

Study Design. Systematic review and modified Delphi technique.

Objective. To use an evidence-based medicine process using the best available literature and expert opinion consensus to develop a comprehensive classification system to diagnose neoplastic spinal instability.

Summary of Background Data. Spinal instability is poorly defined in the literature and presently there is a lack of guidelines available to aid in defining the degree of spinal instability in the setting of neoplastic spinal disease. The concept of spinal instability remains important in the clinical decision-making process for patients with spine tumors.

Methods. We have integrated the evidence provided by systematic reviews through a modified Delphi technique to generate a consensus of best evidence and expert opinion to develop a classification system to define neoplastic spinal instability.

Results. A comprehensive classification system based on patient symptoms and radiographic criteria of the spine was developed to aid in predicting spine stability of neoplastic lesions. The classification system includes global spinal location of the tumor, type and presence of pain, bone lesion quality, spinal alignment, extent of vertebral body collapse, and posterolateral spinal element involvement. Qualitative scores were assigned based on relative importance of particular factors gleaned from the literature and refined by expert consensus.

Conclusion. The Spine Instability Neoplastic Score is a comprehensive classification system with content validity that can guide clinicians in identifying when patients with neoplastic disease of the spine may benefit from surgical consultation. It can also aid surgeons in assessing the key components of spinal instability due to neoplasia and may become a prognostic tool for surgical decision-making when put in context with other key elements such as neurologic symptoms, extent of disease, prognosis, patient health factors, oncologic subtype, and radiosensitivity of the tumor.

Key words: spinal metastasis, instability, tumor, spine oncology. **Spine 2010;35:E1221–E1229**

From the *Combined Neurosurgery and Orthopaedic Spine Program, Department of Orthopaedics, University of British Columbia, Vancouver, BC; †Iowa Spine and Brain Institute, Waterloo, IA; ‡Neurosurgery Service, Memorial Sloan-Kettering Cancer Center, New York, NY; §Department of Neurological Surgery, University of Virginia Medical Center, Charlottesville, VA; ¶Department of Orthopaedics, University of California, San Francisco, CA; ||Department of Neurological Surgery, Thomas Jefferson University, Philadelphia, PA; **Toronto Western Hospital Spinal Program, Department of Surgery, University of Toronto, Toronto, ON, Canada; ††Department of Orthopaedics and Traumatology, Ospedale Maggiore, Ausl Bologna, Bologna, Italy; ‡‡Department of Neurological Surgery, University of California, San Francisco, CA; §§Huntsman Cancer Institute and Department of Neurosurgery, Clinical Neurosciences Center, University of Utah, Salt Lake City, UT; ¶¶Department of Orthopedics, University of Minnesota, Minneapolis, MN; |||Department of Orthopedic Oncology, Regina Elena Institute, Rome, Italy; *****Department of Orthopaedics, Mayo Clinic, Rochester, MN; †††Department of Neurosurgery, Northwestern University, Chicago, IL; ‡‡‡Department of Neurosurgery, University of Pittsburgh Medical Center, Pittsburgh, PA; §§§Department of Neurosurgery, Johns Hopkins University, Baltimore, MD; ¶¶¶Department of Neurosurgery, Beth Israel Deaconess Medical Center, Boston, MA; ||||Department of Radiation Oncology, MA General Hospital, Boston, MA; *****Department of Neurological Surgery, The Ohio State University, Columbus, OH; ††††Department of Oncology & Orthopedic Oncology, Mayo Clinic, Rochester, MN; ‡‡‡‡Departments of Medical Oncology and §§§§Neurosurgery, MD Anderson Cancer Center, University of Texas, Houston, TX; ¶¶¶¶Department of Neurological Surgery, Mount Sinai Hospital, New York, NY; |||||Department of Orthopaedic Surgery, Kanazawa University School of Medicine, Kanazawa, Japan;

*****National Center for Spinal Disorders, Budapest, Hungary; †††††Catholic University of Parana, Curitiba-Pr, Brazil; ‡‡‡‡‡H Lee Moffitt Cancer Center and Research Institute and Departments of Neurosurgery and Interdisciplinary Oncology, University of South Florida College of Medicine, Tampa, FL; §§§§§Department of Radiation Oncology, Memorial Sloan-Kettering Cancer Center, New York, NY; and ¶¶¶¶¶Division of Neurosurgery, University of Saskatchewan, Royal University Hospital, Saskatoon, SK, Canada.

Acknowledgment date: August 12, 2009. First revision date: October 29, 2009. Second revision date: December 3, 2009. Acceptance date: April 2, 2010.

The manuscript submitted does not contain information about medical device(s)/drug(s).

Corporate/Industry funds were received in support of this work. No benefits in any form have been or will be received from a commercial party related directly or indirectly to the subject of this manuscript.

Address correspondence and reprint requests to Charles G. Fisher, MD, MHSc, Department of Orthopaedics, University of British Columbia, Blusson Spinal Cord Centre, 818 W. 10th Avenue, 6th floor, Vancouver, BC, Canada V5Z 1M9; E-mail: charles.fisher@vch.ca

Metastatic disease of the spine remains a common problem and its incidence is increasing as detection methods improve and treatments for primary cancers allows patients with active disease to have a longer life expectancy.¹ Recent data has shown that patients with metastatic epidural cord compression who undergo surgical decompression and reconstruction followed by radiation have superior outcomes to those who undergo radiation alone in terms of preservation of neurologic function and pain relief.² There is further evidence that surgical decompression for spinal cord compression from metastatic disease before radiation therapy results in improved neurologic outcomes and fewer wound complications.^{2,3} Thus, it appears critical to develop treatment plans for patients with spinal metastasis via a multidisciplinary approach between medical oncologists, radiation oncologists, and spine surgeons so that proper treatment and timing of treatment can be employed.

For patients with spinal metastasis or primary neoplastic disease, neurologic status is only one factor that influences surgical decision-making. While all patients with the diagnosis of a primary spine tumor should receive surgical consultation, it is still not completely established as to when patients with metastatic disease of the spine should receive surgical consultation and intervention. Surgical treatment decisions are broadly based on spinal stability and patient-specific factors that include patient health, prognosis,⁴ and tumor histology. Because spinal instability is not well defined in the literature, there are no evidence-based guidelines currently available to aid in assessment of a particular patient's risk for spinal instability in the setting of neoplastic spinal disease. The concept of spinal instability, however, remains critical in the surgical decision-making process. Spinal instability as the result of a neoplastic process differs significantly from high-energy traumatic injuries in the pattern of bony and ligamentous involvement, potential for healing, neurologic manifestations, and bone quality, and therefore requires a specific and different set of criteria for stability assessment. Recently, systematic reviews of the cervical and thoracolumbar spine literature have been unable to definitively describe what constitutes neoplastic spinal instability.^{5,6} Thus, for the purposes of clinical decision-making and future research, the Spine Oncology Study Group (SOSG) defines spine instability as loss of spinal integrity as a result of a neoplastic process that is associated with movement-related pain, symptomatic or progressive deformity, and/or neural compromise under physiologic loads.

Because of the lack of guidelines, spine surgeons currently rely on clinical experience to determine whether instability is present in the setting of spinal neoplasia and surgery is indicated. Although demanding for the spine surgeon, the diagnosis of instability for the nonsurgeon may be extremely challenging, often leading to inappropriate referrals of patients without instability or undertreatment of patients with instability, risking pain, and/or neurologic deterioration. Development of a sim-

ple classification with easily assigned radiographic and patient factors would help to facilitate communication and appropriate referral between oncologists, radiologists, and orthopedic and/or neurosurgical spine surgeons to ensure that prompt and optimized treatment plans can be developed. Furthermore, the classification can lead to a more consistent therapeutic approach among spine surgeons and will aid in education and scientific study. The purpose of this study is to use an evidence-based medicine process incorporating the best available literature and expert opinion consensus to develop a comprehensive classification system for diagnosing neoplastic spinal instability.

■ Materials and Methods

Systematic Reviews

Before the start of this study, 2 systematic reviews⁵⁻⁷ of the current spine literature were performed by members of the SOSG to identify the best evidence for clinical, radiographic, and pathologic factors that relate to neoplastic spinal instability in the cervical and thoracolumbar spine. The first review sought to answer the question, "how is impending or overt instability of the cervical spine diagnosed in the setting of neoplastic involvement?" The second systematic review dealt with the problem of what defines instability or impending instability in patients with metastatic disease of the thoracolumbar spine. These systematic reviews, although inconclusive with regard to defining exact instability criteria, nonetheless served as the framework from which to guide an expert consensus on neoplastic spine instability.

Expert Opinion

The SOSG is an international group of 30 spine oncology experts and thought leaders from North America, Europe, South America, and Asia who meet biannually to discuss research, assess the best evidence for current practices, and formulate clinical trials to advance the field of spine oncology. Guyatt *et al*⁸ have highlighted that a key component to evidence-based medicine (especially when higher levels of evidence fall short) is to employ consensus expert opinion.

Delphi Technique

The Delphi method is typically a group communication among a panel of geographically dispersed experts. The technique allows the group to deal systematically with a complex problem or task (in this case the question of how to define neoplastic spinal instability).⁸⁻¹⁰ A modified Delphi process was used to collect and distill knowledge from the SOSG by means of a series of questionnaires interspersed with controlled opinion feedback for the production of suitable information for decision-making.¹⁰

The modified process involved 7 defined steps for review of the opinions.

1. An initial meeting of the SOSG was undertaken that included a round-table discussion, moderated by an appointed "chairperson." The criteria deemed important to clinical decision-making were identified. Twenty-four orthopedic and neurosurgical spine surgeons and oncologists with expertise in the area of spinal oncology were asked to list factors relevant to the definition of spinal instability in the oncology setting. The first round of criteria was then further organized, and the terminology

Table 1. Results of the Statistical Analysis of Round 1 and 2 of the Content Validity Surveys

Factors Associated With Instability	Left Skewness	Right Skewness	Comparison Between Rounds 1 and 2
Presence of pain at rest	X		
Character of pain (<i>i.e.</i> , changes with mobility)		X	
Sclerotic tumor	X		
Pain with percussion	X		Increased rating $P = 0.034$
Subluxation/translation		X (pointed)	
Occipitocervical location		X (pointed)	
Cervicothoracic junction location		X	
Complete pedicle involvement (bilateral)		X (pointed)	
Progression of deformity		X (pointed)	
Midcervical location	X		Decreased rating $P = 0.031$
Unilateral pedicle involvement		X	Decreased rating $P = 0.037$

ECOG/Karnofsky Performance Status assigns relative weight to the responses based on the pattern of their distribution. Left skewness indicates a pile-up of scores to the left of, or below, the mean; right skewness is a pile-up of scores to the right of, or above, the mean. Strong skewness shows a significantly pointed distribution. T-test comparisons of Round 1 and 2 responses were made to determine whether subsequent panel discussion swayed opinions on contributing factors.

employed was refined to be consistent with the evidence-based systematic reviews.

- A questionnaire was developed to assess the SOSG members' opinions on the relative weight of importance of the identified factors. The results were used to generate a 4-part survey addressing mechanical instability including clinical features (12 items), radiographic features (12 items), anatomic location (9 items), and other (open-ended response). All participants then ranked these factors from 0 to 100 (0 indicating nonrelevance and 100 indicating absolute importance).
- The open-ended responses were compiled and included in the final results. The results were divided based on scoring into 3 groups: highly relevant (>70); relevant; (40–70) less relevant (<40). These groupings were used for a consensus-based discussion to develop a working definition of oncologic spinal instability and a draft of a classification scheme. Further discussion occurred between SOSG members in interactive forum.
- A preliminary Spine Instability Neoplastic Score (SINS) was developed.
- A second-round questionnaire was developed and distributed *via* e-mail. Results were compared with the response obtained in the first round. Further feedback from SOSG members was used to refine the scoring system. First- and second-round results were compared, showing no statistically significant changes in the relative importance of any factors between rounds.
- The SINS was applied to a series of representative cases by a subgroup of SOSG surgeons to assess clarity and ease of use.
- Open-ended feedback was provided by SOSG members that led to consolidation of the SINS.

Statistical Analysis

Descriptive statistics for the rankings for the 40 factors associated with spinal instability were performed, including skewness and kurtosis measures. Skewness and kurtosis are measures indicating a departure from a normal distribution. Paired *t* tests were used to assess the differences between the ratings by physician at Round 1 and Round 2 for the instability factors.

Results

Twenty-four fellowship trained spine surgeons (of the 26 in the group) completed the original questionnaire. His-

tograms were developed to assess the distribution of answers, and the skewness (a pileup of scores to the left or right of the mean) and kurtosis (“pointedness” or “flatness” of the distribution) were assessed, and significant departures from the normal distribution were noted (Table 1).

All 24 physicians ranked the resulting 40 factors. Nine factors scored greater than 70 and 19 scored between 40 and 70. The highest ranked factors included subluxation/translation (86.67 ± 11.95), progression of deformity (86.52 ± 13.60), facet destruction bilaterally (78.75 ± 13.85), and character of neurologic changes (with motion) (77.71 ± 19.89). The anatomic areas of most concern were the occipitocervical junction (70.83 ± 16.33) and the cervicothoracic junction (72.29 ± 21.01).

Twenty surgeons subsequently completed the Round 2 questionnaire, and their answers were compared with those provided in Round 1 (but only for those 20 surgeons) to determine whether there were any significant changes of opinion that could be attributed to the group discussion. Responses were compared *via* paired *t* tests. The factors for which there was significant change at the $P < 0.05$ level are listed in Table 1.

After integrating information from the previous SOSG discussions and the 2 rounds of questionnaires, a preliminary scoring system was developed. Consolidation of the scoring system was accomplished after final

Table 2. SINS Component Score for Spine Location

Spine Location	Score
Junctional (Occiput-C2, C7-T2, T11-L1, L5-S1)	3
Mobile spine (C3-C6, L2-L4)	2
Semi-rigid (T3-T10)	1
Rigid (S2-S5)	0

Spine location is scored based on global variations in the spinal architecture. Junctional regions include occipitocervical (C0–C2), cervicothoracic (C7–T2), thoracolumbar (T11–L1), and lumbosacral (L5–S1) regions. Mobile segments include those not in the junctional regions and those that do not articulate with the rib cage. Semi-rigid segments are nonjunctional segments in the thoracic region that articulate with the rib cage. Rigid segments are parts of the nonjunctional sacral spine (S2–S4).

Table 3. SINS Component Score for Mechanical or Postural Pain

Pain Relief With Recumbence and/or Pain With Movement/Loading of the Spine	Score
Yes	3
No (occasional pain but not mechanical)	1
Pain-free lesion	0

Mechanical or postural pain is scored in this section. Relief with recumbency supports a structural or mechanical component.

application to a series of representative clinical cases. The SINS is made up of the following 6 components.

Spine Location

This component considers whether the location of the neoplasm is in a typically less stable location. Patients with neoplasms in “rigid” segments (nonjunctional sacral spine) receive a score of 0, whereas those with “semi-rigid” segments articulate with the rib cage from T3–T10 receive a score of 1. Patients with “mobile” segments (nonjunctional and not articulating with the rib cage or pelvis) receive a score of 2. These segments range from C3–C6 and L2–L4. Patients whose neoplasms are located in junctional regions of the spine including occipitocervical (C0–C2), cervicothoracic (C7–T2), thoracolumbar (T11–L1), or lumbosacral (L5–S1) regions were graded as a 3 (Table 2).

Mechanical Pain

This component considers whether patients have mechanical pain associated with the neoplasm. Patients with presence of pain without mechanical characteristics receive a score of 1. Patients who have pain with movement, upright posture, or loading of the spine (mechanical) and/or those for whom this pain is relieved with recumbence receive a score of 3 (Table 3).

Bone Lesion Quality

Bone lesion quality is considered among the components affecting spinal instability. Patients with blastic (sclerotic) lesions receive a score of 1 while those with lytic bone lesions receive a score of 2 (Table 4). Computed tomography (CT) scan is the best modality for defining this characteristic.

Spinal Alignment

Patients with *de novo* deformity in the sagittal or coronal plane can be assessed with serial radiographs or by comparing supine and upright radiographs. These patients received a score of 2. Subluxation or translation denotes the highest contribution to instability in this subsection

Table 4. SINS Component Score for Bone Lesion Quality

Bone Lesion Quality	Score
Lytic	2
Mixed lytic/blastic	1
Blastic	0

Table 5. SINS Component Score for Spinal Alignment

Radiographic Spinal Alignment	Score
Subluxation/translation present	4
De novo deformity (kyphosis/scoliosis)	2
Normal alignment	0

This category is meant to describe spinal alignment between motion segments that are affected by tumor. Scoring of *de novo* deformity such as kyphosis and/or scoliosis requires knowledge of prior imaging or may be assessed with upright compared with supine radiographs.

and throughout the entire cumulative score. Patients with subluxation or translation received a score of 4. Patients with normal alignment receive a score of 0 for this component (Table 5).

Vertebral Body Collapse

Anterior and middle column involvement by tumor is denoted by this component of the scoring system. Patients with no vertebral body involvement receive 0 points, those with greater than 50% vertebral body involvement with no collapse receive 1 point, those with less than 50% collapse receive 2 points, and those with greater than 50% collapse receive 3 points (Table 6).

Posterolateral Involvement of Spinal Elements

Patients with no tumor involvement of the posterior elements receive a score of 0, whereas those with unilateral posterior involvement receive a score of 1 and those with bilateral involvement of pedicles, facets, and/or costovertebral joints receives a score of 3 (Table 7).

The SINS is generated by tallying each score from the 6 individual components. The minimum score is 0 and maximum is 18. Scores of 0 to 6 denote “stability,” scores of 7 to 12 denote “indeterminate (possibly impending) instability,” and scores of 13 to 18 denote “instability.” Patients with SINS scores of 7 to 18 warrant surgical consultation.

The following cases illustrate application of the SINS.

Case 1. A 53-year-old woman with an 11-year history of breast cancer that has been well controlled with systemic regimens of chemotherapy had been independent and functioning without the need for narcotic medication. She sustained a pathologic T11 compression fracture 1.5 years ago that has been symptom free and resulted in vertebra plana and a functional thoracic deformity. She presented with new-onset severe thoracic back pain for 2 weeks and was found to have a new

Table 6. SINS Component Score for Vertebral Body Involvement

Vertebral Body Collapse	Score
>50% collapse	3
<50% collapse	2
No collapse with >50% body involved	1
None of the above	0

Presence and extent of vertebral body height collapse are used to assign a contribution of the score to the anterior and middle columns.

Table 7. SINS Component Score for Posterior Involvement

Posterolateral Involvement of Spinal Elements (Facet, Pedicle, or CV Joint Fracture or Replacement With Tumor)	Score
Bilateral	3
Unilateral	1
None of the above	0

The "posterolateral elements of the spine" component to the score allows contribution from the posterior elements including pedicles, facets, and CV joints. Bilateral involvement is scored as greater than double the contribution of unilateral involvement because of the destabilizing nature of its effects.

pathologic fracture of T10 (Figure 1). She had mechanical back pain that was relieved by lying down. She was neurologically intact on examination. Supine to upright radiographs demonstrated an increase in kyphosis of 20°.

SINS scoring for this patient was scored as follows: spine location—semirigid spine (T10) = 1; mechanical pain—presence of mechanical pain = 3; bone lesion quality—lytic = 2; radiographic spinal alignment—kyphosis = 2; vertebral body collapse—>50% = 3; posterolateral involvement of spinal elements—bilateral = 3. The final tally of component scores yielded 14 out of a possible 18. This condition is deemed as indeterminate instability but falls within the range of lesions that warrant surgical consultation for the oncologist and should be considered a possible surgical candidate depending on prognosis and other patient factors.

Case 2. A 65-year-old man with a 70-pack/yr history of smoking presents with severe upper cervical neck pain that was exacerbated by head rotation and relieved slightly by supine posture. He had greater occipital

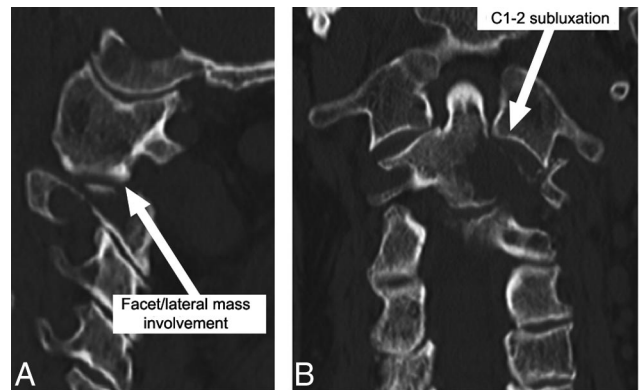


Figure 2. **A**, Sagittal computed tomography (CT) scan demonstrating lytic lesion of the left C2 lateral mass with pathologic fracture and C1–C2 subluxation. **B**, Coronal CT scan demonstrates extent of lytic lesion and subluxation of left C1–C2 articulation through the pathologic fracture.

parasthesiae but was otherwise neurologically intact. Staging images demonstrated multiple right upper lobe lung lesions consistent with lung cancer. Cervical spine imaging is shown in Figure 2.

SINS scoring for this patient would proceed as follows: spine location—junctional = 3; mechanical pain—presence of mechanical pain = 3; bone lesion quality—lytic = 2; radiographic spinal alignment—subluxation = 4; vertebral body collapse—>50% tumor involvement = 1; posterolateral involvement of spinal elements—unilateral = 1. The final tally of component scores yields 14 out of a possible 18. This score indicates that the patient is in an unstable situation.

Case 3. A 69-year-old man with a recent diagnosis of renal cell carcinoma presented with occasional back pain

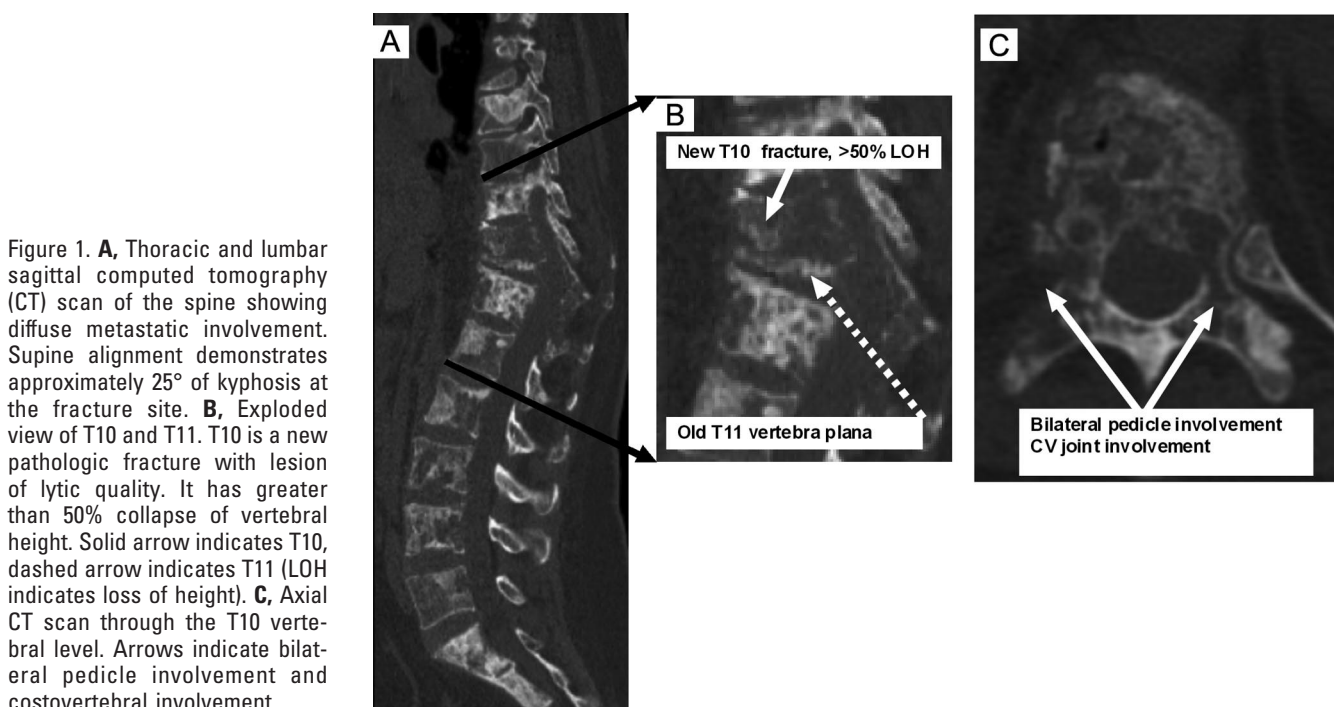


Figure 1. **A**, Thoracic and lumbar sagittal computed tomography (CT) scan of the spine showing diffuse metastatic involvement. Supine alignment demonstrates approximately 25° of kyphosis at the fracture site. **B**, Exploded view of T10 and T11. T10 is a new pathologic fracture with lesion of lytic quality. It has greater than 50% collapse of vertebral height. Solid arrow indicates T10, dashed arrow indicates T11 (LOH indicates loss of height). **C**, Axial CT scan through the T10 vertebral level. Arrows indicate bilateral pedicle involvement and costovertebral involvement.

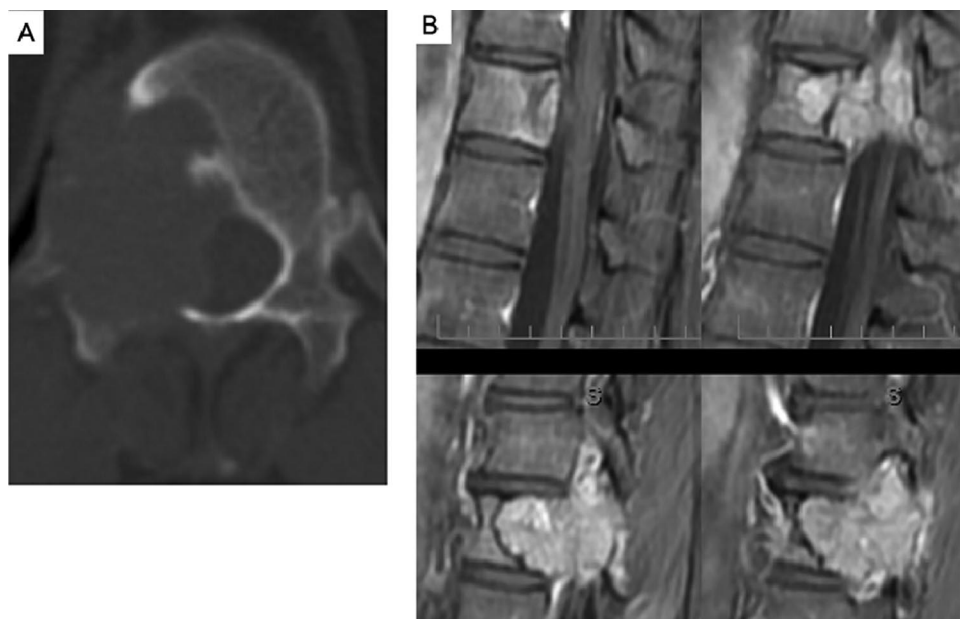

Figure 3. **A**, Axial CT scan demonstrating lytic lesion of T10 involving severe destruction of the right pedicle. **B**, Multiple sequential sagittal magnetic resonance images of the metastatic renal cell lesion in T10.

and right T10 radicular pain. His pain occurred at night while supine or during the day but did not particularly change with posture. His radiographic studies are shown in Figure 3.

SINS scoring for this patient would proceed as follows: spine location—semirigid spine (T10) = 1; mechanical pain—lack of mechanical pain, but presence of occasional nonspecific back pain = 1; bone lesion quality—lytic = 2; radiographic spinal alignment—normal = 0; vertebral body collapse/involvement—greater than 50% involvement, no collapse = 1; posterolateral involvement of spinal elements—unilateral = 1. The final tally of component scores yields 6 out of a possible 18, suggesting a stable lesion. However, it is important to note that, as with all metastatic spine tumor cases, surgical decision-making is not based on spinal stability alone. It has been shown that patients with solitary spinal metastasis from renal cell carcinoma who undergo surgery have a survival benefit.¹¹ In practice, this patient was worked up in anticipation for surgery but surgical intervention was not pursued because of a shared blood supply of the tumor with the artery of Adamkiwicz.

Discussion

The current paper describes the development of a Spine Instability Neoplastic Score, which seeks to provide objective criteria to evaluate the relative stability of metastatic spinal lesions. We must emphasize that stability is only one of many components used to determine management of the patient with a metastatic spine lesion and is perhaps the most difficult component to judge, especially for the nonspine surgeon.

White *et al*¹² defined spinal stability as the ability of the spine to maintain its degree of motion while simultaneously preventing pain, neurologic deficit, and abnormal angulation. Spinal instability created by neoplastic process appears to be different from that associated with

traumatic injuries. It is an ill-defined clinical entity based on symptoms, signs, and imaging. The SOSG defines spine instability as loss of spinal integrity as a result of a neoplastic process that is associated with movement-related pain, symptomatic or progressive deformity, and/or neural compromise under physiologic loads. Impending spinal instability is also an important factor that affects the clinical decision-making process in oncologic spinal disease. There has yet to be a consensus on comprehensive definitions of either set of terms, but the importance of this task is clear.

Neoplastic lesions rarely follow the anatomic patterns typical of traumatic ones and involve different biologic healing potential and patient factors. The role for surgery in the setting of neurologic deficit and spinal cord compression with metastatic disease is well established.^{2,3} However, in patients with metastatic spinal disease without neurologic deficit, it is important for oncologists (medical and radiation oncologists), radiologists, and spine surgeons to recognize which situations are unstable or may lead to spinal instability and neurologic injury. This will allow proper stabilization of patients with severe mechanical pain and will hopefully prevent painful collapse, neurologic consequences, and inappropriate treatment planning for patients with impending instability.

The key components of a spine oncology stability classification system include the ability to guide clinical decision-making, content validity, reproducibility, reliability, and acceptance among practitioners. Above all, a clinically applicable spine oncology stability classification system should be easy to use, should facilitate communication by providing a universal language among practitioners (*i.e.*, spine surgeons and oncologists), and should address comprehensive components of the problem (spine stability in the setting of neoplastic disease) to guide treatment. To this point, no single classification

system has been validated and proven to comprehensively address all or even most of the important factors involved in metastatic spine instability.

Previous studies in the spinal oncology literature have used instability criteria adopted from trauma situations or have failed to define the term instability entirely. In studies that do assign a predetermined definition of instability, the criteria are often derived from biomechanical studies¹³ or adapted from theoretical considerations without having been subject to rigorous methodologic process or validation.^{14,15} Other authors have used clinical and symptom-related criteria to define instability in their series of surgical treatment for metastatic spine disease.¹⁶⁻¹⁹ The “NOMS” (neurologic, oncologic, mechanical instability, systemic disease) criteria for decision-making have been used to guide clinicians in choosing between radiation and surgical treatment for metastatic spine tumors.¹⁶⁻²⁰ The “mechanical instability” component of the criteria relies solely on the assessment of a patient’s movement-related pain. Different types of motions and postures are characteristic of mechanical pain (and thus, as defined by NOMS, instability).¹⁶⁻²⁰ This classification system has not been validated and fails to consider other key components of instability such as radiographic parameters. In 2 recent systematic reviews of instability in the setting of neoplastic disease of the cervical and thoracolumbar spine, it was shown that there is a lack of level I evidence and scarce level II evidence to clearly define the issue.^{5,6} Nevertheless, several clinical and radiographic parameters were identified that likely relate to spinal instability with neoplastic disease.

Mechanical (activity-related) pain is a consistent feature of oncologic instability.¹⁶⁻²⁰ Axial spinal pain, which is a mechanical pain exacerbated by movement and relieved by recumbence, has been considered to be associated with a structural abnormality in the spinal column.¹⁶⁻²² Some authors report that a majority of patients presenting with spine metastases have mechanical neck or back pain.^{20,23} Other types of pain, such as that associated with periosteal stretching or nerve root/spinal cord compression, are not indicative of instability, although they may coexist with instability. These types of pain are clinically distinguishable by their distribution, severity, and quality and are influenced by factors that increase venous pressure (such as recumbency) or decrease edema (such as steroids). As described earlier, mechanical back or neck pain has been used as a component of the NOMS classification system to aid in guiding treatment for metastatic spinal disease.¹⁶⁻²⁰ However, pain is not the only feature that may be important in defining spinal instability in the setting of neoplastic disease.

Tumor size²⁴ and location also influence the stability of the spine. Involvement of more than 50% of the vertebral body could represent instability, as tumor size and cross-sectional area within the vertebral body have been shown to predict risk of pathologic fracture.^{13,25-28} The

“vertebral body collapse” element of the SINS allows the user to apply a score to a spectrum of tumor involvement for the vertebral body. Tumor involvement of greater than 50% confers a higher risk of subsequent vertebral collapse from pathologic fracture and receives a higher score depending on whether the collapse is less than or greater than 50%. Risk of burst fracture generally increases with tumor size; however, there is no clear threshold identified in the literature,^{13,29,30} so this assignment may be arbitrary. It is, nonetheless, a component of the score that was well accepted by the expert group.

Junctional regions of the spine are subject to transitional forces that place them at increased risk for instability leading to deformity.^{24,31} Unique biomechanical force differences as well as blood supply characteristics may put these regions at increased risk for neurologic deterioration,³¹ and, thus, tumors in these regions receive the highest relative score in the SINS “global spine location” component. The vertebrae supported by the rib cage (thoracic vertebrae) and the rigid segments of the sacrum are considered to have an added element of biomechanical protection. These segments are thus assigned the lowest score. The remainder of the “mobile” spine receives an intermediate score, if involved.

Lytic lesions inherently carry a greater risk of collapse⁷ because of a relative lack of mineralization; thus, they receive the highest score within the “lesion quality” component of the SINS. Assessment of bone lesions is best performed by CT scan. While plain radiographs may also be helpful, the sensitivity of CT for assessing bony characteristics is much greater.³² Magnetic resonance imaging alone is unable to define this characteristic as well as CT. General bone quality is also a very important factor to consider in assessing fracture and stability risk. There is strong biomechanical literature to suggest that the cross-sectional area of a defect combined with the bone mineral density is an excellent predictor of vertebral body failure and pathologic fracture risk.³³⁻³⁵ In those patients with metastatic lesions of the spine, low bone density is associated with greater fracture risk.^{36,37} Lesions may behave differently based on the surrounding bone quality of the entire spine and thus low bone mineral density should also be considered as strong risk factor for instability.

Radiographically, the presence of deformity or the possibility of progressive deformity has been taken by several authors to indicate instability.³⁸⁻⁴⁰ Deformity may occur progressively and may include a cumulative effect from multiple lesions (*e.g.*, the kyphotic deformity that often occurs from several multiple myeloma compression fractures). These deformities often can “settle out” and remain stable in a kyphotic or deformed posture without any further consequences because of compensation from normal spinal elements and hip and pelvic mobility. It should be noted that although static deformity may not cause direct neural compromise, it may impair individual patient function by the produc-

Table 8. Summary Table Including All Elements of the SINS

Element of SINS	Score
Location	
Junctional (occiput-C2, C7-T2, T11-L1, L5-S1)	3
Mobile spine (C3-C6, L2-L4)	2
Semi-rigid (T3-T10)	1
Rigid (S2-S5)	0
Pain relief with recumbency and/or pain with movement/loading of the spine	
Yes	3
No (occasional pain but not mechanical)	1
Pain free lesion	0
Bone lesion	
Lytic	2
Mixed (lytic/blastic)	1
Blastic	0
Radiographic spinal alignment	
Subluxation/translation present	4
De novo deformity (kyphosis/scoliosis)	2
Normal alignment	0
Vertebral body collapse	
>50% collapse	3
<50% collapse	2
No collapse with >50% body involved	1
None of the above	0
Posterolateral involvement of the spinal elements (facet, pedicle or CV joint fracture or replacement with tumor)	
Bilateral	3
Unilateral	1
None of the above	0

tion of positive sagittal imbalance, compensatory lumbar hyperextension resulting in foraminal stenosis, and secondary respiratory insufficiency due to volumetric decrease of the thoracic and abdominal cavities. At the most severe level of the spectrum, subluxation, or dislocation is classified as overt “translational instability” and receives the highest component score within the entire SINS.

The literature supports the consideration of the posterolateral vertebral structures including the pedicles, facet joints, and costovertebral joints as a separate entity and factor in the stability of neoplastic spinal lesions.^{2,5,41,42} SINS assigns a specific component score to the posterolateral elements of the spine. Greater than double the relative weight of scoring is assigned to bilateral over unilateral posterolateral complex involvement.

The comprehensive scoring system is presented in Table 8. Note that a minimum score of 2 and a maximum score of 18 can be assigned to each patient. It is also important to note that in the case of multiple spine lesions, stability scores are not summed. Each lesion or general region of neoplastic pathology should be considered in the work-up of spinal neoplastic disease, but it is suggested that scores be assigned separately. The SINS system does not account for a “global spinal score” and does not predict the nature of interaction within the spine that is affected by multiple neoplastic lesions.

Many studies focus on specific regions of the spine (e.g., cervical *vs.* thoracolumbar) and thus these results

are not necessarily generalizable to all regions of the spine. Application of the literature to develop the scoring system has been challenging in that one of the goals has been to develop a system that provides application to lesions throughout the entire spinal column. Expert opinion and consensus generation has been invaluable in reviewing and refining the most important factors that can be used to unify the “language of instability” for neoplastic spinal disease. As a result, 6 subcategories were addressed and scored. The summed scores generate a relative stability score that can be used to guide treatment and to alert the oncologist or other physicians as to when they ought to consider surgical consultation and when the spine surgeon ought to consider surgical treatment. It must be emphasized that the SINS is meant to be only 1 component of the evaluation process when considering spine surgical referral or planning. If a patient has neurologic deficit or high-grade spinal cord compression without deficit, surgery is certainly indicated regardless of the SINS score.

It should be noted that modifying factors that likely contribute to spinal instability that are not accounted for by this scoring system must still be considered. Multi-level (contiguous) spinal disease may be an important factor but has been difficult to quantify and is not fully understood. The role of noncontiguous lesions is also not fully established. Previous laminectomies or other surgical procedures and previous radiation therapy (including radiosurgery) may also influence the fracture risk. Similarly, the extent of diffuse bony involvement of metastatic disease and likely poor bone quality as in the patient illustrated by case 1 should play into clinical decision-making. Patient body weight and activity level may also influence spinal loading and impending instability. Prior surgery, especially involving laminectomy, should also be noted and considered in the assessment of spinal stability in this setting. All of the additional factors should be considered qualifiers and dictate special consideration when assessing global spinal stability in the setting of neoplastic disease.

■ Conclusion

The SOSG derived a comprehensive classification system to aid in defining neoplastic spinal instability that includes the following factors: global spinal location of tumor, pain, bone lesion quality, spinal alignment, vertebral body collapse, and posterior involvement. After further validation and reliability testing, the SINS should be useful to both spine surgeons and other clinicians for the purposes of guiding patient care and future research. Future study and flexibility in the system will probably also be important when it comes to guiding treatment. As interventions become less invasive, the timing and threshold for intervention may also change. Most importantly, we must emphasize that in making surgical treatment decisions, stability is only 1 component of the process. Patient general health, tumor histology,

prognosis, neurology, and patient choice must also be considered.

■ Key Points

- Spinal instability is a key component in the treatment decision-making for spinal oncology patients. Other key components are: patient general health, tumor histology, prognosis, neurology, and patient choice.
- The Spine Instability Neoplastic Score (SINS) uses a comprehensive set of factors including: global spinal location of tumor, pain, bone lesion quality, spinal alignment, vertebral body collapse and posterior involvement, to aid in assessment of instability.
- SINS will aid radiation and medical oncologists as well as primary care physicians with respect to timing of referral to spine surgeons for evaluation.
- SINS will aid spine surgeons and oncologists in developing treatment algorithms for patients with primary and metastatic spine tumors.

References

1. American Cancer Society. Cancer Facts and Figures. American Cancer Society; 2007.
2. Patchell RA, Tibbs PA, Regine WF, et al. Direct decompressive surgical resection in the treatment of spinal cord compression caused by metastatic cancer: a randomised trial. *Lancet* 2005;366:643–8.
3. Ghogawala Z, Mansfield FL, Borges LF. Spinal radiation before surgical decompression adversely affects outcomes of surgery for symptomatic metastatic spinal cord compression. *Spine* 2001;26:818–24.
4. Tokuhashi Y, Matsuzaki H, Oda H, et al. A revised scoring system for preoperative evaluation of metastatic spine tumor prognosis. *Spine* 2005;30:2186–91.
5. Fehlings MD, Furlan J, Bilsky M, et al. Defining oncologic instability of the cervical spine—can the available evidence guide clinical practice? *Spine* In press.
6. Fisher CW, Burch M, Buckley J, et al. Instability and impending instability of the thoracolumbar spine in patients with spinal metastases: a systematic review. *Spine* In press.
7. Mirels H. Metastatic disease in long bones: a proposed scoring system for diagnosing impending pathologic fractures. 1989. *Clin Orthop Relat Res* 2003;415:54–13.
8. Guyatt G, Vist G, Falck-Ytter Y, et al. An emerging consensus on grading recommendations? *ACP J Club* 2006;144:A8–9.
9. Hsu CS. The Delphi technique: making sense of consensus. *Pract Assess Res Eval* 2007;12:1–8.
10. Linstone FT. *The Delphi Method: Techniques and Applications*. London, United Kingdom: Addison-Wesley; 1975.
11. Jung ST, Ghert MA, Harrelson JM, et al. Treatment of osseous metastases in patients with renal cell carcinoma. *Clin Orthop Relat Res* 2003;409:223–31.
12. White AA, Southwick WO, Panjabi MM. Clinical instability in the lower cervical spine a review of past and current concepts. *Spine* 1976;1:15–27.
13. Taneichi H, Kaneda K, Takeda N, et al. Risk factors and probability of vertebral body collapse in metastases of the thoracic and lumbar spine. *Spine* 1997;22:239–45.
14. Kostuik JP, Errico TJ, Gleason TF, et al. Spinal stabilization of vertebral column tumors. *Spine* 1988;13:250–6.
15. Cybulski GR. Methods of surgical stabilization for metastatic disease of the spine. *Neurosurgery* 1989;25:240–52.
16. Bilsky M, Smith M. Surgical approach to epidural spinal cord compression. *Hematol Oncol Clin North Am* 2006;20:1307–17.
17. Bilsky MH, Boakye M, Collignon F, et al. Operative management of metastatic and malignant primary subaxial cervical tumors. *J Neurosurg Spine* 2005;2:256–64.
18. Bilsky MH, Boland P, Lis E, et al. Single-stage posterolateral transpedicle approach for spondylectomy, epidural decompression, and circumferential fusion of spinal metastases. *Spine* 2000;25:2240–9; discussion 250.
19. Placantonakis DG, Laufer I, Wang JC, et al. Posterior stabilization strategies following resection of cervicothoracic junction tumors: review of 90 consecutive cases. *J Neurosurg Spine* 2008;9:111–9.
20. Bilsky MH, Shannon FJ, Sheppard S, et al. Diagnosis and management of a metastatic tumor in the atlantoaxial spine. *Spine* 2002;27:1062–9.
21. Fournier DR, York JE, Cohen ZR, et al. Management of atlantoaxial metastases with posterior occipitocervical stabilization. *J Neurosurg* 2003;98:165–70.
22. Jackson RJ, Gokaslan ZL. Occipitocervicothoracic fixation for spinal instability in patients with neoplastic processes. *J Neurosurg* 1999;91:81–9.
23. Sundaresan N, Galicich JH, Lane JM, et al. Treatment of odontoid fractures in cancer patients. *J Neurosurg* 1981;54:187–92.
24. Mazel CM, Hoffmann EM, Antonietti PM, et al. Posterior cervicothoracic instrumentation in spine tumors. *Spine* 2004;29:1246–53.
25. Ebihara H, Ito M, Abumi K, et al. A biomechanical analysis of metastatic vertebral collapse of the thoracic spine: a sheep model study. *Spine* 2004;29:994–9.
26. McBroom RJ, Hayes WC, Edwards WT, et al. Prediction of vertebral body compressive fracture using quantitative computed tomography. *J Bone Joint Surg Am* 1985;67:1206–14.
27. Whyne CM, Hu SS, Lotz JC. Biomechanically derived guideline equations for burst fracture risk prediction in the metastatically involved spine. *J Spinal Disord Tech* 2003;16:180–5.
28. Whyne CM, Hu SS, Lotz JC. Burst fracture in the metastatically involved spine: development, validation, and parametric analysis of a three-dimensional poroelastic finite-element model. *Spine* 2003;28:652–60.
29. Tschirhart CE, Finkelstein JA, Whyne CM. Metastatic burst fracture risk assessment based on complex loading of the thoracic spine. *Ann Biomed Eng* 2006;34:494–505.
30. Tschirhart CE, Nagpurkar A, Whyne CM. Effects of tumor location, shape and surface serration on burst fracture risk in the metastatic spine. *J Biomech* 2004;37:653–60.
31. An HS, Vaccaro A, Cotler JM, et al. Spinal disorders at the cervicothoracic junction. *Spine* 1994;19:2557–64.
32. White AP, Kwon BK, Lindskog DM, et al. Metastatic disease of the spine. *J Am Acad Orthop Surg* 2006;14:587–98.
33. Dimar JR II, Voor MJ, Zhang YM, et al. A human cadaver model for determination of pathologic fracture threshold resulting from tumorous destruction of the vertebral body. *Spine* 1998;23:1209–14.
34. Windhagen H, Hipp JA, Hayes WC. Postfracture instability of vertebrae with simulated defects can be predicted from computed tomography data. *Spine* 2000;25:1775–81.
35. Windhagen HJ, Hipp JA, Silva MJ, et al. Predicting failure of thoracic vertebrae with simulated and actual metastatic defects. *Clin Orthop Relat Res* 1997;344:313–9.
36. Tschirhart CE, Finkelstein JA, Whyne CM. Biomechanics of vertebral level, geometry, and transcortical tumors in the metastatic spine. *J Biomech* 2007;40:46–54.
37. Whyne CM, Hu SS, Klisch S, et al. Effect of the pedicle and posterior arch on vertebral body strength predictions in finite element modeling. *Spine* 1998;23:899–907.
38. Asdourian PL, Mardjetko S, Rauschnig W, et al. An evaluation of spinal deformity in metastatic breast cancer. *J Spinal Disord* 1990;3:119–34.
39. Fehlings MG, Cooper PR, Errico TJ. Posterior plates in the management of cervical instability: long-term results in 44 patients. *J Neurosurg* 1994;81:341–9.
40. Tomita K, Kawahara N, Kobayashi T, et al. Surgical strategy for spinal metastases. *Spine* 2001;26:298–306.
41. Schunemann HJ, Jaeschke R, Cook DJ, et al. An official ATS statement: grading the quality of evidence and strength of recommendations in ATS guidelines and recommendations. *Am J Respir Crit Care Med* 2006;174:605–14.
42. Sundaresan N, Sachdev VP, Holland JF, et al. Surgical treatment of spinal cord compression from epidural metastasis. *J Clin Oncol* 1995;13:2330–5.