

Fungal infections 1



Fungal infections in HIV/AIDS

Andrew H Limper, Antoine Adenis, Thuy Le, Thomas S Harrison

Fungi are major contributors to the opportunistic infections that affect patients with HIV/AIDS. Systemic infections are mainly with *Pneumocystis jirovecii* (pneumocystosis), *Cryptococcus neoformans* (cryptococcosis), *Histoplasma capsulatum* (histoplasmosis), and *Talaromyces (Penicillium) marneffei* (talaromycosis). The incidence of systemic fungal infections has decreased in people with HIV in high-income countries because of the widespread availability of antiretroviral drugs and early testing for HIV. However, in many areas with high HIV prevalence, patients present to care with advanced HIV infection and with a low CD4 cell count or re-present with persistent low CD4 cell counts because of poor adherence, resistance to antiretroviral drugs, or both. Affordable, rapid point-of-care diagnostic tests (as have been developed for cryptococcosis) are urgently needed for pneumocystosis, talaromycosis, and histoplasmosis. Additionally, antifungal drugs, including amphotericin B, liposomal amphotericin B, and flucytosine, need to be much more widely available. Such measures, together with continued international efforts in education and training in the management of fungal disease, have the potential to improve patient outcomes substantially.

Introduction

Fungi contribute greatly to opportunistic infections in patients with late-stage HIV infection. *Pneumocystis jirovecii* is the most common cause of respiratory infection and *Cryptococcus neoformans* the most common cause of CNS infection in patients with AIDS across large parts of the world. *Histoplasma capsulatum* (especially common in parts of the Americas) and *Talaromyces* (formerly *Penicillium*) *marneffei* (endemic in south and southeast Asia) are thermally dimorphic fungi that cause disseminated infections.

In this Series paper, we review the epidemiology and progress in diagnosis and therapy for these four major systemic fungal pathogens in patients with HIV/AIDS. We cite the most relevant recent papers, but additional supplementary references are available online, organised by section (appendix).

Although we focus on these major infections, other fungi are also important in patients with HIV/AIDS. *Coccidioides* spp especially affect patients with AIDS in the Americas and *Emmonsia* sp in South Africa.^{1,2} *Candida* spp commonly cause mucosal, oral, vaginal, and oesophageal infections in patients with stage 3 and 4 HIV disease, and fungal skin and nail infections are major causes of morbidity in HIV-infected individuals. However, mucosal candida infections usually readily respond to azole antifungal treatment and immune reconstitution with antiretroviral therapy (ART). In the era of ART, recurrent azole-resistant *Candida* spp infections are rare.

With widespread availability of ART and earlier testing and treatment for HIV, the incidence of systemic fungal infections has decreased in people living with HIV in high-income countries, although room for improvement remains.³ By contrast, in many regions with high HIV prevalence, particularly sub-Saharan Africa, there is little evidence for a substantial decrease in cases.⁴ Many patients present with advanced HIV and with a low CD4 cell

count.⁵ Additionally, enrolment data from cryptococcal meningitis trials show that, although the total number of cases was stable over time, half or more of patients with cryptococcal meningitis had taken ART⁶ but had persistent low CD4 cell counts due to problems of retention in care and or ART resistance. Thus, further efforts to address the problem of fungal infections through rapid point-of-care diagnostics for these major fungal pathogens and global access to antifungal drugs are needed as an integral part of an effective response to the HIV pandemic.

Pneumocystis pneumonia

Epidemiology

Pneumocystis pneumonia has emerged as a major cause of infection in those with HIV/AIDS, and is estimated to

Lancet Infect Dis 2017

Published Online

July 31, 2017

[http://dx.doi.org/10.1016/S1473-3099\(17\)30303-1](http://dx.doi.org/10.1016/S1473-3099(17)30303-1)

[http://dx.doi.org/10.1016/S1473-3099\(17\)30304-3](http://dx.doi.org/10.1016/S1473-3099(17)30304-3),

[http://dx.doi.org/10.1016/S1473-3099\(17\)30309-2](http://dx.doi.org/10.1016/S1473-3099(17)30309-2),

[http://dx.doi.org/10.1016/S1473-3099\(17\)30306-7](http://dx.doi.org/10.1016/S1473-3099(17)30306-7),

[http://dx.doi.org/10.1016/S1473-3099\(17\)30316-X](http://dx.doi.org/10.1016/S1473-3099(17)30316-X),

[http://dx.doi.org/10.1016/S1473-3099\(17\)30442-5](http://dx.doi.org/10.1016/S1473-3099(17)30442-5),

[http://dx.doi.org/10.1016/S1473-3099\(17\)30443-7](http://dx.doi.org/10.1016/S1473-3099(17)30443-7), and

[http://dx.doi.org/10.1016/S1473-3099\(17\)30308-0](http://dx.doi.org/10.1016/S1473-3099(17)30308-0)

See Online/Comment

[http://dx.doi.org/10.1016/S1473-3099\(17\)30319-5](http://dx.doi.org/10.1016/S1473-3099(17)30319-5)

This is the first in a Series of

eight papers about fungal

infections

Mayo Clinic College of Medicine,

Rochester, MN, USA

(A H Limper MD); Inserm

CIC 1424, Centre

d'Investigation Clinique Antilles

Guayane, Centre Hospitalier de

Key messages

- Incidence of systemic fungal infections in patients with HIV/AIDS has decreased in many resource-rich areas after the introduction of antiretroviral therapy and earlier diagnosis and treatment of infection
- In many resource-limited settings incidence is not yet decreasing due to continued late diagnosis and challenges with retention in HIV care
- New PCR-based assays can distinguish colonisation from infection with pneumocystis
- Measurement of cerebrospinal fluid pressure is essential in cryptococcal meningitis, and management of raised cerebrospinal fluid pressure through careful therapeutic lumbar punctures reduces mortality
- In large parts of the world, HIV-related histoplasmosis is often neglected, undiagnosed, or misdiagnosed as tuberculosis, because of poor access to current diagnostics
- The intersection with HIV has transformed *Talaromyces marneffei* from a rare human pathogen to a major cause of HIV-associated death in southeast Asia; amphotericin B was shown to be superior to itraconazole as initial treatment in a large randomised trial
- Novel, affordable, point-of-care diagnostics for pneumocystis, histoplasmosis, and talaromycosis, and wider access to effective antifungals are urgently needed to reduce the burden of HIV-associated fungal infections in resource-limited settings

Cayenne, Cayenne, France (A Adenis MD); Equipe EA 3593, Ecosystèmes Amazoniens et Pathologie Tropicale, Université de Guyane, Cayenne, France (A Adenis); Oxford University Clinical Research Unit, Wellcome Trust Major Overseas Programme, Ho Chi Minh City, Vietnam (T Le MD); Hawaii Centre for AIDS, University of Hawaii at Manoa, Honolulu, HI, USA (T Le); and Institute of Infection and Immunity, St George's, University of London, London, UK (Prof T S Harrison FRCP)

Correspondence to: Prof Thomas S Harrison, Institute of Infection and Immunity, St George's, University of London, London SW17 0RE, UK tharriso@sgul.ac.uk

See Online for appendix

cause more than 400 000 cases worldwide every year.⁷ Many of these patients are undiagnosed or diagnosed late, particularly in resource-limited settings. The mortality of pneumocystis pneumonia ranges from 10% to 30% or higher, depending on the patient population, comorbidities, and whether the diagnosis is made early.^{8,9} Although the incidence has been reduced by implementation of ART, pneumocystis pneumonia continues to be a problem in patients who are unaware that they are infected with HIV and in those with ART failure or who stop taking ART.¹⁰

Pathogenesis

Pneumocystis spp are members of the Ascomycetous fungi. Each mammalian species can harbour at least one unique species of the *Pneumocystis* genus¹¹—eg, *P jirovecii* infecting human beings and *Pneumocystis carinii* infecting rats. Serological and epidemiological data indicate that

most people are exposed and transiently infected with *P jirovecii* early in life.¹² With healthy immune responses, this early infection is effectively cleared. However, during periods of immune suppression such as in patients with HIV who have CD4 counts lower than 200 cells per μL , the organism proliferates, leading to life-threatening pneumonia. CD4 immunity is essential for long-term control and memory responses to this fungus; contributing immunity is provided by innate immune responses, CD8 cells, and B-lymphocytes. In the absence of effective CD4-based immunity, innate inflammatory responses promote the accumulation of inflammatory cells, including neutrophils and CD8 lymphocytes, which strongly contribute to lung injury. Appreciation of this innate immune response has led to the use of adjunctive anti-inflammatory corticosteroids in moderate-to-severe pneumocystis pneumonia.¹³ Evidence suggests that infection can be acquired from other infected individuals. Therefore, whenever feasible, immunosuppressed patients should not be directly exposed to individuals with active pneumocystis pneumonia.^{14,15}

Diagnosis

Most patients with pneumocystis pneumonia present with cough and progressive dyspnoea (initially on exertion) and pulmonary infiltrates on chest radiograph or lung imaging (figure 1A). Definitive diagnosis relies on identification of *P jirovecii* organisms in respiratory secretions or bronchoalveolar lavage samples (figure 1B). Experienced observers can identify the organisms using Wright-Giemsa stained smears. However, tinctorial methods including methenamine silver, Papanicolaou, cresyl echt violet, and Calcofluor white staining assists in rapid identification of organisms.¹⁶ Fluorescence staining with monoclonal antibodies further increases sensitivity to approximately 95% when applied to bronchoalveolar lavage samples.⁹

Over the past decade, many laboratories have switched to identification using PCR. Nested PCR has been useful to identify colonisation as well as clinical infection, whereas, single-copy real-time PCR assays have been devised to rapidly identify patients with clinical infection, rather than colonisation.^{17,18} In expensive point-of-care diagnostic strategies, which are technically less demanding, are needed for regions with limited resources.⁷ Work is ongoing to develop relevant pneumocystis antigen-detection systems and thermocycler independent amplification strategies that can be used in such settings.

β -D-glucan assays in the serum can be useful as a screening tool and adjunct to diagnosis because they have good sensitivity in patients with HIV and pneumocystis pneumonia. Although β -D-glucan testing does cross react with the glucans released from other fungi, high levels of β -D-glucan (>100 pg/mL) in patients with HIV in the appropriate clinical setting does provide evidence to support starting therapy.¹⁹

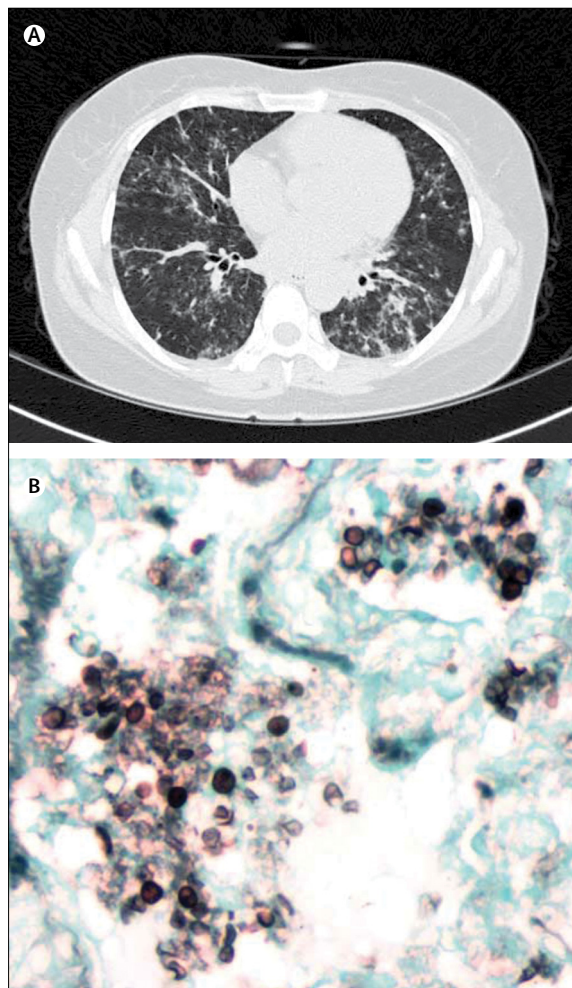


Figure 1: Features of *Pneumocystis jirovecii* pneumonia in patients with HIV. CT image of a 41 year old woman presenting with cough and dyspnoea (A). Imaging shows mixed alveolar and interstitial infiltrates, which were diagnosed as being due to *Pneumocystis jirovecii* pneumonia on bronchoalveolar lavage. Methenamine silver staining demonstrates typical pneumocystis organisms clustered in alveolar exudates (B).

Vast regions of the world including sub-Saharan Africa, Asia, and South America do not have ready access to laboratory facilities equipped for the diagnosis of pneumocystis pneumonia, rendering the true burden and impact of this infection under-recognised. For instance, when modern diagnostic methods were applied, unsuspected pneumocystis infection was found to be the cause of up to 7% of all severe pneumonia in children younger than 5 years in a hospital in southern Mozambique.²⁰ In regions with few laboratory facilities, the diagnosis of pneumocystis is often made on clinical grounds. Although such an approach is pragmatic, it lacks specificity, which is necessary to rapidly focus the appropriate antibiotic therapy towards pneumocystis when it is present.

Treatment

The mainstay of therapy is intravenous co-trimoxazole (sulfamethoxazole-trimethoprim) with the trimethoprim dosed at 15–20 mg/kg per day and sulfamethoxazole at 75–100 mg/kg per day. This is given in four equally divided doses for 21 days. For patients with milder disease, and once the disease is under control, therapy can be safely switched from intravenous to oral administration. It is useful to monitor therapeutic trough levels to avoid toxicity and ensure benefit, although this is infrequently done.¹³ Often, clinical improvement is not noted for up to 1 week. Patients who cannot tolerate co-trimoxazole are usually treated with the combination of primaquine and clindamycin or pentamidine. Atovaquone is generally reserved for those with milder disease.¹³ Efavirenz significantly reduces atovaquone concentrations. Only co-trimoxazole is present on the WHO Model List of Essential Medicines for pneumocystis pneumonia, with the alternative drugs appearing on the complementary list and for other indications.

Adjunctive corticosteroid therapy is given to patients with moderate to severe pneumocystis pneumonia, as defined by a room air PaO₂ lower than 70 mm Hg or alveolar–arterial oxygen gradient higher than 35 mm Hg. For these individuals, prednisone is provided at 40 mg twice a day on days 1–5, 40 mg once a day on days 6–10, and then 20 mg once a day up to day 21.²¹ In children younger than 13 years, prednisone can be given at 1 mg/kg twice a day on days 1–5, 0.5 mg/kg twice a day on days 6–10, and finally 0.5 mg/kg once a day on days 11–21.²²

Prevention

Appropriate pneumocystis prophylaxis is essential to prevent the often-lethal infection. Patients who have CD4 counts lower than 200 cells per μ L or a history of oropharyngeal candidiasis should receive prophylaxis with one double-strength co-trimoxazole tablet three times a week or one single-strength co-trimoxazole tablet once a day.²³ Co-trimoxazole in low-income and middle-income countries has additional benefits by reducing early

mortality from malaria, reducing anaemia, and improving growth in children.²⁴ Alternatives for patients who cannot tolerate co-trimoxazole include dapsone, atovaquone, or dapsone with pyrimethamine and leucovorin.¹³ Dapsone should be used cautiously in individuals with glucose-6-phosphate dehydrogenase deficiency.¹³ Generally, prophylaxis can be discontinued when CD4 counts are consistently higher than 200 cells per μ L for longer than 3 months. An effective pneumocystis vaccine is not yet available, but pre-clinical primate studies support the potential efficacy of such an approach for patients with HIV.²⁵

Cryptococcosis

Epidemiology

Latest estimates suggest that HIV-associated cryptococcal meningitis accounts for 150 000–200 000 deaths per year. These deaths occur mostly in sub-Saharan Africa where the associated mortality remains at around 70% at 3 months. Most HIV-associated infections are caused by *C neoformans*, although in Botswana, up to 30% of infections are with *Cryptococcus gattii*. Patients with cryptococcal meningitis present with headache and fever, with a median duration of 2 weeks between symptom onset and first presentation.²⁶ Many patients develop nausea, vomiting, diplopia due to cranial nerve VI palsies, and reduced visual acuity related to raised cerebrospinal fluid pressure. If untreated, symptoms progress to abnormal mental status, reduced conscious level, seizures, and finally coma.

Diagnosis

Traditionally, diagnosis has relied on lumbar puncture. A cerebrospinal fluid India ink preparation is positive in 70–90% of patients with HIV-associated infections,²⁶ and the remainder of patients can be reliably diagnosed by cryptococcal antigen (CrAg) detection or culture. However, headache is non-specific and lumbar puncture is frequently delayed, especially in resource-limited settings, until such time as the prognosis is poor. Development of a point-of-care lateral flow test for detection of CrAg is a major advance.²⁷ Antigen is present in blood (serum, plasma, or whole-blood finger-prick sample) before the development of symptoms and the test is highly specific and more sensitive than previous latex agglutination assays. The test enables earlier diagnosis, even in primary care settings, and screening of patients in hospitals in high-prevalence areas. It also makes feasible screening and pre-emptive therapy as a strategy to prevent the development of meningitis after HIV diagnosis and before starting ART in those with low CD4 cell counts.²⁸

Antifungal therapy

The gold-standard antifungal therapy for cryptococcal meningitis is the combination of amphotericin B deoxycholate (D-AmB; 0.7–1.0 mg/kg per day) and

For the WHO Model Lists of Essential Medicines see <http://www.who.int/medicines/publications/essentialmedicines/en>

flucytosine (100 mg/kg per day in four divided doses) for the initial 2 weeks, followed by fluconazole (400–800 mg per day for 8 weeks, and 200 mg per day thereafter) for a minimum of 1 year and until immune reconstitution.^{29–31} Addition of flucytosine was associated with a 40% reduction in mortality compared with D-AmB alone.³² Pre-hydration with normal saline and pre-emptive replacement of potassium and magnesium is recommended to mitigate the toxicities of D-AmB,³⁰ but anaemia remains an important problem where transfusion capacity is limited. Liposomal amphotericin B (L-AmB) at 3–6 mg/kg per day is as effective as and better tolerated than D-AmB.³³ Studies are ongoing to assess whether L-AmB could be used in intermittent high doses, as for leishmaniasis, to provide a convenient and cost-effective induction treatment. With care taken to adjust doses in case of renal impairment, flucytosine is generally well tolerated in this patient population for 2 weeks.³⁴

Complications

Raised cerebrospinal fluid pressure caused by a blockage of cerebrospinal fluid reabsorption at the level of the arachnoid granulations is common in cryptococcal meningitis, with about a quarter of patients having a pressure greater than 35 cm H₂O.³⁵ If untreated, high pressure is associated with increased mortality,³⁵ but increasing evidence points to the effectiveness of careful therapeutic lumbar punctures.^{26,36,37} Only the most severely ill patients might require a temporary lumbar drain or ventricular shunt.^{38,39} High cerebrospinal fluid pressure can develop in the second and third weeks of treatment, despite effective sterilisation of the cerebrospinal fluid, meaning that a lumbar puncture should be repeated if symptoms persist or recur.

Recommendations are to start ART between 4 weeks and 6 weeks after starting antifungal therapy. This schedule is based on the findings of studies suggesting 3 days or 8 days is too soon^{40,41} and 6 weeks or later is probably unnecessarily late. Given that in many centres, half of cryptococcal meningitis cases now occur in ART-experienced patients, it is prudent to only switch to second-line ART in those thought to have ART resistance or re-start ART in those who have discontinued taking ART, after 4 weeks of antifungal therapy. Cryptococcal meningitis in patients with ART failure needs to be distinguished from patients with unmasking cryptococcal immune reconstitution inflammatory syndrome (IRIS)⁴² (in which presentation is precipitated by starting ART) and in whom ART should be continued. Frequent clinical review is needed given some overlapping toxic effects of antifungal and antiretroviral drugs.

Paradoxical cryptococcal IRIS occurs in 15–20% of patients who are treated for cryptococcal meningitis. These patients respond to treatment but later have a recurrence of symptoms, at a median of around 1 month after starting ART.⁴³ In patients re-presenting with a recurrence of symptoms, cerebrospinal fluid pressure

should be measured and managed, because raised pressure is common in cryptococcal IRIS. Re-introduction of induction antifungal therapy can be considered while cerebrospinal fluid culture results are pending and while alternative diagnoses are actively pursued. If cryptococcal IRIS remains the likely diagnosis, and the patient is deteriorating, then short courses of corticosteroids have been used successfully. By contrast, corticosteroids given with initial antifungal therapy are harmful.⁶ Although cryptococcal IRIS can be life-threatening, related mortality should be lower than recorded in earlier series because of increased awareness and more prudent timing of ART.

Prevention

The lateral flow CrAg test has made feasible a screen and pre-emptive fluconazole treatment strategy to prevent the development of meningitis in patients with low CD4 cell counts. 3–8% of individuals with a CD4 count lower than 100 cells per μ L usually test positive on CrAg screening of blood samples.⁴⁴ In a retrospective study from Cape Town, patients testing positive for CrAg had a high (28%) chance, without treatment, of developing meningitis in the first year of ART, whereas, of those who tested negative and were started promptly on ART, none went on to develop meningitis.²⁸ Subsequent modelling suggested such a strategy could be highly cost-effective,^{44,45} and screening has been endorsed in WHO guidelines³⁰ and introduced in South Africa and elsewhere. Prospective studies are underway, with one report demonstrating that such screening and pre-emptive fluconazole, combined with ART adherence support, led to a 28% reduction in mortality in patients with late-stage HIV in the first year of ART.⁴⁶ However, further work is needed to optimise the treatment of CrAg-positive patients. Despite the success of fluconazole therapy, these patients still have higher mortality compared with those who are CrAg negative,^{46,47} and of some concern there have been reports of decreased susceptibility to fluconazole in some areas.⁴⁸ Some patients, even though asymptomatic or minimally symptomatic, have evidence of meningitis if they agree to a lumbar puncture, and this risk is related to blood antigen titre.⁴⁷ Studies are planned to ascertain if those with a high antigen titre in blood would benefit from more aggressive antifungal therapy.

Histoplasmosis

Epidemiology

Histoplasmosis is caused by *Histoplasma capsulatum*, a thermally dimorphic ascomycete.⁴⁹ The mould form is distributed worldwide in moist and enriched soils containing bird droppings or bat guano.⁵⁰ Autochthonous cases of HIV-associated histoplasmosis have been described on five continents, the Americas accounting for most cases, notably the central eastern USA and Latin America.⁵¹ However, HIV-associated histoplasmosis is more widespread than was previously thought and is probably neglected, undiagnosed, or misdiagnosed as

tuberculosis.⁵² In endemic areas, histoplasmosis occurs in 2–25% of patients with HIV/AIDS and represents the first AIDS-defining infection in up to 50–75% of patients with HIV.⁵³ Mortality rates range between 10% and 60%, depending on whether the diagnosis is made by experienced physicians with adequate infrastructure and access to antifungals other than fluconazole.^{54,55}

Pathogenesis

Soil disruption aerosolises microconidia or mycelial fragments, which are inhaled and, at body temperature, convert into yeasts in the lungs.⁵⁰ Infection might also develop when, years after the primary infection, quiescent organisms are reactivated during immunosuppression.⁵⁶ Once in the lungs, *H capsulatum* survives phagocytosis in macrophages, facilitating its dissemination throughout the mononuclear phagocyte system. An early robust proinflammatory response (Th1/Th17) is required to control *H capsulatum* growth.⁵⁷ Hence, people with HIV are at higher risk of disseminated histoplasmosis, an AIDS-defining disease, which is lethal if left untreated.⁵⁰

Environmental exposures to bird droppings or bat guano and history of exposure to chicken coops are associated with an increased risk of histoplasmosis.⁵⁸ Host factors such as low CD4 count lower than 200 cells

per μL , nadir CD4 count lower than 50 cells per μL , CD8 count lower than 50 cells per μL , absence of ART or systemic antifungal therapy, the first 6 months of ART, history of herpes simplex virus infection, and male sex are independently associated with histoplasmosis in people with HIV infection.⁵⁹

Clinical features and diagnosis

In AIDS, histoplasmosis usually presents as a disseminated disease (>95% of patients). All organs and tissues can be involved. Fever, fatigue, and weight loss are almost universal. Cough and dyspnoea are the most frequent localising symptoms, in association with diffuse radiological infiltrates, usually with a miliary reticulonodular pattern (figure 2A).⁵³ Abdominal pain and diarrhoea are frequent and reflective of colonic ulcerations (figure 2C). Lymph node enlargement, hepatosplenomegaly, and mucocutaneous manifestations are diagnostic clues.⁵³ Lactate dehydrogenase, liver enzymes (a higher concentration of aspartate aminotransferase than alanine aminotransferase), and ferritin elevation, with or without pancytopenia and haemophagocytosis syndrome, should lead to further investigations.⁵¹ Usually subacute (1–2 months), the disease evolution varies from latency to 10–20% fulminant severe forms (septic shock

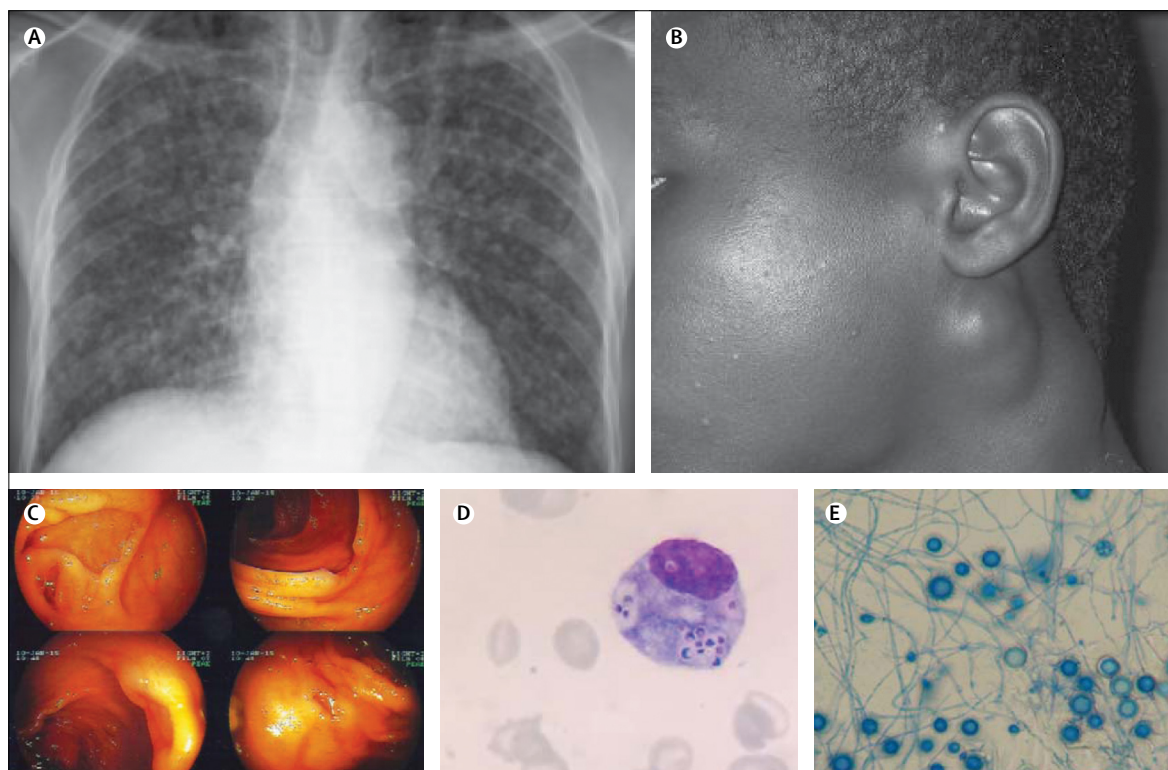


Figure 2: Features of histoplasmosis in patients with HIV

Chest radiograph showing a diffuse interstitial reticulonodular pattern in a patient with histoplasmosis (A). Photograph of a lymph node enlargement in histoplasmosis (B). Photographs of colonic ulcerations in a patient with histoplasmosis (C). Giemsa-stained bone marrow smear showing the yeast phase of *Histoplasma capsulatum* (D). Lactophenol blue-stained bone marrow culture showing the mould form of *H capsulatum* (E). Used with permission of P Couppié (A, B, C) and C Aznar (D, E) from Cayenne General Hospital, France.

with multiorgan failure), mainly in late presenters, with fatality rates reaching 50–70%.^{51,53}

Direct examination with special staining (May-Grünwald Giemsa, periodic acid–Schiff, and Grocott-Gömöri's methenamine-silver) and culture of all tissues or body fluids at room temperature are the gold standard methods for diagnosis.⁶⁰ Bone marrow aspiration, blood culture, and tissue biopsies are all useful.⁵¹ Direct examination is rapid, but culture, which requires a biosafety level 3 laboratory, takes a median of 2 weeks, and maximum of 6 weeks. For both methods, sensitivity varies with sample type, disease severity, and operator experience.⁵¹ Antibody detection in cerebrospinal fluid is of most interest for the diagnosis of neurospinal forms.⁶¹ Although useful molecular tools are being developed, their place in care and treatment is still evolving.⁵¹ Detection of *H capsulatum* antigen is among the most sensitive and rapid means to diagnose disseminated histoplasmosis in AIDS.⁶² The non-invasive reference method in the USA has been a polyclonal quantitative *Histoplasma* spp antigen radioimmunoassay in urine, blood, and bronchoalveolar lavage, but it is unavailable in other endemic areas.⁵¹ However, a new commercially available monoclonal ELISA detecting galactomannan antigen in urine is being made widely available; with promising results.^{62,63} It is noteworthy that the highest yield is achieved through the combination of several diagnostic methods.

Therapy

In moderately severe to severe cases, intravenous L-AmB (3–4 mg/kg per day) is recommended for 2 weeks or until clinical improvement.⁶⁴ An alternative lipid formulation of amphotericin B at the same dosage might be preferred

over D-AmB (0.7 mg/kg per day) if L-AmB is unavailable. Continued treatment with oral itraconazole (200 mg three times a day for 3 days, followed by 200 mg twice a day) is given for at least 1 year.⁶⁴ Patients with non-severe cases can be treated with itraconazole alone.⁶⁴ Prevention is based on recommendations for workers at risk, and long-term suppressive therapy with itraconazole 200 mg a day as primary (only in the USA) or secondary prophylaxis.⁶⁵ ART should be started promptly, within the month after antifungal therapy initiation.⁶⁴ Nevirapine and efavirenz are moderate inducers of the CYP3A4 enzyme, and reduce the concentration of itraconazole.⁶⁶ However, both itraconazole and its major metabolite hydroxyitraconazole are equally active antifungal drugs, and it is unclear whether itraconazole dose adjustment is needed. In view of these interactions, a randomly obtained serum level of at least 1.0 µg/mL of itraconazole is recommended after 2 weeks of therapy.^{64,67}

Morbidity and mortality from histoplasmosis have increased, largely attributable to the spread of HIV.⁶⁸ Although thousands are dying of a treatable disease, histoplasmosis is off the radar of international organisations involved in the fight against HIV/AIDS and tuberculosis.⁶⁹ Hence, the global burden of histoplasmosis remains unknown and access to rapid and simple diagnostics and effective antifungals remains a challenge in low-income and middle-income countries.^{69,70}

Talaromycosis (formerly penicilliosis)

Epidemiology

T marneffei causes a life-threatening mycosis affecting primarily immunocompromised residents and travellers in southeast Asia, southern China, and northeastern India (figure 3).^{71,72} The intersection with HIV has transformed *T marneffei* from a rare human pathogen to a major cause of HIV-associated death, second only to tuberculosis and cryptococcosis or pneumocystis pneumonia in Thailand and Hong Kong.^{73,74} In Vietnam, talaromycosis makes up 4–11% of AIDS-related admissions^{75,76} and is the second most common cause of bloodstream infections after cryptococcosis.⁷⁷ ART has led to a decline in incidence, but talaromycosis remains a major problem in people with undiagnosed and untreated HIV infection. Increasingly talaromycosis occurs outside endemic regions because of increased migration and international travel⁷⁸ and a rise in use of chemotherapy and immunosuppression.⁷⁹

Ecology and transmission

Pathogen reservoirs and disease acquisition are being elucidated. The bamboo rat is the only non-human host of *T marneffei* with a high frequency of asymptomatic infection.^{80,81} Isolates from bamboo rat and human beings have similar or identical genotypes.^{80,81} However, there is no evidence of direct bamboo-rat-to-human transmission; instead, occupational exposure to plants and animals has been associated with human

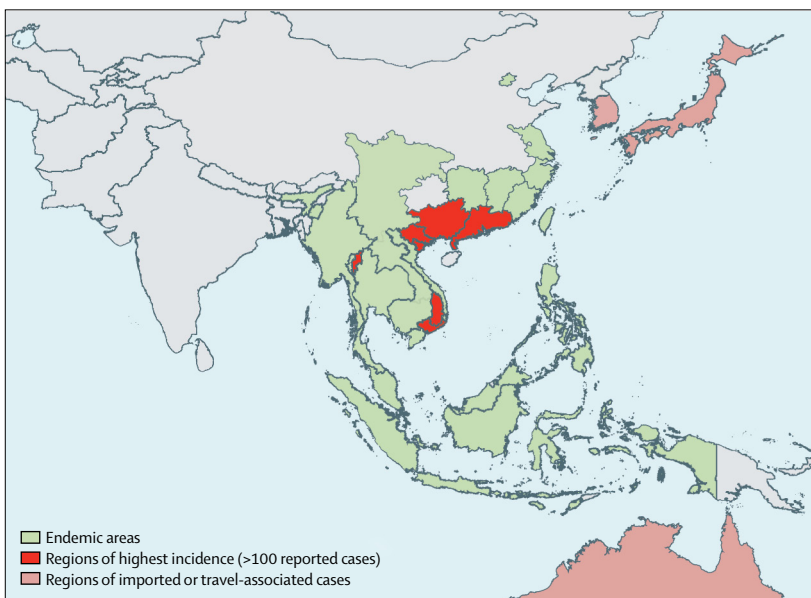


Figure 3: Geographical distribution of *Talaromyces marneffei* infection

infection.⁸² This association is recently confirmed in a large case-control study from Vietnam, which additionally revealed that residents from or travellers to highland areas are at increased risk.⁸³ Incidence increases 30–50% during the rainy months,^{76,84} and can be predicted by humidity levels.^{85,86} *T marneffei* has been isolated from bamboo rat faeces and soil samples within bamboo rat burrows,^{87,88} and *T marneffei* DNA detected in elephant-associated soil.⁸⁹ Collectively, these epiecological data suggest an interplay among multiple environmental reservoirs involving soil, plants, and animals, in which bamboo rats may be exploited by *T marneffei* to expand its biomass and biogeography. Infections in people probably occur through inhalation of *T marneffei* conidia. The incubation period is estimated to be 1–3 weeks in acute disease, whereas reactivation disease can occur many years after exposure in immunocompromised hosts.

Clinical features and outcomes

Most infections with talaromycosis occur in patients with CD4 counts lower than 100 cells per μL . Patients typically develop disseminated disease with fever, weight loss, hepatosplenomegaly, lymphadenopathy, and respiratory and gastrointestinal abnormalities. Papulonecrotic skin lesions are present in 60–70% of patients (figure 4A). Common laboratory findings include anaemia, thrombocytopenia, and elevated transaminases.^{71,75,76} Concomitant opportunistic infections are common, particularly tuberculosis and salmonella infections.^{75,76}

Case fatality rates in treated patients vary, from 10% in Thailand and Hong Kong^{71,90} to 33% in China and Vietnam,^{76,85,91} reflecting differences in time to diagnosis and access to ART. Some clinical and laboratory predictors of mortality include older age, shorter duration of symptoms, dyspnoea, absence of fever or skin lesions, thrombocytopenia, and increased lactate dehydrogenase concentrations.^{75,76}

T marneffei-associated IRIS has been reported; commonly occurring as unmasking IRIS in patients starting ART.

Skin lesions can be atypical, including erythematous nodules, verrucous lesions, or erythematous plaques.^{92,93} Prospective studies that define incidence, risk, and impact of talaromycosis IRIS are needed. Continuation of ART, antifungal therapy, and cautious use of non-steroidal anti-inflammatory medications are the main therapeutic approaches.

Diagnosis

Presumptive diagnosis can be made based on microscopic findings of intramacrophage and extramacrophage yeast organisms in smears of skin lesions, lymph node, or bone marrow aspirate (figure 4B). Definitive diagnosis is made by pathogen isolation from clinical specimens demonstrating thermal dimorphism (figure 4C). Culture can be slow (3–14 days), resulting in diagnostic delay and raised mortality, particularly in patients without skin lesions.^{73,76} PCR-based assays have been developed for rapid diagnosis,^{94,95} however, the sensitivities are insufficient (range 60–70%) to be considered widely applicable. Recently developed ELISA to detect *T marneffei* antigen appears to be more sensitive than blood culture and other diagnostic methods,^{96,97} and should be further evaluated for clinical application. Point-of-care tests are urgently needed.

Antifungal therapy and prevention

D-AmB and itraconazole are effective drugs in talaromycosis, whereas *T marneffei* is resistant to fluconazole.^{75,76,90,91} The IVAP multicentre trial comparing D-AmB and itraconazole induction therapy reported mortality after 6 months of 11.3% and 21.0%, respectively (absolute risk difference 9.7%, 95% CI 2.8–16.6; $p=0.006$).⁹⁸ L-AmB and voriconazole are also effective; however, these drugs are not available in resource-limited settings. International guidelines recommend D-AmB (0.6–1.0 mg/kg per day) for 2 weeks, followed by itraconazole 400 mg per day for 10 weeks, with itraconazole 200 mg per day continued until CD4 counts are higher than 100 cells per μL for at least 6 months.⁹⁹ Primary

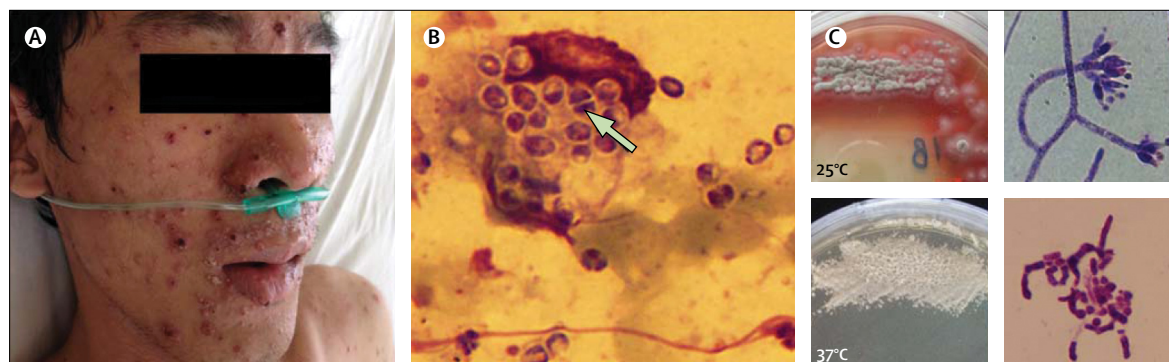


Figure 4: Features of talaromycosis in patients with HIV

Photograph of skin lesions in a patient with talaromycosis (A). Giemsa-stained touch skin smear showing oval-shaped yeast organisms inside and outside of a ruptured macrophage (B). The arrowhead highlights the midline septum in a dividing yeast cell characteristic of *Talaromyces marneffei*. Morphology of *T marneffei* colonies and *T marneffei* cells grown at 25°C and at 37°C on Sabouraud agar medium (C).

Search strategy and selection criteria

We identified references for this Series paper through searches of PubMed for articles published from January 1, 1980, to June 30, 2016, by use of the terms “pneumocystis, PCP, *P carinii*, *P jirovecii*, cryptococcal meningitis, cryptococcosis, *C neoformans*, *C gattii*, histoplasmosis, *Histoplasma capsulatum*, *Penicillium marneffeii*, penicilliosis, *Talaromyces marneffeii*, talaromycosis, fungal infection, mycoses, AND (HIV OR AIDS)”. We identified relevant articles published before these dates and abstracts through searches of our records. We reviewed articles resulting from these searches and relevant references cited in those articles. Articles published in English, French, and Spanish were included.

prophylaxis with itraconazole reduces invasive fungal infections in patients with CD4 counts lower than 200 cells per μL ;¹⁰⁰ however, the strategy has not been widely adopted in Asia because of concerns about costs, toxic effects, drug resistance, and interactions.

Conclusion

Serious fungal infections continue to contribute considerably to HIV/AIDS-related mortality worldwide. For pneumocystosis, talaromycosis, and particularly histoplasmosis, affordable, rapid point-of-care diagnostic tests, as have been developed for cryptococcosis, are urgently needed. Antifungal drugs, including D-AmB, L-AmB, and flucytosine, need to be made much more widely available.¹⁰¹ D-AmB and flucytosine have been recently added to the WHO Model List of Essential Medicines. Such measures, together with continued international efforts for education and training in the management of fungal disease, have the potential to greatly improve patient outcomes.

Contributors

All authors planned the scope of the review. AHL, TSH, AA, and TL wrote the first drafts of the sections on pneumocystis, cryptococcosis, histoplasmosis, and talaromycosis, respectively. All authors contributed to and edited the final manuscript.

Declaration of interests

TSH received an investigator award from Gilead Sciences, diagnostic tests for research from ImmunoMycologics, honoraria from Pfizer, and serves on the advisory board for Viamet. AA spoke for Janssen Pharmaceutical Companies of Johnson & Johnson (in 2016) and received diagnostic tests for research from the Centers for Disease Control and Prevention Mycotic Diseases Branch and from IMMY (ImmunoMycologics). AHL and TL report no competing interests.

Acknowledgments

TL is supported by the Hawaii Center for AIDS in the US and by the Joint Global Health Trial Grant funded by the Wellcome Trust, the Medical Research Council, and the Department for International Development in the UK. AA is supported by an “Investissement d’Avenir” grant managed by Agence Nationale de la Recherche (CEBA; reference ANR-10-LABX-0025), by the Agence Nationale de Recherche sur le SIDA et les hépatites virales—Agence autonome de l’Institut National de la Santé et de la Recherche Médicale (ANRS-Inserm number 12260) and by the European Union (PO FEDER 2007–2013, number Présage: 31362, Guyane Française).

References

- 1 Nguyen C, Barker BM, Hoover S, et al. Recent advances in our understanding of the environmental, epidemiological, immunological, and clinical dimensions of coccidioidomycosis. *Clin Microbiol Rev* 2013; **26**: 505–25.
- 2 Schwartz IS, Govender NP, Corcoran C, et al. Clinical characteristics, diagnosis, management, and outcomes of disseminated emmonsiosis: a retrospective case series. *Clin Infect Dis* 2015; **61**: 1004–12.
- 3 Buchacz K, Lau B, Jing Y, et al. Incidence of AIDS-defining opportunistic infections in a multicohort analysis of hiv-infected persons in the United States and Canada, 2000–2010. *J Infect Dis* 2016; **214**: 862–72.
- 4 Jarvis JN, Boule A, Loyse A, et al. High ongoing burden of cryptococcal disease in Africa despite antiretroviral roll out. *AIDS* 2009; **23**: 1182–83.
- 5 Siedner MJ, Ng CK, Bassett IV, Katz IT, Bangsberg DR, Tsai AC. Trends in CD4 count at presentation to care and treatment initiation in sub-Saharan Africa, 2002–2013: a meta-analysis. *Clin Infect Dis* 2015; **60**: 1120–27.
- 6 Beardsley J, Wolbers M, Kibengo FM, et al. Adjunctive dexamethasone in HIV-associated cryptococcal meningitis. *N Engl J Med* 2016; **374**: 542–54.
- 7 Brown GD, Denning DW, Gow NA, Levitz SM, Netea MG, White TC. Hidden killers: human fungal infections. *Sci Transl Med* 2012; **4**: 165rv13.
- 8 Thomas CF, Jr., Limper AH. Current insights into the biology and pathogenesis of pneumocystis pneumonia. *Nat Rev Microbiol* 2007; **5**: 298–308.
- 9 Thomas CF Jr, Limper AH. Pneumocystis pneumonia. *N Engl J Med* 2004; **350**: 2487–98.
- 10 Lopez-Sanchez C, Falco V, Burgos J, et al. Epidemiology and long-term survival in HIV-infected patients with *Pneumocystis jirovecii* pneumonia in the HAART era: experience in a university hospital and review of the literature. *Medicine* 2015; **94**: e681.
- 11 Cushion MT. Are members of the fungal genus *Pneumocystis* (a) commensals; (b) opportunists; (c) pathogens; or (d) all of the above? *PLoS Pathog* 2010; **6**: e1001009.
- 12 Pifer LL, Hughes WT, Stagno S, Woods D. *Pneumocystis carinii* infection: evidence for high prevalence in normal and immunosuppressed children. *Pediatrics* 1978; **61**: 35–41.
- 13 Limper AH, Knox KS, Sarosi GA, et al. An official American Thoracic Society Statement: treatment of fungal infections in adult pulmonary and critical care patients. *Am J Respir Crit Care Med* 2011; **183**: 96–128.
- 14 Chave JP, David S, Wauters JP, Van Melle G, Francioli P. Transmission of *Pneumocystis carinii* from AIDS patients to other immunosuppressed patients: a cluster of *Pneumocystis carinii* pneumonia in renal transplant recipients. *AIDS* 1991; **5**: 927–32.
- 15 Keely SP, Baughman RP, Smulian AG, Dohn MN, Stringer JR. Source of *Pneumocystis carinii* in recurrent episodes of pneumonia in AIDS patients. *AIDS* 1996; **10**: 881–88.
- 16 Krajicek BJ, Limper AH, Thomas CF Jr. Advances in the biology, pathogenesis and identification of pneumocystis pneumonia. *Curr Opin Pulm Med* 2008; **14**: 228–34.
- 17 Morris A, Kingsley LA, Groner G, Lebedeva IP, Beard CB, Norris KA. Prevalence and clinical predictors of pneumocystis colonization among HIV-infected men. *AIDS* 2004; **18**: 793–98.
- 18 Wilson JW, Limper AH, Grys TE, Karre T, Wengenack NL, Binnicker MJ. *Pneumocystis jirovecii* testing by real-time polymerase chain reaction and direct examination among immunocompetent and immunosuppressed patient groups and correlation to disease specificity. *Diagn Microbiol Infect Dis* 2011; **69**: 145–52.
- 19 Onishi A, Sugiyama D, Kogata Y, et al. Diagnostic accuracy of serum 1,3-beta-D-glucan for *Pneumocystis jirovecii* pneumonia, invasive candidiasis, and invasive aspergillosis: systematic review and meta-analysis. *J Clin Med* 2012; **50**: 7–15.
- 20 Lanaspá M, O’Callaghan-Gordo C, Machevo S, et al. High prevalence of *Pneumocystis jirovecii* pneumonia among Mozambican children <5 years of age admitted to hospital with clinical severe pneumonia. *Clin Microbiol Infect* 2015; **21**: 1018 e9–e15.
- 21 Ewald H, Raatz H, Boscacci R, Furrer H, Bucher HC, Briel M. Adjunctive corticosteroids for *Pneumocystis jirovecii* pneumonia in patients with HIV infection. *Cochrane Database Syst Rev* 2015; **4**: CD006150.

- 22 Bye MR, Cairns-Bazarian AM, Ewig JM. Markedly reduced mortality associated with corticosteroid therapy of *Pneumocystis carinii* pneumonia in children with acquired immunodeficiency syndrome. *Arch Pediatr Adolesc Med* 1994; **148**: 638–41.
- 23 Masur H, Brooks JT, Benson CA, et al. Prevention and treatment of opportunistic infections in HIV-infected adults and adolescents: Updated Guidelines from the Centers for Disease Control and Prevention, National Institutes of Health, and HIV Medicine Association of the Infectious Diseases Society of America. *Clin Infect Dis* 2014; **58**: 1308–11.
- 24 Church JA, Fitzgerald F, Walker AS, Gibb DM, Prendergast AJ. The expanding role of co-trimoxazole in developing countries. *Lancet Infect Dis* 2015; **15**: 327–39.
- 25 Kling HM, Norris KA. Vaccine-induced immunogenicity and protection against pneumocystis pneumonia in a nonhuman primate model of HIV and pneumocystis coinfection. *J Infect Dis* 2016; **213**: 1586–95.
- 26 Jarvis JN, Bicanic T, Loyse A, et al. Determinants of mortality in a combined cohort of 501 patients with HIV-associated cryptococcal meningitis: implications for improving outcomes. *Clin Infect Dis* 2014; **58**: 736–45.
- 27 Jarvis JN, Percival A, Bauman S, et al. Evaluation of a novel point-of-care cryptococcal antigen test on serum, plasma, and urine from patients with HIV-associated cryptococcal meningitis. *Clin Infect Dis* 2011; **53**: 1019–23.
- 28 Jarvis JN, Lawn SD, Vogt M, Bangani N, Wood R, Harrison TS. Screening for cryptococcal antigenemia in patients accessing an antiretroviral treatment program in South Africa. *Clin Infect Dis* 2009; **48**: 856–62.
- 29 Perfect JR, Dismukes WE, Dromer F, et al. Clinical practice guidelines for the management of cryptococcal disease: 2010 update by the infectious Diseases Society of America. *Clin Infect Dis* 2010; **50**: 291–322.
- 30 WHO Guidelines Approved by the Guidelines Review Committee. Rapid advice: diagnosis, prevention and management of cryptococcal disease in HIV-infected adults, adolescents and children. Geneva: World Health Organization, 2011.
- 31 Brouwer AE, Rajanuwong A, Chierakul W, et al. Combination antifungal therapies for HIV-associated cryptococcal meningitis: a randomised trial. *Lancet* 2004; **363**: 1764–67.
- 32 Day JN, Chau TT, Wolbers M, et al. Combination antifungal therapy for cryptococcal meningitis. *N Engl J Med* 2013; **368**: 1291–302.
- 33 Hamill RJ, Sobel JD, El-Sadr W, et al. Comparison of 2 doses of liposomal amphotericin B and conventional amphotericin B deoxycholate for treatment of AIDS-associated acute cryptococcal meningitis: a randomized, double-blind clinical trial of efficacy and safety. *Clin Infect Dis* 2010; **51**: 225–32.
- 34 Loyse A, Dromer F, Day J, Lortholary O, Harrison TS. Flucytosine and cryptococcosis: time to urgently address the worldwide accessibility of a 50-year-old antifungal. *J Antimicrob Chemother* 2013; **68**: 2435–44.
- 35 Graybill JR, Sobel J, Saag M, et al. Diagnosis and management of increased intracranial pressure in patients with AIDS and cryptococcal meningitis. The NIAID Mycoses Study Group and AIDS Cooperative Treatment Groups. *Clin Infect Dis* 2000; **30**: 47–54.
- 36 Rolfes MA, Hullsiek KH, Rhein J, et al. The effect of therapeutic lumbar punctures on acute mortality from cryptococcal meningitis. *Clin Infect Dis* 2014; **59**: 1607–14.
- 37 Bicanic T, Brouwer AE, Meintjes G, et al. Relationship of cerebrospinal fluid pressure, fungal burden and outcome in patients with cryptococcal meningitis undergoing serial lumbar punctures. *AIDS* 2009; **23**: 701–06.
- 38 Macsween KF, Bicanic T, Brouwer AE, Marsh H, Macallan DC, Harrison TS. Lumbar drainage for control of raised cerebrospinal fluid pressure in cryptococcal meningitis: case report and review. *J Infect* 2005; **51**: e221–24.
- 39 Fessler RD, Sobel J, Guyot L, et al. Management of elevated intracranial pressure in patients with cryptococcal meningitis. *J Acquir Immune Defic Syndr Hum Retrovirol* 1998; **17**: 137–42.
- 40 Makadzange AT, Ndhlovu CE, Takarinda K, et al. Early versus delayed initiation of antiretroviral therapy for concurrent HIV infection and cryptococcal meningitis in sub-saharan Africa. *Clin Infect Dis* 2010; **50**: 1532–38.
- 41 Boulware DR, Meya DB, Muzoora C, et al. Timing of antiretroviral therapy after diagnosis of cryptococcal meningitis. *N Engl J Med* 2014; **370**: 2487–98.
- 42 Longley N, Harrison TS, Jarvis JN. Cryptococcal immune reconstitution inflammatory syndrome. *Curr Opin Infect Dis* 2013; **26**: 26–34.
- 43 Bicanic T, Meintjes G, Rebe K, et al. Immune reconstitution inflammatory syndrome in HIV-associated cryptococcal meningitis: a prospective study. *J Acquir Immune Defic Syndr* 2009; **51**: 130–34.
- 44 Meya DB, Manabe YC, Castelnovo B, et al. Cost-effectiveness of serum cryptococcal antigen screening to prevent deaths among HIV-infected persons with a CD4+ cell count < or = 100 cells/microL who start HIV therapy in resource-limited settings. *Clin Infect Dis* 2010; **51**: 448–55.
- 45 Jarvis JN, Harrison TS, Lawn SD, Meintjes G, Wood R, Cleary S. Cost effectiveness of cryptococcal antigen screening as a strategy to prevent HIV-associated cryptococcal meningitis in South Africa. *PLoS One* 2013; **8**: e69288.
- 46 Mfinanga S, Chanda D, Kivuyo SL, et al. Cryptococcal meningitis screening and community-based early adherence support in people with advanced HIV infection starting antiretroviral therapy in Tanzania and Zambia: an open-label, randomised controlled trial. *Lancet* 2015; **385**: 2173–82.
- 47 Longley N, Jarvis JN, Meintjes G, et al. Cryptococcal antigen screening in patients initiating ART in South Africa: a prospective cohort study. *Clin Infect Dis* 2016; **62**: 581–87.
- 48 Smith KD, Achan B, Hullsiek KH, et al. Increased antifungal drug resistance in clinical isolates of *Cryptococcus neoformans* in Uganda. *Antimicrob Agents Chemother* 2015; **59**: 7197–204.
- 49 Brandt ME, Gómez BL, Warnock D. Histoplasma, blastomyces, coccidioides, and other dimorphic fungi causing systemic mycoses In: Versalovic J, Carroll KC, Funke G, et al, eds. Manual of Clinical Microbiology. 10th edn. Washington DC: American Society for Microbiology, 2011: 1902–18.
- 50 Woods JP. Revisiting old friends: Developments in understanding *Histoplasma capsulatum* pathogenesis. *J Microbiol* 2016; **54**: 265–76.
- 51 Adenis AA, Aznar C, Couppie P. Histoplasmosis in HIV-infected patients: a review of new developments and remaining gaps. *Curr Trop Med Rep* 2014; **1**: 119–28.
- 52 Nacher M, Adenis A, Aznar C, et al. How many have died from undiagnosed human immunodeficiency virus-associated histoplasmosis, a treatable disease? Time to act. *Am J Trop Med Hyg* 2013; **90**: 193–94.
- 53 Wheat J. Endemic mycoses in AIDS: a clinical review. *Clin Microbiol Rev* 1995; **8**: 146–59.
- 54 Peigne V, Dromer F, Elie C, Lidove O, Lortholary O. Imported acquired immunodeficiency syndrome-related histoplasmosis in metropolitan France: a comparison of pre-highly active anti-retroviral therapy and highly active anti-retroviral therapy eras. *Am J Trop Med Hyg* 2011; **85**: 934–41.
- 55 Adenis A, Nacher M, Hanf M, et al. HIV-associated histoplasmosis early mortality and incidence trends: from neglect to priority. *PLoS Negl Trop Dis* 2014; **8**: e3100.
- 56 Hanf M, Adenis A, Couppie P, Carme B, Nacher M. HIV-associated histoplasmosis in French Guiana: recent infection or reactivation? *AIDS* 2010; **24**: 1777–78.
- 57 Kroetz DN, Deepe GS. The role of cytokines and chemokines in *Histoplasma capsulatum* infection. *Cytokine* 2012; **58**: 112–17.
- 58 Hajjeh RA, Pappas PG, Henderson H, et al. Multicenter case-control study of risk factors for histoplasmosis in human immunodeficiency virus-infected persons. *Clin Infect Dis* 2001; **32**: 1215–20.
- 59 Nacher M, Adenis A, Blanchet D, et al. Risk factors for disseminated histoplasmosis in a cohort of HIV-infected patients in French Guiana. *PLoS Negl Trop Dis* 2014; **8**: e2638.
- 60 De Pauw B, Walsh TJ, Donnelly JP, et al. Revised definitions of invasive fungal disease from the European Organization for Research and Treatment of Cancer/Invasive Fungal Infections Cooperative Group and the National Institute of Allergy and Infectious Diseases Mycoses Study Group (EORTC/MSG) Consensus Group. *Clin Infect Dis* 2008; **46**: 1813–21.
- 61 Wheat LJ, Musial CE, Jenny-Avital E. Diagnosis and management of central nervous system histoplasmosis. *Clin Infect Dis* 2005; **40**: 844–52.
- 62 Theel ES, Harring JA, Dababneh AS, Rollins LO, Bestrom JE, Jespersen DJ. Reevaluation of commercial reagents for detection of *Histoplasma capsulatum* antigen in urine. *J Clin Microbiol* 2015; **53**: 1198–203.

- 63 Caceres DH, Scheel CM, Tobón AM, et al. Validation in Colombia of a commercial antigen detection test for the diagnosis of progressive disseminated histoplasmosis. 19th Congress of the International Society for Human and Animal Mycology; Melbourne, VIC, Australia; May 4–8, 2015. Abstract 545.
- 64 Panel on Opportunistic Infections in HIV-Infected Adults and Adolescents. Guidelines for the prevention and treatment of opportunistic infections in HIV-infected adults and adolescents: recommendations from the Centers for Disease Control and Prevention, the National Institutes of Health, and the HIV Medicine Association of the Infectious Diseases Society of America. 2013.
- 65 Wheat LJ, Freifeld AG, Kleiman MB, et al. Clinical practice guidelines for the management of patients with histoplasmosis: 2007 update by the Infectious Diseases Society of America. *Clin Infect Dis* 2007; **45**: 807–25.
- 66 Jaruratanasirikul S, Sriwiriyanjan S. Pharmacokinetic study of the interaction between itraconazole and nevirapine. *Eur J Clin Pharmacol* 2007; **63**: 451–56.
- 67 Huet E, Hadji C, Hulin A, Botterel F, Bretagne S, Levy Y. Therapeutic monitoring is necessary for the association itraconazole and efavirenz in a patient with AIDS and disseminated histoplasmosis. *AIDS* 2008; **22**: 1885–86.
- 68 Homei A, Worboys M. Fungal disease in Britain and the United States, 1850–2000, mycoses and modernity. Nov 15, 2013 edn. Manchester, UK: Palgrave Macmillan, 2013.
- 69 Neglected histoplasmosis in Latin America group. Disseminated histoplasmosis in Central and South America, the invisible elephant: the lethal blind spot of international health organizations. *AIDS* 2016; **30**: 167–70.
- 70 Murphy RA, Gounder L, Manzini TC, Ramdial PK, Castilla C, Moosa MY. Challenges in the management of disseminated progressive histoplasmosis in human immunodeficiency virus-infected patients in resource-limited settings. *Open Forum Infect Dis* 2015; **2**: ofv025.
- 71 Supparatpinyo K, Khamwan C, Baosoung V, Nelson KE, Sirisanthana T. Disseminated *Penicillium marneffei* infection in southeast Asia. *Lancet* 1994; **344**: 110–13.
- 72 Vanittanakom N, Cooper CR Jr, Fisher MC, Sirisanthana T. *Penicillium marneffei* infection and recent advances in the epidemiology and molecular biology aspects. *Clin Microbiol Rev* 2006; **19**: 95–110.
- 73 Supparatpinyo K, Chiewchanvit S, Hirunri P, Uthammachai C, Nelson KE, Sirisanthana T. *Penicillium marneffei* infection in patients infected with human immunodeficiency virus. *Clin Infect Dis* 1992; **14**: 871–74.
- 74 Wong KH, Lee SS, Chan KC, Choi T. Redefining AIDS: case exemplified by *Penicillium marneffei* infection in HIV-infected people in Hong Kong. *Int J STD AIDS* 1998; **9**: 555–56.
- 75 Larsson M, Nguyen LH, Wertheim HF, et al. Clinical characteristics and outcome of *Penicillium marneffei* infection among HIV-infected patients in northern Vietnam. *AIDS Res Ther* 2012; **9**: 24.
- 76 Le T, Wolbers M, Chi NH, et al. Epidemiology, seasonality, and predictors of outcome of AIDS-associated *Penicillium marneffei* infection in Ho Chi Minh City, Viet Nam. *Clin Infect Dis* 2011; **52**: 945–52.
- 77 Nga TV, Parry CM, Le T, et al. The decline of typhoid and the rise of non-typhoid salmonellae and fungal infections in a changing HIV landscape: bloodstream infection trends over 15 years in southern Vietnam. *Trans R Soc Trop Med Hyg* 2012; **106**: 26–34.
- 78 Antinori S, Gianelli E, Bonaccorso C, et al. Disseminated *Penicillium marneffei* infection in an HIV-positive Italian patient and a review of cases reported outside endemic regions. *J Travel Med* 2006; **13**: 181–88.
- 79 Chan JF, Chan TS, Gill H, et al. Disseminated infections with *Talaromyces marneffei* in non-AIDS patients given monoclonal antibodies against CD20 and kinase inhibitors. *Emerg Infect Dis* 2015; **21**: 1101–06.
- 80 Gughani H, Fisher MC, Paliwal-Johsi A, Vanittanakom N, Singh I, Yadav PS. Role of *Cannomys badius* as a natural animal host of *Penicillium marneffei* in India. *J Clin Microbiol* 2004; **42**: 5070–75.
- 81 Cao C, Liang L, Wang W, et al. Common reservoirs for *Penicillium marneffei* infection in humans and rodents, China. *Emerg Infect Dis* 2011; **17**: 209–14.
- 82 Chariyalertsak S, Sirisanthana T, Supparatpinyo K, Praparattanapan J, Nelson KE. Case-control study of risk factors for *Penicillium marneffei* infection in human immunodeficiency virus-infected patients in northern Thailand. *Clin Infect Dis* 1997; **24**: 1080–86.
- 83 Le T, Jonat B, Kim Cuc NT, et al. The exposure and geospatial risk factors for AIDS-associated penicilliosis in Vietnam. Conference on Retroviruses and Opportunistic Infections; Seattle, WA, USA; Feb 23–26, 2015.
- 84 Chariyalertsak S, Sirisanthana T, Supparatpinyo K, Nelson KE. Seasonal variation of disseminated *Penicillium marneffei* infections in northern Thailand: a clue to the reservoir? *J Infect Dis* 1996; **173**: 1490–93.
- 85 Hu Y, Zhang J, Li X, et al. *Penicillium marneffei* infection: an emerging disease in mainland China. *Mycopathologia* 2012; **175**: 57–67.
- 86 Bulters PL, Le T, Quang VM, Nelson KE, Lloyd-Smith JO. Environmental predictors and incubation period of AIDS-associated *Penicillium marneffei* infection in Ho Chi Minh City, Vietnam. *Clin Infect Dis* 2013; **56**: 1273–79.
- 87 Chariyalertsak S, Vanittanakom P, Nelson KE, Sirisanthana T, Vanittanakom N. *Rhizomys sumatrensis* and *Cannomys badius*, new natural animal hosts of *Penicillium marneffei*. *J Med V Med* 1996; **34**: 105–10.
- 88 Huang X, He G, Lu S, Liang Y, Xi L. Role of *Rhizomys pruinosus* as a natural animal host of *Penicillium marneffei* in Guangdong, China. *Microb Biotechnol* 2015; **8**: 659–64.
- 89 Pryce-Miller E, Aanensen D, Vanittanakom N, Fisher MC. Environmental detection of *Penicillium marneffei* and growth in soil microcosms in competition with *Talaromyces stipitatus*. *Fungal Ecol* 2008; **1**: 49–56.
- 90 Wu TC, Chan JW, Ng CK, Tsang DN, Lee MP, Li PC. Clinical presentations and outcomes of *Penicillium marneffei* infections: a series from 1994 to 2004. *Hong Kong Med J* 2008; **14**: 103–09.
- 91 Son VT, Khue PM, Strobel M. Penicilliosis and AIDS in Haiphong, Vietnam: evolution and predictive factors of death. *Med Mal Infect* 2014; **44**: 495–501.
- 92 Saikia L, Nath R, Hazarika D, Mahanta J. Atypical cutaneous lesions of *Penicillium marneffei* infection as a manifestation of the immune reconstitution inflammatory syndrome after highly active antiretroviral therapy. *Indian J Dermatol Venereol Leprol* 2010; **76**: 45–48.
- 93 Sudjaritruk T, Sirisanthana T, Sirisanthana V. Immune reconstitution inflammatory syndrome from *Penicillium marneffei* in an HIV-infected child: a case report and review of literature. *BMC Infect Dis* 2012; **12**: 28.
- 94 Lu S, Li X, Calderone R, et al. Whole blood nested PCR and real-time PCR amplification of *Talaromyces marneffei* specific DNA for diagnosis. *Med Mycol* 2016; **54**: 162–68.
- 95 Hien HT, Thanh TT, Thu NT, et al. Development and evaluation of a real-time polymerase chain reaction assay for the rapid detection of *Talaromyces marneffei* MP1 gene in human plasma. *Mycoses* 2016; **59**: 773–80.
- 96 Wang YF, Cai JP, Wang YD, et al. Immunoassays based on *Penicillium marneffei* Mp1p derived from *Pichia pastoris* expression system for diagnosis of penicilliosis. *PLoS One* 2011; **6**: e28796.
- 97 Prakit K, Nosanchuk JD, Pruksaphon K, Vanittanakom N, Youngchim S. A novel inhibition ELISA for the detection and monitoring of *Penicillium marneffei* antigen in human serum. *Eur J Clin Microbiol Infect Dis* 2016; **35**: 647–56.
- 98 Le T, Kinh NV, Cuc NTK, et al. A trial of itraconazole or amphotericin B for HIV-associated talaromycosis. *N Engl J Med* 2017; **376**: 2329–40.
- 99 Kaplan JE, Benson C, Holmes KK, Brooks JT, Pau A, Masur H. Guidelines for prevention and treatment of opportunistic infections in HIV-infected adults and adolescents: recommendations from CDC, the National Institutes of Health, and the HIV Medicine Association of the Infectious Diseases Society of America. *MMWR Recomm Rep* 2009; **58**: 1–207.
- 100 Chariyalertsak S, Supparatpinyo K, Sirisanthana T, Nelson KE. A controlled trial of itraconazole as primary prophylaxis for systemic fungal infections in patients with advanced human immunodeficiency virus infection in Thailand. *Clin Infect Dis* 2002; **34**: 277–84.
- 101 Loyse A, Thangaraj H, Easterbrook P, et al. Cryptococcal meningitis: improving access to essential antifungal medicines in resource-poor countries. *Lancet Infect Dis* 2013; **13**: 629–37.