

Case Report

Video Head Impulse Testing (vHIT) and the Assessment of Horizontal Semicircular Canal Function

DOI: 10.3766/jaaa.14083

Kristal M. Riska*†

Owen Murnane*†

Faith W. Akin*†

Courtney Hall*‡

Abstract

Background: Vestibular function (specifically, horizontal semicircular canal function) can be assessed across a broad frequency range using several different techniques. The head impulse test is a qualitative test of horizontal semicircular canal function that can be completed at bedside. Recently, a new instrument (video head impulse test [vHIT]) has been developed to provide an objective assessment to the clinical test. Questions persist regarding how this test may be used in the overall vestibular test battery.

Purpose: The purpose of this case report is to describe vestibular test results (vHIT, rotational testing, vestibular evoked myogenic potentials, and balance and gait performance) in an individual with a 100% unilateral caloric weakness who was asymptomatic for dizziness, vertigo or imbalance.

Data Collection and/or Analysis: Comprehensive assessment was completed to evaluate vestibular function. Caloric irrigations, rotary chair testing, vHIT, and vestibular evoked myogenic potentials were completed.

Results: A 100% left-sided unilateral caloric weakness was observed in an asymptomatic individual. vHIT produced normal gain with covert saccades.

Conclusions: This case demonstrates the clinical usefulness of vHIT as a diagnostic tool and indicator of vestibular compensation and functional status.

Key Words: vestibular hypofunction, semicircular canal, video head impulse test, case reports, vestibular testing

Abbreviations: AC = air conduction; BC = bone conduction; cVEMP = cervical vestibular evoked myogenic potential; DGI = Dynamic Gait Index; HIT = head impulse test; hSCC = horizontal semicircular canal; oVEMP = ocular vestibular evoked myogenic potential; SHA = sinusoidal harmonic acceleration; UW = unilateral weakness; vHIT = video head impulse test; VOR = vestibular ocular reflex

BACKGROUND

Several techniques and instruments have been developed to supplement the standard video-nystagmography test battery in the assessment

of patients with vertigo, dizziness, and imbalance. These tests include tests of otolith function such as cervical and ocular vestibular evoked myogenic potentials (oVEMPs) and more advanced techniques to assess horizontal canal function such as rotary chair. Cervical

*Vestibular/Balance Laboratory, Auditory and Vestibular Research Enhancement Award Program, VA Medical Center, Mountain Home, TN; †Department of Audiology and Speech-Language Pathology, East Tennessee State University, Johnson City, TN; ‡Department of Physical Therapy, East Tennessee State University, Johnson City, TN

Corresponding author: Kristal M. Riska, VA Medical Center, Mountain Home, TN 37684; E-mail: Kristal.riska@va.gov

vestibular-evoked myogenic potentials (cVEMPs) assess the saccule and/or inferior branch of the vestibular nerve and oVEMPs assess the utricle and/or superior branch of the vestibular nerve. Even with these technical advances that now allow for assessment of the otolith organs, the standard clinical test battery primarily relies on assessment of the horizontal semicircular canal (hSCC) and vestibular ocular reflex (VOR). Further, the standard clinical evaluation of the horizontal VOR has until recently been confined to frequencies below 1 Hz even though the VOR functions as a high-pass filter with frequencies between 1 and 6 Hz being optimally encoded (Minor et al, 1999). The caloric test is considered the “gold standard” test of hSCC function, especially for the identification of unilateral vestibular losses. However, caloric testing generates a very low-frequency stimulation of the hSCCs and is estimated to be equivalent to head movements with a frequency of approximately 0.003 Hz (Hamid et al, 1987). Rotary chair protocols, including the sinusoidal harmonic acceleration (SHA) test and the velocity step test, assess vestibular function across a broader frequency/velocity range (0.01 to 0.64 Hz; peak angular velocities ranging from 30 to 80°/sec for SHA and peak angular velocities of 60 to 240°/sec for velocity step). The frequencies of natural head rotations, however, largely exceed the frequencies typically used for the rotary chair test. For example, the fundamental frequencies of rotational head perturbations during locomotion are in the range of 0.5–5.0 Hz with significant harmonics up to 20 Hz (Grossman et al, 1988; King et al, 1992).

The bedside head impulse test (HIT) can also be used to assess semicircular canal function. The HIT can assess all three semicircular canal planes (Halmagyi and Curthoys, 1988; Aw et al, 1996); however, the hSCC is most often assessed clinically. In this test, the examiner rapidly turns the patient’s head in the horizontal plane while the patient is instructed to fixate on a stationary target. The head turn is a high-frequency/high-velocity stimulus (peak head velocities around 300°/sec and peak head accelerations around 3,000°/sec²; Halmagyi and Curthoys, 1988). An individual with an intact vestibular system is able to maintain steady gaze on the target when the head is rotated. In contrast, patients with vestibular loss are unable to maintain gaze on the target during ipsilesional head rotation. Instead, the eyes move with the head and are taken off target so that at the end of the head rotation the patient makes a voluntary corrective saccade back to the target. The corrective, or ‘catch-up’ saccade is visible to the clinician and, therefore, is called an overt saccade. The observation of an overt saccade is an indirect sign of hSCC hypofunction on the side to which the head was rotated. If a corrective saccade occurs during the head rotation (covert saccades), then it will not be observed by the clinician and thereby increase the likelihood of a false-negative bedside HIT

result. (Weber et al, 2009; Blödow et al, 2013). In the initial work by Halmagyi and Curthoys (1988), the sensitivity and specificity of the bedside HIT was reported as 100% in patients with total unilateral vestibular loss (e.g., unilateral vestibular neurectomy); however, others have demonstrated poorer sensitivity and specificity in patients with partial vestibular loss as measured by caloric stimulation (Foster et al, 1994; Harvey et al, 1997; Schmid-Priscoveanu et al, 2001; Perez and Rama-Lopez, 2003; Schubert et al, 2004). The poorer sensitivity and specificity for partial vestibular losses and the inability to detect covert saccades have limited the usefulness of the bedside HIT.

More recently, the video head impulse test (vHIT) has been developed and is based on the same principles as the HIT (Halmagyi and Curthoys, 1988) but allows for the recording and quantification of the eye and head movement. To perform the vHIT, patients are seated and instructed to maintain their gaze on an earth-fixed visual target. The clinician stands behind the patient and manually rotates the head abruptly and unpredictably to the left or right through a small angle (10–20°) in the horizontal plane to stimulate the left and right hSCCs. To test either of the coplanar vertical canal pairs, right anterior/left posterior or the left anterior/right posterior, the head is positioned ~30–45° relative to the trunk (aligns the vertical canal pair with the trunk’s sagittal plane) prior to rotating the head either downward (stimulates the anterior canal) or upward (stimulates the posterior canal). A high-speed digital infrared video camera uses pupil detection methods to record two-dimensional eye movement during and immediately after the head rotation. The camera is embedded in head-worn goggles. Head movement is recorded by an inertial measurement unit (triaxial linear accelerometer and gyroscopes) mounted on the head-worn goggles. In contrast to the caloric and rotary chair tests which assess hSCC function using low-frequency stimulation, vHIT is capable of evaluating the function of the vertical semicircular canals using high frequency stimulation (Ulmer et al, 2011; MacDougall et al, 2013a, 2013b; Murnane et al, 2014). The vHIT provides the ability to record eye and head movements for measurement of VOR gain and the recording of overt and covert saccades. This case report presents an individual with an unusual pattern of test findings across the vestibular frequency/velocity spectrum and highlights the usefulness of the vHIT in the clinical vestibular test battery.

CASE REPORT

A 25-yr-old female graduate student was identified during a class assignment as having a 100% left unilateral weakness (UW) during caloric testing. The student volunteered to enroll in a Veterans Affairs/East

Tennessee State University Institutional Review Board approved study, and the caloric findings were confirmed by a licensed audiologist (right warm = 37°/sec, right cool = 45°/sec, left warm = 0°/sec, and left cool = 0°/sec). The left-sided caloric weakness was unexpected as the student was asymptomatic for vertigo, dizziness, and/or imbalance and denied any previous history of these symptoms. Pure-tone air conduction (AC) and bone conduction (BC) audiometry, tympanometry, and acoustic reflex thresholds were all consistent with normal, symmetrical hearing bilaterally. Auditory brainstem responses were normal bilaterally.

Comprehensive tests of vestibular function were performed. Random saccades, smooth pursuit, and optokinetic tracking were within normal limits. No spontaneous, gaze-evoked or positional nystagmus was observed. To further assess horizontal canal VOR function, both rotary chair testing (Micromedical System 2000 Rotary Chair, Micromedical Spectrum, 8.8, Micromedical Technologies, Inc., Chatham, IL) and the vHIT (ICS Impulse, OtoSuite V, GN Otometrics) were conducted. During SHA testing, low gain was observed from 0.01–0.32 Hz; gain approximated normal at 0.64 Hz (Figure 1). VOR gain and time constants were also assessed using a 100°/sec velocity step protocol with a 200°/sec² acceleration profile. For velocity steps, a shortened post-rotary time constant (2 sec) was recorded for counter clockwise (leftward) responses, whereas the postrotary time constant (10 sec) was within normal limits for clockwise (rightward) stimulation. In contrast to the SHA results, the vHIT revealed normal VOR gain for both rightward (1.04) and leftward (0.90) horizontal head impulses. Covert saccades, however, were recorded during leftward (ipsilesional) head impulses (Figure 2). No overt saccades were recorded. vHIT results were suggestive of a unilateral peripheral vestibular loss and corroborated the left sided caloric weakness and the abnormally shortened time constants for postrotary counter-clockwise (leftward) velocity step responses.

Vestibular evoked myogenic potentials were performed to assess otolith function. Specifically, AC cVEMPs were used to assess saccule/inferior vestibular nerve function and BC oVEMPs were used to assess utricle/superior vestibular nerve function. AC cVEMPs were obtained using recording methods previously described (Akin and Murnane, 2001) and were present on the left and right side (Figure 3); the asymmetry ratio (13%) was within normal limits. BC oVEMPs (minishaker at Fz) were present beneath each eye (Figure 4) and were symmetrical (asymmetry ratio of 2%) using recording methods described previously (Iwasaki et al, 2007).

Functional gait and balance were assessed using the sensory organization test and the Dynamic Gait Index (DGI). The sensory organization test produced a normal composite score of 89 and the student scored 23 out of 24 on the DGI suggesting mild impairment (Whitney et al, 2000). The

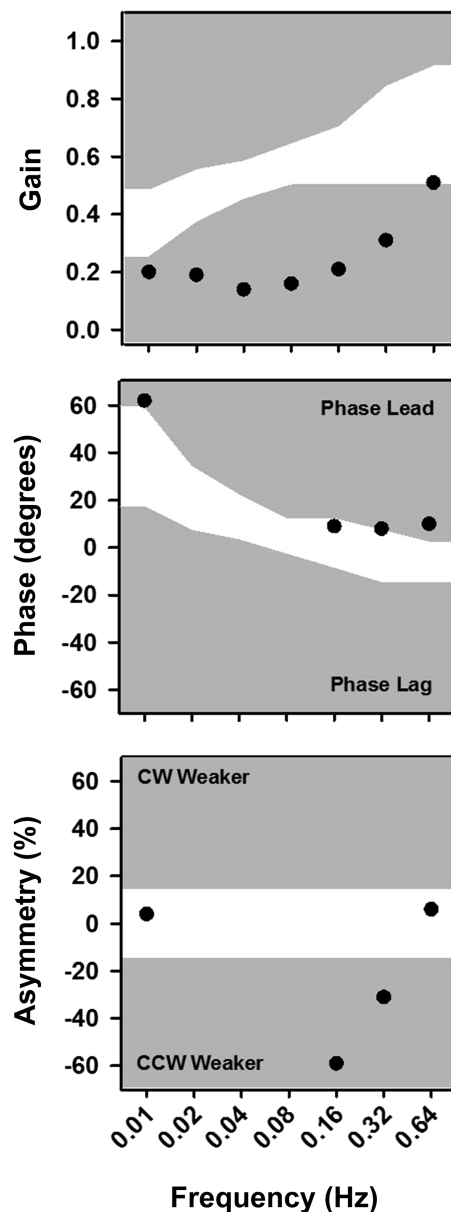


Figure 1. Rotary chair results for an asymptomatic unilateral vestibular loss (100% left-sided caloric weakness). The whitened area represents the normal limits for gain, symmetry, and phase, whereas the gray area represents values falling outside normal range. Gain was significantly reduced in the low- to mid-frequencies. At 0.02, 0.04, and 0.08 Hz, gain was reduced to the point where phase and symmetry cannot be reliably calculated. A phase lead was noted at 0.01 Hz consistent with a UW.

decrease in the DGI was related to a slight decrease in gait velocity during walking with horizontal head turns.

DISCUSSION

This case report presents a novel pattern of vHIT findings in an asymptomatic individual with unilateral vestibular loss. Clinical vestibular tests identified and lateralized a vestibular deficit on the left

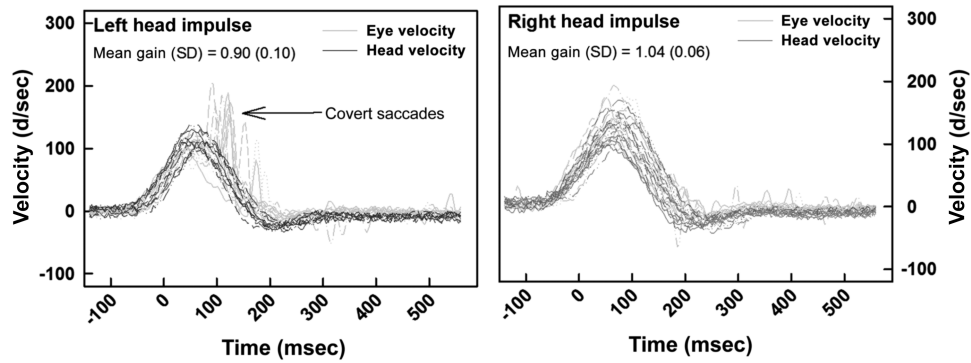


Figure 2. vHIT results for an asymptomatic unilateral vestibular loss. The left panel shows head velocity and corresponding eye velocity waveforms for multiple head impulses in the horizontal plane. Head (blue) and eye (green) velocity waveforms obtained for left horizontal head impulses are on the left and head (red) and eye (green) velocity waveforms obtained for right horizontal head impulses are on the right. VOR gain was within normal limits for left and right horizontal head impulses, however, covert saccades (black arrow) were recorded only for left (ipsilesional) horizontal head impulses. (This figure appears in color in the online version of this article.)

side. Specifically, bithermal caloric testing revealed a total left caloric weakness which is well established as a clinical finding of peripheral vestibular deficit (Baloh et al, 1977). The rotary chair test confirmed the left peripheral vestibular loss, as the key findings were low gain, phase lead, left asymmetry, and shortened time constants (Honrubia et al, 1984; Huygen and Nicolaisen, 1985; Blakeley et al, 1989). In contrast, the vHIT revealed normal VOR gain for both leftward and rightward head impulses; however, covert saccades were recorded for leftward (ipsilesional) head impulses. The normal VOR gain on vHIT was an unexpected finding given the magnitude of the caloric weakness (100%); vHIT has been shown to be sensitive to large caloric weakness (>40–60%) (Bartolomeo et al, 2014; Mahringer and Rambold, 2014; McCaslin et al, 2014). Although recovery of normal VOR gain has been demonstrated in patients with vestibular neuritis (e.g.,

Manzari et al, 2013), our student has no history of vestibular symptoms and the caloric weakness is not consistent with restoration of peripheral vestibular function. It is interesting to note that the vHIT was the only clinical test consistent with the absence of vestibular symptoms. In contrast, the low VOR gain and asymmetry on the rotary chair test suggested that vestibular compensation was incomplete and the caloric weakness is not sensitive to vestibular adaptation. Similar to the vHIT results in this case, Perez-Fernandez et al (2012) observed normal VOR gain in the presence of corrective saccades in 21% of 179 patients referred for vestibular assessment. The mean caloric weakness in those patients, however, was only 39%.

In addition to being diagnostic indicators regarding the outcome of the vHIT (normal versus abnormal), corrective saccades recorded during vHIT may provide insights concerning the time course of adaptation and

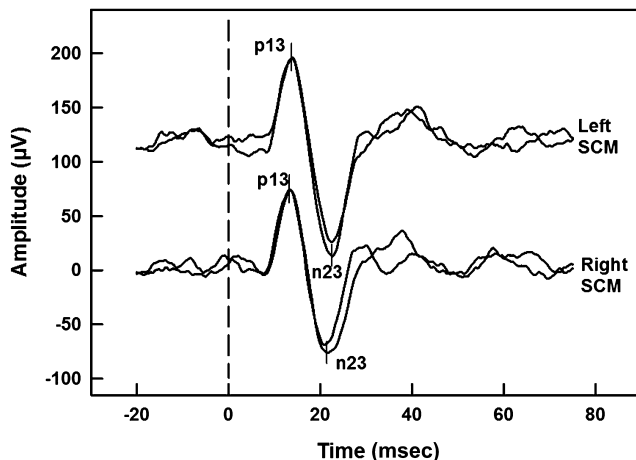


Figure 3. cVEMPs for an asymptomatic unilateral vestibular loss. Both the left and right side elicited strong and symmetrical responses to a 500 Hz air-conducted stimulus suggesting normal utricular and/or superior vestibular nerve function.

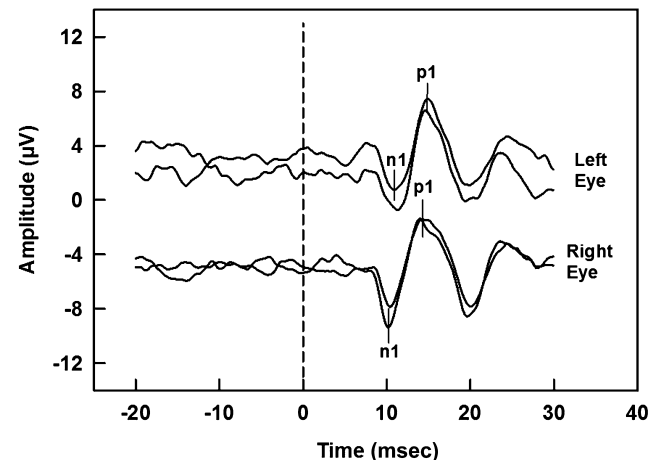


Figure 4. oVEMPs for an asymptomatic unilateral vestibular loss. Responses were symmetrical and within normal limits for the left and right side, suggesting normal utricular and/or superior vestibular nerve function.

compensation following unilateral vestibular loss that might be applicable to patient management and vestibular rehabilitation. Saccadic eye movements are high-velocity ballistic eye movements in which vision is suppressed during the time of the saccadic movement (Richards, 1969; Matin, 1974). Accordingly, Berthoz (1988) proposed that saccades serve as a substitute for a deficient VOR and, therefore, may be important in reducing visual blurring (retinal slip) when vestibular input is reduced. MacDougall and Curthoys (2012) have suggested that the pattern of recorded saccadic eye movements during vHIT may provide an indication of the status of vestibular compensation. Mantokoudis et al (2014) performed vHITs preoperatively and postoperatively in five patients after unilateral vestibular deafferentation from vestibular schwannoma resection. On postoperative days 1 to 3, the corrective saccades were exclusively overt with an average latency of ~193 msec; however, by day 5 the average latency had decreased significantly to 134 msec (covert saccades). The authors hypothesized that patients who do not demonstrate similar decreases in saccade latencies following unilateral vestibular deafferentation may benefit from gaze-stabilizing vestibular rehabilitation. Batuecas-Caletrio et al (2014) examined the latency distribution of corrective saccades recorded during the vHIT in 49 patients one year following vestibular schwannoma surgery. Patients with a relatively wide corrective saccade latency distribution had significantly higher scores on the Dizziness Handicap Inventory than patients with a relatively narrow latency distribution and suggested an association between the latency characteristics of corrective saccades and self-perceived handicap. Recently, Ramaioli et al (2014) examined reading ability during head impulses in subjects with pharmacologically reduced VOR gain. One individual was able to generate consistent covert saccades and had minimal degradation in reading ability during head rotation. In contrast, subjects who were unable to generate covert saccades demonstrated significant reductions in dynamic visual acuity. The results of this case also indicate that the vHIT, in addition to detecting and lateralizing a vestibular lesion, may also provide useful information concerning the status of central compensation.

This case demonstrates the clinical usefulness of vHIT as an indicator of vestibular compensation and the patient's functional status. The vHIT may be unique as a test of hSCC/VOR function as it provides both diagnostic information as well as insights into the time course of adaptation and compensation following unilateral vestibular loss. Further research is needed to determine the role of vHIT in the management and rehabilitation of patients with vestibular disorders.

Acknowledgments. The authors acknowledge Stephanie Byrd, AuD, and Amber Pearson, AuD, for their help with data acquisition. Support for this study was provided by the Audi-

tory Vestibular Dysfunction Research Enhancement Award Program at Mountain Home VAMC sponsored by the Rehabilitation Research and Development Service, Department of Veterans Affairs, Washington, DC. The contents do not represent the views of the Department of Veterans Affairs or the United States Government.

REFERENCES

- Akin FW, Murnane OD. (2001) Vestibular evoked myogenic potentials: preliminary report. *J Am Acad Audiol* 12(9):445–452, quiz 491.
- Aw ST, Haslwanter T, Halmagyi GM, Curthoys IS, Yavor RA, Todd MJ. (1996) Three-dimensional vector analysis of the human vestibuloocular reflex in response to high-acceleration head rotations. I. Responses in normal subjects. *J Neurophysiol* 76(6):4009–4020.
- Baloh RW, Sills AW, Honrubia V. (1977) Caloric testing. 3. Patients with peripheral and central vestibular lesions. *Ann Otol Rhinol Laryngol Suppl* 86(5 Pt 3 Suppl 43):24–30.
- Bartolomeo M, Biboulet R, Pierre G, Mondain M, Uziel A, Venail F. (2014) Value of the video head impulse test in assessing vestibular deficits following vestibular neuritis. *Eur Arch Otorhinolaryngol* 271(4):681–688.
- Batuecas-Caletrio A, Santacruz-Ruiz S, Muñoz-Herrera A, Perez-Fernandez N. (2014) The vestibulo-ocular reflex and subjective balance after vestibular schwannoma surgery. *Laryngoscope* 124(6):1431–1435.
- Berthoz A. (1988) The role of gaze in compensation of vestibular dysfunction: the gaze substitution hypothesis. *Prog Brain Res* 76:411–420.
- Blakley BW, Barber HO, Tomlinson RD, McIlmoy L. (1989) Changes in the time constants of the vestibulo-ocular reflex and optokinetic afternystagmus following unilateral ablative vestibular surgery. *J Otolaryngol* 18(5):210–217.
- Blödow A, Pannasch S, Walther LE. (2013) Detection of isolated covert saccades with the video head impulse test in peripheral vestibular disorders. *Auris Nasus Larynx* 40(4):348–351.
- Fetter M, Zee DS. (1988) Recovery from unilateral labyrinthectomy in rhesus monkey. *J Neurophysiol* 59(2):370–393.
- Foster CA, Foster BD, Spindler J, Harris JP. (1994) Functional loss of the horizontal doll's eye reflex following unilateral vestibular lesions. *Laryngoscope* 104(4):473–478.
- Grossman GE, Leigh RJ, Abel LA, Lanska DJ, Thurston SE. (1988) Frequency and velocity of rotational head perturbations during locomotion. *Exp Brain Res* 70(3):470–476.
- Hamid M, Hughes G, Kinney S. (1987) Criteria for diagnosing bilateral vestibular dysfunction. In: Graham MD, Kemink JL, eds. *The Vestibular System: Neurophysiologic and Clinical Research*. New York, NY: Raven Press, 115–118.
- Hamid MA, Hughes GB, Kinney SE, Hanson MR. (1986) Results of sinusoidal harmonic acceleration test in one thousand patients: preliminary report. *Otolaryngol Head Neck Surg* 94(1):1–5.
- Halmagyi GM, Curthoys IS. (1988) A clinical sign of canal paresis. *Arch Neurol* 45(7):737–739.
- Harvey SA, Wood DJ, Feroah TR. (1997) Relationship of the head impulse test and head-shake nystagmus in reference to caloric testing. *Am J Otol* 18(2):207–213.

- Honrubia V, Jenkins HA, Baloh RW, Yee RD, Lau CG. (1984) Vestibulo-ocular reflexes in peripheral labyrinthine lesions: I. Unilateral dysfunction. *Am J Otolaryngol* 5(1):15–26.
- Huygen PL, Nicolaisen MG. (1985) Diagnostic value of velocity-step responses. *ORL J Otorhinolaryngol Relat Spec* 47(5):249–261.
- Iwasaki S, McGarvie LA, Halmagyi GM, et al. (2007) Head taps evoke a crossed vestibulo-ocular reflex. *Neurology* 68(15):1227–1229.
- King OS, Seidman SH, Leigh RJ. (1992) Control of head stability and gaze during locomotion in normal subjects and patients with deficient vestibular function. In Berthoz A, Graf W, Vidal PP, eds., *Second Symposium on Head-Neck Sensory-Motor System*. New York: Oxford (pp. 568–570).
- MacDougall HG, Curthoys IS. (2012) Plasticity during vestibular compensation: the role of saccades. *Front Neurol* 3:21.
- MacDougall HG, McGarvie LA, Halmagyi GM, Curthoys IS, Weber KP. (2013a) Application of the video head impulse test to detect vertical semicircular canal dysfunction. *Otol Neurotol* 34(6):974–979.
- MacDougall HG, McGarvie LA, Halmagyi GM, Curthoys IS, Weber KP. (2013b) The video Head Impulse Test (vHIT) detects vertical semicircular canal dysfunction. *PLoS ONE* 8(4):e61488.
- Mahringer A, Rambold HA. (2014) Caloric test and video-head-impulse: a study of vertigo/dizziness patients in a community hospital. *Eur Arch Otorhinolaryngol* 271(3):463–472.
- Mantokoudis G, Schubert MC, Tehrani AS, Wong AL, Agrawal Y. (2014) Early adaptation and compensation of clinical vestibular responses after unilateral vestibular deafferentation surgery. *Otol Neurotol* 35(1):148–154.
- Manzari L, Burgess AM, MacDougall HG, Curthoys IS. (2013) Vestibular function after vestibular neuritis. *Int J Audiol* 52(10):713–718.
- Matin E. (1974) Saccadic suppression: a review and an analysis. *Psychol Bull* 81(12):899–917.
- McCaslin DL, Jacobson GP, Bennett ML, Gruenwald JM, Green AP. (2014) Predictive properties of the video head impulse test: measures of caloric symmetry and self-report dizziness handicap. *Ear Hear* 35(5):e185–e191.
- Minor LB, Lasker DM, Backous DD, Hullar TE. (1999) Horizontal vestibuloocular reflex evoked by high-acceleration rotations in the squirrel monkey. I. Normal responses. *J Neurophysiol* 82(3):1254–1270.
- Murnane O, Mabrey H, Pearson A, Byrd S, Akin F. (2014) Normative data and test-retest reliability of the SYNAPSYS video head impulse test. *J Am Acad Audiol* 25(3):244–252.
- Pérez-Fernández N, Gallegos-Constantino V, Barona-Lleo L, Manrique-Huarte R. (2012) Clinical and video-assisted examination of the vestibulo-ocular reflex: a comparative study. *Acta Otorrinolaryngol Esp* 63(6):429–435.
- Perez N, Rama-Lopez J. (2003) Head-impulse and caloric tests in patients with dizziness. *Otol Neurotol* 24(6):913–917.
- Ramaioli C, Colagiorgio P, Sağlam M, Heuser F, Schneider E, Ramat S, Lehnen N. (2014) The effect of vestibulo-ocular reflex deficits and covert saccades on dynamic vision in opioid-induced vestibular dysfunction. *PLoS One* 9(10):e110322.
- Richards W. (1969) Saccadic suppression. *J Opt Soc Am* 59(5):617–623.
- Schmid-Priscovereanu A, Böhmer A, Obzina H, Straumann D. (2001) Caloric and search-coil head-impulse testing in patients after vestibular neuritis. *J Assoc Res Otolaryngol* 2(1):72–78.
- Schubert MC, Tusa RJ, Grine LE, Herdman SJ. (2004) Optimizing the sensitivity of the head thrust test for identifying vestibular hypofunction. *Phys Ther* 84(2):151–158.
- Ulmer E, Bernard-Demanze L, Lacour M. (2011) Statistical study of normal canal deficit variation range. Measurement using the Head Impulse Test video system. *Eur Ann Otorhinolaryngol Head Neck Dis*. 128(5):278–282.
- Weber KP, MacDougall HG, Halmagyi GM, Curthoys IS. (2009) Impulsive testing of semicircular-canal function using video-oculography. *Ann N Y Acad Sci* 1164:486–491.
- Whitney SL, Hudak MT, Marchetti GF. (2000) The dynamic gait index relates to self-reported fall history in individuals with vestibular dysfunction. *J Vestib Res* 10(2):99–105.