

# Umbilical Cord Blood Transplantation to Treat Pelizaeus-Merzbacher Disease in 2 Young Boys

**AUTHORS:** Jessica Wishnew, MD,<sup>a</sup> Kristin Page, MD,<sup>a</sup> Susan Wood, MN, C-PNP,<sup>a</sup> Leo Galvin, MD,<sup>b</sup> James Provenzale, MD,<sup>b</sup> Maria Escolar, MD, MS,<sup>c</sup> Kathryn Gustafson, PhD,<sup>d</sup> and Joanne Kurtzberg, MD<sup>a</sup>

<sup>a</sup>*Pediatric Blood and Marrow Transplant Program, <sup>b</sup>Division of Neuroradiology, and <sup>c</sup>Department of Psychiatry and Behavioral Sciences, Duke University Medical Center, Durham, North Carolina; and <sup>d</sup>Program for the Study of Neurodevelopment in Rare Disorders, University of Pittsburgh School of Medicine, Pittsburgh, Pennsylvania*

## KEY WORDS

Pelizaeus-Merzbacher disease, umbilical cord blood transplantation, hematopoietic stem cell transplantation, developmental delay, dysmyelination, hypomyelination

## ABBREVIATIONS

CNS—central nervous system  
DUMC—Duke University Medical Center  
GvHD—graft-versus-host disease  
PLP1—proteolipid protein 1 (gene)  
PMD—Pelizaeus-Merzbacher disease  
PNS—peripheral nervous system  
UCBT—umbilical cord blood transplantation

Dr Wishnew reviewed the patient information, drafted the initial manuscript, and constructed the tables and figures; Dr Page conceptualized the manuscript content and reviewed and revised the manuscript; Ms Wood gathered patient data and recorded patient data in the medical record; Dr Galvin assisted with the review and interpretation of the patients' MRI scans and helped construct the MRI portion of the manuscript and figures; Dr Provenzale selected the patients' MRI scans for review, assisted in the interpretation of the MRI scans, and reviewed the MRI portion of the manuscript and figures; Dr Escolar gathered patient data, recorded patient data in the medical record, and reviewed and revised the manuscript; Dr Gustafson gathered patient data and recorded patient data in the medical record; Dr Kurtzberg conceptualized the manuscript content and edited and critically reviewed the manuscript; and all authors approved the final manuscript as submitted.

[www.pediatrics.org/cgi/doi/10.1542/peds.2013-3604](http://www.pediatrics.org/cgi/doi/10.1542/peds.2013-3604)

doi:10.1542/peds.2013-3604

Accepted for publication Apr 1, 2014

Address correspondence to Jessica Wishnew, MD, Duke University Medical Center, Box 3850, 2400 Pratt St, Durham, NC 27710. E-mail: [jshnoo@gmail.com](mailto:jshnoo@gmail.com)

PEDIATRICS (ISSN Numbers: Print, 0031-4005; Online, 1098-4275).

Copyright © 2014 by the American Academy of Pediatrics

(Continued on last page)

## abstract

Pelizaeus-Merzbacher Disease (PMD) is a rare X-linked recessive leukodystrophy caused by mutations in the proteolipid protein 1 gene on the Xq22 chromosome. PMD is a dysmyelinating disorder characterized by variable clinical presentation and course. Symptoms range from mild motor deficits to progressive spasticity and neurologic decline resulting in death at an early age. There is no definitive curative treatment. This report presents the clinical course of 2 young boys with PMD who are the first known patients to receive umbilical cord blood transplantation as a therapeutic intervention to stabilize disease progression. Pretransplantation evaluation revealed that both patients had significant motor deficits as well as delayed cognitive function as compared with age-matched peers. Brain imaging revealed varying degrees of hypomyelination. Both patients received myeloablative chemotherapy followed by an unrelated donor umbilical cord blood infusion, which they tolerated well with no major transplantation-related complications. At 7-years and 1-year posttransplantation, respectively, both boys are making slow neurocognitive improvements and show no evidence of functional decline. Imaging results show stable or improving myelination. Although the results of unrelated donor umbilical cord blood transplantation in these 2 boys with PMD are encouraging, longer-term follow-up will be necessary to assess the effect of this treatment on the variable natural disease course. *Pediatrics* 2014;134:e1451–e1457

**TABLE 1** Patient Characteristics

Patient	Gender	Age at Transplantation, mo	Weight at Transplantation, kg	Blood Type	Clinical Trial	Type of <i>PLP1</i> Mutation	<i>PLP1</i> Gene Mutation	<i>PLP1</i> Mutation Description
1	Male	9	8.6	O+	Yes <sup>a</sup>	Duplication	[46,XY,nuc ish dup (x)(q22q22)(PLP1x2)[50]]	FISH duplication pattern was seen in > 70% of the interphase cells.
2	Male	29	13.1	O-	No	Aberrant splicing	[c.697-54_711delinsTTTATT]	Deletion extended from base 54 in intron 5 through base 711 in exon 6. The sequence inserted at the deletion junction (TTTATT) was the same sequence as bases 715_720 of exon 6 that was not deleted. The splice acceptor site at exon 6 is within the deleted region, functionally leading to aberrant splicing of <i>PLP1</i> .

FISH, fluorescence in situ hybridization.

<sup>a</sup> A pilot trial of unrelated UCBT augmented with ex vivo cytokine primed aldehyde dehydrogenase bright (ALDH<sup>br</sup>) umbilical cord blood cells (sponsored by Aldagen [Durham, NC]; Biological Investigational New Drug 12289).

Pelizaeus-Merzbacher disease (PMD) is a rare, progressive leukodystrophy caused by mutations in the proteolipid protein 1 (*PLP1*) gene leading to dysmyelination in the central and peripheral nervous systems (CNS and PNS, respectively). Severe disease is associated with death in the first decade of life, whereas milder forms show slower progression. No formal natural history studies have been conducted to date, and no effective curative treatment has been described.

Umbilical cord blood transplantation (UCBT) has been successfully used to treat certain life-threatening inherited metabolic diseases, mostly lysosomal and peroxisomal storage disorders.<sup>1</sup> Disease stabilization may be mediated through engrafting donor cells that become a source of enzyme replacement therapy. When performed early in the disease process, UCBT can stabilize disease progression. This effect has been observed in selected diseases (eg, adrenoleukodystrophy) in which

enzyme replacement is not the mechanism through which UCBT favorably alters the natural history of the disease.<sup>2–5</sup> Although the mechanisms underlying the benefit of UCBT in these diseases is not fully understood, we hypothesized that disease stabilization occurs through engraftment of donor cells in the brain, benefitting children with other types of demyelinating diseases. In this report, we describe the first 2 patients treated with UCBT for PMD.

## METHODS

### Patients

Families were self-referred to Duke University Medical Center (DUMC), and parents provided written informed consent before treatment. Patient 1 was enrolled in an Investigational New Drug-sponsored clinical trial, testing whether engraftment could be accelerated by infusion of aldehyde dehydrogenase cells primed with hematopoietic cytokines

before transplantation.<sup>6</sup> Both patients were enrolled in the Center for International Blood and Marrow Transplant Research outcomes database, the federally mandated research database created as part of the C.W. Bill Young Cell Transplantation Program.<sup>7</sup> The DUMC Institutional Review Board approved both studies. Patient 1 was included in a previous report.<sup>1</sup>

### Genetic Testing

Patients underwent molecular diagnostic testing to confirm PMD diagnosis and to determine *PLP1* mutation (Table 1).

### Neurophysiologic and Neurodevelopmental Evaluation

Neurophysiologic studies and imaging evaluated CNS and PNS function pre- and posttransplantation. Standardized neurodevelopmental tools were used to assess neurocognitive and developmental milestones pre- and posttransplantation (Tables 2 and 3).

**TABLE 2** Neurophysiologic Evaluation Pre- and Posttransplantation

Neurophysiologic Evaluation	Patient 1		Patient 2	
	Baseline Pretransplantation (7 Months Old)	Most Recent Follow-up (60–72 Months Old)	Baseline Pretransplantation (28 Months Old)	Most Recent Follow-up (41–44 Months Old)
EEG	Normal	Stable	Normal	Worsening
Electromyography	Abnormal	Stable	Normal	Worsening
Brainstem auditory evoked potential	Abnormal	Worsening	Abnormal	Stable
Visual evoked potential	Normal	Stable	Abnormal	Improving
Otoacoustic emissions	Abnormal	Not done	Normal	Not done

**TABLE 3** Neurocognitive Evaluation Pre- and Posttransplantation

Neurocognitive Evaluation <sup>a</sup>	Patient 1		Patient 2	
	Baseline Pretransplantation (8 Months)	Most Recent Follow-up (82 Months)	Baseline Pre-transplantation (25 Months)	Most Recent Follow-up (41 Months)
Cognitive scale	6.85 <sup>b</sup>	—	18	30
Visual reception	7	46	—	—
Language scale				
Receptive	7	28	20	30
Expressive	8	—	17	25
Motor scale				
Fine	6	15	18	31
Gross	4	See text	7	9

Data are presented as age equivalents in months.

<sup>a</sup> Patient 1 was evaluated by using Mullen Scales of Early Learning—American Guidance Services, Inc. Edition, except as noted; Patient 2 was evaluated by using Bayley Scales of Infant and Toddler Development—III.

<sup>b</sup> Patient development was measured using the Capute scales: CAT/CLAMS (Cognitive Adaptive Test/Clinical Linguistic and Auditory Milestone Scale).

### Transplant Evaluation and Procedure

Diagnostic testing assessed major organ function pre- and posttransplantation as previously described.<sup>1</sup> Patients received myeloablative transplant conditioning with busulfan, cyclophosphamide, and antithymocyte globulin.<sup>1</sup> One day after completing chemotherapy, they received an infusion of a 5/6 HLA antigen-matched, unrelated umbilical cord blood unit, thawed and washed in dextran/albumin before infusion.<sup>8</sup> Graft-versus-host disease (GvHD) prophylaxis and supportive care measures were followed as previously described.<sup>1,2</sup>

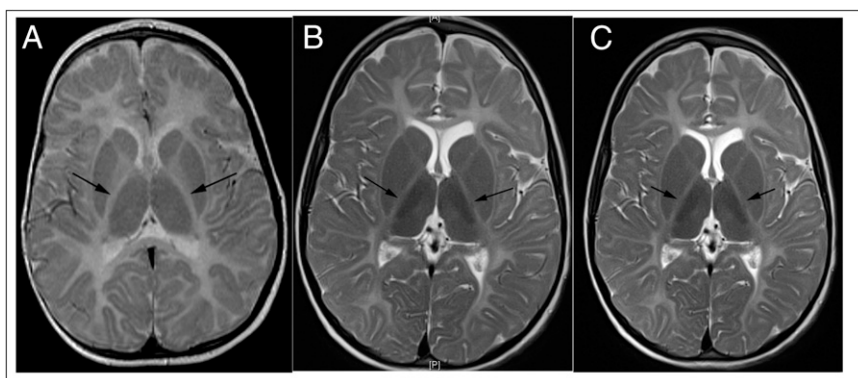
### RESULTS

Patient 1 is a multiracial male born at term after an uncomplicated pregnancy.

He is an only child with no significant family history. Shortly after birth, he developed mild arm tremors, which could be extinguished when held. At 1 month of age, he had head bobbing; bilateral, high-frequency, pendular horizontal nystagmus; choreiform movements; and a brisk startle response. At 3 months of age he had an abnormal EEG with fast rhythmic activity in the central region and parietal/temporal sharp waves during sleep; an MRI at 7 months of age revealed findings indicative of poor myelination for age (Fig 1). Testing confirmed the PMD diagnosis (Table 1). Because of progressive symptoms his parents requested a consultation for UCBT. The team at DUMC evaluated him at 8 months of age and agreed to perform the procedure.

After myeloablative chemotherapy, he underwent UCBT at 9 months of age (Table 4). He engrafted on day +17 after cord blood infusion. He subsequently developed grade 2 acute skin GvHD followed by mild chronic skin GvHD. He developed autoimmune hemolytic anemia and thrombocytopenia at 7 months posttransplantation, which was treated with corticosteroids, rituximab, and azathioprine. He had a gastrostomy tube placed 1 year posttransplantation; it was removed 9 months later because oral intake had improved. Adrenal insufficiency, due to long-term corticosteroid use, was treated with physiologic hydrocortisone replacement until 2.5 years posttransplantation. His chronic medical issues currently include gastroesophageal reflux, recurrent otitis media with myringotomy tube placement, cholelithiasis, and nearsightedness. He is currently 7 years posttransplantation, durably engrafted with >98% donor cells, and has discontinued immunosuppressive medications with normal immune reconstitution.

Patient 2 is a white male born at term by cesarean delivery with a nuchal cord at delivery. At 4 months old, he had rotary and pendular, disconjugate nystagmus, with amblyopia. At 6.5 to 7.5 months old he was found to be hypotonic with gross motor deficits. An MRI at 9 months old was reportedly normal, but delayed myelination was noted retrospectively.

**FIGURE 1**

MRI images (T2-weighted) from patient 1. A, Pretransplantation at 7 months of age; B, posttransplantation at 19 months of age; C, posttransplantation at 69 months of age. A, Increased signal intensity within posterior limbs of internal capsule (arrows) indicates abnormal myelination. Normally, the entire posterior limb of internal capsule would have dark signal, indicative of myelination. B, Development of small foci of dark signal in internal capsule consistent with mild interval myelination. C, Stable myelination.

**TABLE 4** Cord Blood Unit Characteristics

Patient	Cord Blood Donor		HLA Antigen Match <sup>a</sup>	Total Nucleated Cell Count, ×10 <sup>7</sup> Cells/kg		CD34 <sup>+</sup> Cell Count, ×10 <sup>5</sup> Cells/kg
	Blood type	Gender		Cryopreserved	Post-Thaw	
1	A+	Male	5/6	11.1	10.3	1.7
2	O+	Male	5/6	8.5	6.1	1.1

<sup>a</sup> HLA matching using intermediate resolution typing for class I (loci A and B) and high-resolution typing for class II (DR Beta1).

At 16 months old he had intermittent nystagmus, bilateral facial weakness, truncal hypotonia, upper extremity weakness, and hypertonia with dystonic posturing in his extremities. Genetic testing confirmed PMD (Table 1). His parents requested consultation for UCBT at DUMC, and his transplantation was performed after myeloablative conditioning at the age of 29 months (Table 4). He engrafted on day +23 after cord blood infusion. He subsequently experienced mild, grade 1 acute skin GvHD. He required physiologic hydrocortisone replacement until 1 year posttransplantation. At 14 months posttransplantation, he remains durably engrafted with >98% donor cells and has discontinued immunosuppression, with normal immune function.

### Neurocognitive and Motor Function Outcomes

Both patients showed significant gains posttransplantation in cognitive function, although motor function has lagged behind (Table 3). Head circumference in both boys remained normal for age. At the time of last follow-up at 7 years of age, patient 1 showed delayed development, with fine motor skills equivalent to those of a 15-month-old. His level of independence (based on a parental evaluation using the Scales of Independent Behavior–Revised Full-Scale Form) was equivalent to that of a 21-month-old, whereas his visual reception was equivalent to that of a 46-month-old. Gross motor skill age equivalents based on the

Peabody Developmental Motor Skills–Second Edition scale included the following: reflexes, 5 months; stationary, 11 months; locomotion, 9 months; and object manipulation, 13 months. Neurologic examination revealed cerebellar ataxia and tremor, choreoathetosis, proximal extremity weakness, and dystonic posturing. He attends third grade, mainstreamed in a typical class with special education support.

At 1-year posttransplantation, patient 2 uses a stander and a reverse walker and wears lower extremity braces. He has excellent upper extremity function. Testing at 41 months of age revealed cognitive function at an approximate age equivalence of a 30-month-old, but substantial delay in motor function (estimated age equivalence of a 9- to 11-month-old). He receives Early Intervention services including speech, occupational, and physical therapy.

### MRI Evaluation

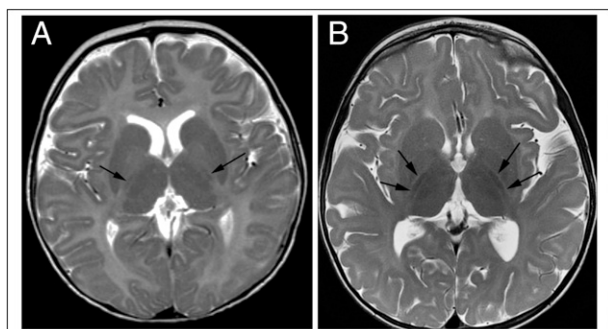
Both patients displayed decreased myelination, measured by fractional anisotropy on diffusion tensor imaging, on pretransplantation MRI evaluation, with altered signal intensity within the brainstem and deep white matter (Table 5). In patient 1, imaging at age 7 months showed abnormal myelination for age (Fig 1). On posttransplantation imaging at 19 months of age, myelination had improved. MRI at age 69 months showed stable myelination compared with the previous posttransplantation imaging.

Diagnostic imaging of patient 2 at 9 months of age showed a moderate decrease in myelination for age (Fig 2). He showed interval myelination between his 9-month MRI and his pretransplantation MRI at 25 months old. On his posttransplantation images at age 42 months, his MRI revealed an interval increase in myelination.

### DISCUSSION

In this report, we describe the clinical outcomes after UCBT of 2 young boys with severe phenotype PMD. Both patients tolerated the procedure well without major posttransplantation complications and remain durably engrafted with donor cells. Both continue to gain cognitive skills, but remain impaired compared with age-matched peers. Brain MRI revealed sustained interval improvement in myelination posttransplantation, although overall myelination remained less than expected for chronological age. Motor function improved to a greater extent in patient 2 as compared with patient 1. This finding may be due, in part, to the fact that patient 1 had a more severe disease presentation with extensive involuntary movements further impairing motor function.

PMD is a leukodystrophy usually inherited in an X-linked recessive pattern with an estimated prevalence of 1 in 200 000 to 500 000 live male births. The natural history is highly variable, and there is no known curative treatment of PMD.<sup>9</sup> Gupta et al<sup>10</sup> recently published the results of a phase 1 study

**FIGURE 2**

MRI images (T2-weighted) from patient 2. A, Pretransplantation at 9 months of age; B, posttransplantation at 42 months of age. A, The arrows indicate foci of hypointense signal in posterior limbs of internal capsule indicating decreased myelination for age. Normally, the entire posterior limb of internal capsule would be expected to have dark signal at birth. B, The arrows indicate additional decrease in signal intensity in posterior limbs of internal capsule, consistent with interval myelination.

investigating the safety and efficacy of intracranial injections of fetus-derived neural stem cells in 4 young boys with PMD. They showed a favorable safety profile and suggested that cell engraftment and donor-derived

myelination occurred in the transplanted host white matter. UCBT after myeloablative chemotherapy has been used to treat > 500 children with inherited metabolic diseases around the world in the last decade. In general,

in children with early-stage disease, the procedure is well tolerated and overall survival ranges between 80% and 90%. Donor stem cell engraftment is durable, and in diseases with enzyme deficiencies, enzyme levels normalize in the blood. Favorable effects on clinical disease have been seen in patients with mucopolysaccharidosis 1, adrenoleukodystrophy, juvenile metachromatic leukodystrophy, and selected patients with Krabbe disease.<sup>1–5</sup>

In congenital PMD, the most severe form of the disease, infants present in the perinatal period with nystagmus, stridor, and hypotonia, and die in the first decade of life. Other manifestations include the following: nonepileptic seizures, microcephaly, weak cry, difficulty sucking, titubation, and poor muscle reflexes.<sup>11</sup> Classic PMD presents with nystagmus at 2 to 6 months of age.

**TABLE 5** Comparison of Pre- and Posttransplantation MRI Results

Patient	T2 Imaging		DTI	
	Pretransplantation	Posttransplantation	Pretransplantation	Posttransplantation
1	MRI at age 7 months showed abnormal hyperintense signal on T2-weighted and FLAIR images within the brainstem, both posterior limbs of internal capsules, and the centrum semiovale, reflecting abnormal myelination.	Imaging at 19 months old showing signal intensity in the brainstem and internal capsules was normal, reflecting interval myelination.	Imaging at 7 months of age showed a 33% decrease in FA (a correlate of white matter development) in the posterior limb of internal capsule.	DTI at 22 months old showed that FA values in the posterior limb of internal capsule had increased on the order of 65%, consistent with myelination. Despite these advances, FA values remained ~25% decreased relative to unaffected age-matched subjects in this structure. Substantial increases in FA values were also seen in the anterior corona radiata (14%), posterior corona radiata (23%), corticospinal tracts (11%), and anterior limb of internal capsule (10%).
2	MRI at 9 months old showed only subtle hypointense signal on T2-weighted images in brainstem, posterior limbs of internal capsules, and corona radiata; normal myelination at this age would be associated with much darker signal intensity. These findings are consistent with a moderate decrease in the degree of myelination. There was interval myelination between MRI at 9 months old and immediate pretransplantation MRI at 25 months old.	The T2-weighted images at age 42 months showed substantial decreases in signal intensity in the ventral pons and posterior limbs of internal capsules, consistent with interval increased myelination.	Not obtained	Not obtained

DTI, diffusion tensor imaging; FA, fractional anisotropy; FLAIR, fluid attenuated inversion recovery.

Later in childhood, delays in motor and speech development, ataxia, and hypotonia are observed. Children slowly deteriorate over the first few decades of life and die as young adults.

The *PLP1* gene normally undergoes alternative splicing to produce 2 proteins, PLP1 and DM20, which stabilize and maintain the myelin sheath along CNS and PNS axons. They also play a role in proper development of oligodendrocyte precursors.<sup>11</sup> Duplications of the *PLP1* gene, as seen in patient 1 in this report, are present in 50% to 75% of patients with PMD and are associated with the most severe forms of clinical disease. Increased *PLP1* gene expression portends a worse clinical outcome; the greater number of gene copies, the more severe the phenotype.<sup>12</sup> Point mutations in the *PLP1* gene account for 15% to 20% of PMD cases and result in production of a prematurely terminated protein, which is toxic to the oligodendrocyte,

causing dysmyelination.<sup>13</sup> Splicing mutations alter relative expression of PLP1 and DM20 protein and lead to variable phenotypes.<sup>14</sup> Patient 2 in our study has a mutation in exon 6, yielding a splicing variant, and has a less severe phenotype than patient 1. Null mutations may lead to an even milder clinical phenotype with moderate spastic quadriplegia, mild cognitive delay, ataxia, and peripheral neuropathy.<sup>14</sup>

PMD is associated with dysmyelination and cortical atrophy on MRI.<sup>15</sup> White matter atrophy has been reported on postmortem brain examination.<sup>16</sup> Both of our patients showed improvement or stabilization of myelination posttransplantation at 7-years and 1-year, respectively, albeit not at the rate seen in a normal child. Natural history studies of radiographic changes in patients with PMD are lacking. However, one would expect disease progression to be associated with slow loss of myelin and subsequent white matter atrophy; hence,

the absence of these findings suggests a beneficial effect, stopping or slowing disease progression after UCBT.

## CONCLUSIONS

We report the results of UCBT in 2 boys with moderate-to-severe PMD. Both boys tolerated transplantation well, including exposure to myeloablative chemotherapy. With 7-year and 1-year follow-up, they showed stabilization of disease with significant gains in cognitive skills and modest gains in motor development. MRI results suggest interval myelination, which is encouraging. Longer-term follow-up is needed to fully assess the effects of UCBT on the course of PMD in these 2 patients. The interpretation of our results is complicated by the lack of formal natural history studies and variability of the clinical course in this rare disease. We will continue to follow our patients to confirm these preliminary observations.

## REFERENCES

1. Prasad VK, Mendizabal A, Parikh SH, et al. Unrelated donor umbilical cord blood transplantation for inherited metabolic disorders in 159 pediatric patients from a single center: influence of cellular composition of the graft on transplantation outcomes. *Blood*. 2008;112(7):2979–2989
2. Staba SL, Escolar ML, Poe M, et al. Cord-blood transplants from unrelated donors in patients with Hurler's syndrome. *N Engl J Med*. 2004;350(19):1960–1969
3. Martin HR, Poe MD, Provenzale JM, Kurtzberg J, Mendizabal A, Escolar ML. Neurodevelopmental outcomes of umbilical cord blood transplantation in metachromatic leukodystrophy. *Biol Blood Marrow Transplant*. 2013;19(4):616–624
4. Escolar ML, Poe MD, Provenzale JM, et al. Transplantation of umbilical-cord blood in babies with infantile Krabbe's disease. *N Engl J Med*. 2005;352(20):2069–2081
5. Beam D, Poe MD, Provenzale JM, et al. Outcomes of unrelated umbilical cord blood transplantation for X-linked adrenoleukodystrophy. *Biol Blood Marrow Transplant*. 2007;13(6):665–674
6. Kurtzberg J MA, Carter S, Reese M, et al. Augmentation of standard umbilical cord blood transplantation with ALDHbr cells: results of a phase I study in pediatric patients [abstract 64]. *Biol Blood Marrow Transplant*. 2008:abst. 64, page 41
7. US Department of Health and Human Services, Health Resources and Services Administration. HRSA Web site. Available at: [www.hrsa.gov/index.html](http://www.hrsa.gov/index.html). Website accessed April 2, 2014
8. Rubinstein P, Dobrila L, Rosenfield RE, et al. Processing and cryopreservation of placental/umbilical cord blood for unrelated bone marrow reconstitution. *Proc Natl Acad Sci USA*. 1995;92(22):10119–10122
9. Hobson GM, Garbern JY. Pelizaeus-Merzbacher disease, Pelizaeus-Merzbacher-like disease 1, and related hypomyelinating disorders. *Semin Neurol*. 2012;32(1):62–67
10. Gupta N, Henry RG, Strober J, et al. Neural stem cell engraftment and myelination in the human brain. *Sci Transl Med*. 2012;4(155):155ra137
11. Inoue K. PLP1-related inherited dysmyelinating disorders: Pelizaeus-Merzbacher disease and spastic paraplegia type 2. *Neurogenetics*. 2005;6(1):1–16
12. Wolf NI, Sistermans EA, Cundall M, et al. Three or more copies of the proteolipid protein gene *PLP1* cause severe Pelizaeus-Merzbacher disease. *Brain*. 2005;128(pt 4):743–751

13. Garbern J, Cambi F, Shy M, Kamholz J. The molecular pathogenesis of Pelizaeus-Merzbacher disease. *Arch Neurol*. 1999;56(10):1210–1214
14. Lassuthova P, Zaliova M, Inoue K, et al. Three new PLP1 splicing mutations demonstrate pathogenic and phenotypic diversity of Pelizaeus-Merzbacher disease. *J Child Neurol*. Epub 2013
15. Cailloux F, Gauthier-Barichard F, Mimault C, et al; Clinical European Network on Brain Demyelinating Disease. Genotype-phenotype correlation in inherited brain myelination defects due to proteolipid protein gene mutations. *Eur J Hum Genet*. 2000;8(11):837–845
16. Sima AA, Pierson CR, Woltjer RL, et al. Neuronal loss in Pelizaeus-Merzbacher disease differs in various mutations of the proteolipid protein 1. *Acta Neuropathol*. 2009;118(4):531–539

---

(Continued from first page)

**FINANCIAL DISCLOSURE:** Dr Kurtzberg is the medical director of the CORD:USE Cord Blood Bank and the director of the Carolinas Cord Blood Bank. She holds a consultancy position as the National Marrow Donor Program Medical Advisor Co-Chair, part of the Cord Blood Working Group and has a grant through the Health Resources and Services Administration Cord Blood Public Banking Contract. The other authors have indicated they have no financial relationships relevant to this article to disclose.

**FUNDING:** No external funding.

**POTENTIAL CONFLICT OF INTEREST:** The authors have indicated they have no potential conflicts of interest to disclose.

## Umbilical Cord Blood Transplantation to Treat Pelizaeus-Merzbacher Disease in 2 Young Boys

Jessica Wishnew, Kristin Page, Susan Wood, Leo Galvin, James Provenzale, Maria Escolar, Kathryn Gustafson and Joanne Kurtzberg

*Pediatrics* 2014;134:e1451

DOI: 10.1542/peds.2013-3604 originally published online October 6, 2014;

### Updated Information & Services

including high resolution figures, can be found at:  
<http://pediatrics.aappublications.org/content/134/5/e1451>

### References

This article cites 12 articles, 2 of which you can access for free at:  
<http://pediatrics.aappublications.org/content/134/5/e1451.full#ref-list-1>

### Permissions & Licensing

Information about reproducing this article in parts (figures, tables) or in its entirety can be found online at:  
<https://shop.aap.org/licensing-permissions/>

### Reprints

Information about ordering reprints can be found online:  
<http://classic.pediatrics.aappublications.org/content/reprints>

Pediatrics is the official journal of the American Academy of Pediatrics. A monthly publication, it has been published continuously since . Pediatrics is owned, published, and trademarked by the American Academy of Pediatrics, 141 Northwest Point Boulevard, Elk Grove Village, Illinois, 60007. Copyright © 2014 by the American Academy of Pediatrics. All rights reserved. Print ISSN: .

American Academy of Pediatrics

DEDICATED TO THE HEALTH OF ALL CHILDREN™





# PEDIATRICS®

OFFICIAL JOURNAL OF THE AMERICAN ACADEMY OF PEDIATRICS

## **Umbilical Cord Blood Transplantation to Treat Pelizaeus-Merzbacher Disease in 2 Young Boys**

Jessica Wishnew, Kristin Page, Susan Wood, Leo Galvin, James Provenzale, Maria  
Escolar, Kathryn Gustafson and Joanne Kurtzberg

*Pediatrics* 2014;134:e1451

DOI: 10.1542/peds.2013-3604 originally published online October 6, 2014;

The online version of this article, along with updated information and services, is  
located on the World Wide Web at:

<http://pediatrics.aappublications.org/content/134/5/e1451>

Pediatrics is the official journal of the American Academy of Pediatrics. A monthly publication, it has been published continuously since . Pediatrics is owned, published, and trademarked by the American Academy of Pediatrics, 141 Northwest Point Boulevard, Elk Grove Village, Illinois, 60007. Copyright © 2014 by the American Academy of Pediatrics. All rights reserved. Print ISSN: .

American Academy of Pediatrics

DEDICATED TO THE HEALTH OF ALL CHILDREN™

