



## Case report

## Solitary mastocytoma in the eyelid of an adult

Elizabeth L. McKinnon, Andrew J. Rand<sup>1</sup>, Alan D. Proia\*

Department of Pathology, Duke University Medical Center, Durham, NC 27710, USA



## ARTICLE INFO

## Keywords:

Eyelid  
Mast cell  
Mastocytosis  
Mastocytoma  
Tumor

## ABSTRACT

**Purpose:** To describe the ophthalmic symptoms and histopathological findings in a rare case of an eyelid mastocytoma in an adult.

**Observations:** A man in his early 60s developed a painless, non-tender, non-pruritic, mobile nodule on the right lower eyelid beneath the inferior orbital rim. The lesion grew to 15 × 9 mm over eleven months. Biopsy revealed a diffuse infiltrate of histiocytoid and spindle-shaped mast cells forming cords and small nests between collagen fibers in the superficial and deep dermis. Mast cell lineage was confirmed by immunohistochemistry. Physical examination revealed no other cutaneous lesions and no evidence of systemic disease. Serum tryptase level was normal. Annual full-body examination by a dermatologist for 4.5 years has revealed neither recurrence in the eyelid nor cutaneous involvement at other sites.

**Conclusions and importance:** Mast cell tumors limited to the human eyelid are extremely uncommon with only four previously reported cases, including one in an adult. This case highlights the rare possibility of a solitary mastocytoma presenting in the eyelid of an adult.

## 1. Introduction

Mastocytosis is a neoplastic proliferation of mast cells that can present in the skin with or without systemic disease.<sup>1–3</sup> It is sub-classified according to microscopic and clinical features, including sites of involvement and clinical behavior.<sup>1–3</sup> Clinical variants include cutaneous mastocytosis; indolent systemic mastocytosis; systemic mastocytosis with associated clonal hematological non-mast-cell lineage disease; aggressive systemic mastocytosis; mast cell leukemia; mast cell sarcoma; and extracutaneous mastocytoma.<sup>1–3</sup>

Mastocytosis may involve any tissue in the body. The bone marrow is almost always involved in systemic mastocytosis, and it is biopsied to fully establish the diagnosis.<sup>1,2</sup> Systemic mastocytosis may also be found in the lymph nodes, spleen, liver, and gastrointestinal tract mucosa.<sup>2</sup> Mast cell sarcoma is extremely rare and has occurred in the larynx, large intestine, meninges, bone, and skin.<sup>2</sup> More than 50% of patients with systemic mastocytosis, and approximately 80% of patients with mastocytosis of any kind, have cutaneous lesions.<sup>2</sup> Skin lesions in patients with systemic mastocytosis usually portend a more indolent clinical course.<sup>2</sup>

The diagnosis of cutaneous mastocytosis requires appropriate clinical findings, histological proof of an abnormal mast cell infiltrate in the dermis, and insufficient features to diagnose systemic mastocytosis such as elevated serum tryptase or organomegaly.<sup>2</sup> There are three major

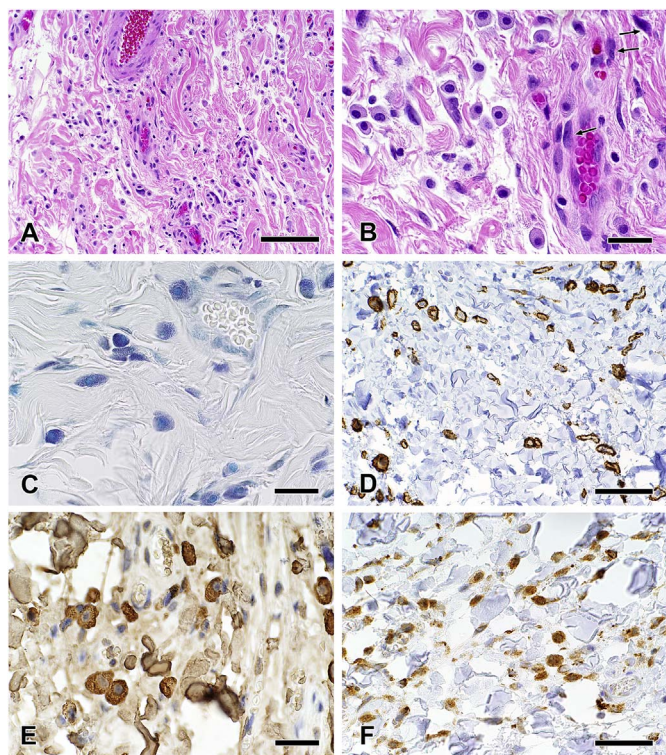
variants of cutaneous mastocytosis: urticaria pigmentosa/maculopapular cutaneous mastocytosis, the most common variant; diffuse cutaneous mastocytosis; and solitary mastocytoma of skin.<sup>2,3</sup>

Cutaneous mastocytosis is described most often in children<sup>1,4</sup> and only rarely in adults.<sup>5</sup> Solitary mastocytoma of skin occurs almost exclusively in infants, with no predominant site.<sup>2,3,6</sup> Interestingly, mast cell tumors are very common in the skin of cats,<sup>7</sup> and they occur frequently in feline eyelids<sup>8</sup> and the periocular region.<sup>9</sup> In a study of eyelid tumors from 43 cats, there were 12 squamous cell carcinomas and 11 mast cell tumors.<sup>8</sup> In contrast to the cat, mastocytomas are rare in the human eyelid with only four reported cases.<sup>4,10–12</sup> The first case, reported in 1987, was a 10 mm in diameter solitary mastocytoma in the right lower eyelid of a 4-month-old boy that was present since birth.<sup>12</sup> A second child presented with recurrent eyelid edema.<sup>4</sup> Most recently, a 2-month-old boy presented with a 7 × 3 mm lesion that caused occasional swelling.<sup>11</sup> Our review of the literature uncovered only one example of solitary mastocytoma in the eyelid of an adult: a 56-year-old man with prolidase deficiency.<sup>10</sup> No cases of mastocytosis were reported in three large series of eyelid tumors.<sup>13–15</sup> We report the fifth case of solitary mastocytoma in the human eyelid and only the second in an adult.

\* Corresponding author. Duke University Medical Center, Department of Pathology, DUMC 3712, Durham, NC, 27710, USA.

E-mail address: [alan.proia@duke.edu](mailto:alan.proia@duke.edu) (A.D. Proia).

<sup>1</sup> Current address: St. Anthony's Hospital, Saint Petersburg, FL 33705, USA.



**Fig. 1.** Histopathology of solitary mastocytoma of the eyelid. **A.** The dermis contained an infiltrate of histiocytoid-appearing mast cells mostly forming cords between collagen bundles (hematoxylin & eosin; bar = 100  $\mu\text{m}$ ). **B.** The mast cells were mostly round to oval with round nuclei and finely granular cytoplasm, though some were spindle-shaped (examples at arrows) with oval nuclei and granular cytoplasm (hematoxylin & eosin; bar = 25  $\mu\text{m}$ ). **C.** Mast cell granules were highlighted in both the histiocytoid and spindle-shaped cells using toluidine blue (bar = 25  $\mu\text{m}$ ). **D.** The histiocytoid and spindle-shaped mast cells exhibited membrane staining using antibodies to CD117 (monoclonal mouse anti-human CD117, clone 104D2 [Agilent Technologies, Carpinteria, CA]; bar = 50  $\mu\text{m}$ ). **E.** The mast cell granules stained intensely using antibodies to mast cell tryptase. The light staining of the collagen may represent bound tryptase released from the mast cells (monoclonal mouse anti-human mast cell tryptase, clone AA1 [Agilent]; bar = 25  $\mu\text{m}$ ). **F.** CD68 antibodies stained the mast cell granules (monoclonal mouse anti-human CD68, clone KP1 [Agilent]; bar = 50  $\mu\text{m}$ ).

## 2. Case report

A man in his early 60s presented with a painless, non-tender, non-pruritic, mobile nodule on the right lower eyelid below the inferior orbital rim. The lesion grew to 15  $\times$  9 mm over eleven months. There was no antecedent trauma (including insect bite), infection, or neoplasm at this location and no history of atopic dermatitis. Physical examination revealed no other cutaneous lesions and no evidence of systemic disease. Serum tryptase level was within normal limits (5.3 ng/mL; normal < 11.5 ng/mL), and a complete blood count with differential was remarkable only for mild anemia. Annual full-body examination by a dermatologist for five years has revealed neither recurrence in the eyelid nor cutaneous involvement at other sites.

An excisional biopsy revealed a diffuse interstitial infiltrate of histiocytoid cells forming cords and small nests between collagen fibers in the dermis (Fig. 1A). The histiocytoid cells had round nuclei with occasional small nucleoli and a moderate amount of finely granular, amphophilic cytoplasm (Fig. 1B). Scattered among the collagen fibers and histiocytoid cells were distinct spindle-shaped cells with larger, more pleomorphic nuclei and a small to moderate amount of amphophilic cytoplasm with fewer apparent granules (Fig. 1B). Toluidine blue stain highlighted innumerable minute granules in the cytoplasm of both the histiocytoid and spindle-shaped cells (Fig. 1C). The cells expressed CD117 on their cell membrane (Fig. 1D) and mast cell tryptase (Fig. 1E) and CD68 in their granules (Fig. 1F). Immunostains highlighted greater

than 20 mast cells per high power field (x40). Rare mast cells (< 1%) expressed CD25. The epidermis was not hyperpigmented nor was there significant telangiectasia.

## 3. Discussion

The dense dermal infiltrate of mast cells forming a clinically apparent nodule, the absence of an antecedent inciting stimulus, and the normal serum tryptase level established the diagnosis of cutaneous mastocytosis.<sup>16</sup> There was insufficient clinical suspicion for systemic disease to warrant a bone marrow biopsy since the serum tryptase level was normal. Mast cell sarcoma was excluded because the mast cells showed neither severe cytological atypia nor a destructive growth pattern.<sup>2</sup> Among the three major variants of cutaneous mastocytosis,<sup>1–3</sup> this lesion is best classified as a solitary mastocytoma because it was singular with a diameter greater than 1 cm. Mastocytomas, also known as nodular cutaneous mastocytosis,<sup>6</sup> typically have sheets of mast cells filling the papillary and reticular dermis and sometimes extending subcutaneously.<sup>2,3</sup> Our patient exhibited an interstitial pattern with mast cells mostly forming cords between dermal collagen bundles. The interstitial pattern is usually seen in patients with urticaria pigmentosa/maculopapular cutaneous mastocytosis<sup>6</sup> and has not been reported, to our knowledge, in a solitary mastocytoma. Thus, our patient with a solitary mastocytoma is peculiar both because of his age and the histological pattern of the mast cell infiltrate.

Immunohistochemistry may be a useful adjunct to confirm the diagnosis of mastocytosis, which requires  $\geq 15$  mast cells in aggregates<sup>2</sup> or > 20 cells per high power (x40) field.<sup>16</sup> Normal mast cells express CD117 and mast cell tryptase, as well as CD9, CD33, CD45, and CD68.<sup>2</sup> They do not express the myelomonocytic antigens CD14, CD15, and CD16, as well as most T- and B-cell related antigens.<sup>2</sup> Chymase is highly specific but not very sensitive for identifying atypical and immature mast cells.<sup>2</sup> In the eyelid, immunostains may be particularly useful for distinguishing mastocytosis from primary signet-ring cell/histiocytoid carcinoma, which has a predilection for the eyelids.<sup>17</sup> Neoplastic mast cells are immunophenotypically similar to normal mast cells but co-express CD2 or CD2 and CD25.<sup>2</sup> Membrane expression of CD25 on cutaneous mast cells in adults may be predictive of systemic mastocytosis,<sup>18</sup> but a consensus threshold for a positive result remains to be established. In one recent study, the percentage of cutaneous mast cells expressing CD25 ranged from 2% to 75% in adults with systemic mastocytosis with compact mast cell infiltrates.<sup>5</sup> The two adults with isolated cutaneous mastocytosis in that study had no CD25<sup>+</sup> mast cells in their biopsy.<sup>5</sup> In our patient, the significance of the rare CD25<sup>+</sup> mast cells (< 1%) is uncertain given that the serum tryptase level was normal and there have been no other signs or symptoms of systemic mastocytosis during 4.5 years of clinical follow-up.

The prognosis for patients with mastocytosis varies widely with disease type. Patients with mast cell sarcoma and mast cell leukemia usually progress rapidly and die within months.<sup>1</sup> In contrast, cutaneous mastocytosis in pediatric populations has an excellent prognosis, and lesions may regress spontaneously before or during puberty.<sup>1,4</sup> Adult-onset cutaneous lesions have a good prognosis but generally do not regress, and they are often associated with indolent systemic mastocytosis.<sup>1,5</sup> Systemic mastocytosis has a better prognosis when cutaneous lesions are identified.<sup>1,2</sup> There is no cure for systemic mastocytosis; patients with aggressive variants may undergo cytoreductive therapies.<sup>1</sup> In our patient, the lack of recurrence after excision was expected given the good prognosis of isolated cutaneous mastocytosis.

## 4. Conclusion

Our patient, the fifth reported case of mastocytosis limited to the eyelid and only the second in an adult, serves as a reminder to include mast cell disease in the differential diagnosis of nodular eyelid lesions.

## Patient consent

Consent to publish this case report was not obtained as the authors' only involvement with the patient was interpretation of the biopsy. This report does not contain sufficient personal information for identification of the patient.

## Funding

No funding or grant support.

## Authorship

All authors attest that they meet the current ICMJE criteria for Authorship.

## Conflict of interest

None of the authors have any potential conflicts of interest with any organization or entity with a financial interest in or financial conflict with the subject matter or materials discussed in the manuscript.

## Acknowledgements

Ms. Susan Reeves prepared the composite figure.

## Appendix A. Supplementary data

Supplementary data related to this article can be found at <http://dx.doi.org/10.1016/j.ajoc.2018.01.009>.

## References

1. Chiu A, Orazi A. Mastocytosis and related disorders. *Semin Diagn Pathol.*

- 2012;29:19–30.
2. Horny H-P, Metcalfe D, Bennett J, et al. Mastocytosis. In: Swerdlow S, Campo E, Harris N, eds. *WHO Classification of Tumours of Haematopoietic and Lymphoid Tissues*. fourth ed. Lyon: International Agency for Research on Cancer; 2008:54–63.
3. Soilleux EJ. Recent advances in mastocytosis and neoplasms of probable monocytic/dendritic cell lineage. *Diagn Histopathol.* 2010;16:182–205.
4. Hannaford R, Rogers M. Presentation of cutaneous mastocytosis in 173 children. *Australas J Dermatol.* 2001;42:15–21.
5. Berezowska S, Flaig MJ, Rueff F, et al. Adult-onset mastocytosis in the skin is highly suggestive of systemic mastocytosis. *Mod Pathol.* 2014;27:19–29.
6. Wolff K, Komar M, Petzelbauer P. Clinical and histopathological aspects of cutaneous mastocytosis. *Leuk Res.* 2001;25:519–528.
7. Miller MA, Nelson SL, Turk JR, et al. Cutaneous neoplasia in 340 cats. *Vet Pathol.* 1991;28:389–395.
8. Newkirk KM, Rohrbach BW. A retrospective study of eyelid tumors from 43 cats. *Vet Pathol.* 2009;46:916–927.
9. Montgomery KW, van der Woerd A, Aquino SM, Sapienza JS, Ledbetter EC. Periocular cutaneous mast cell tumors in cats: evaluation of surgical excision (33 cases). *Vet Ophthalmol.* 2010;13:26–30.
10. Ma SP, Hardy TG. Solitary mastocytoma of the eyelid in an adult patient with prolidase deficiency. *Ophthalmic Plast Reconstr Surg.* 2017;33:e10–e13.
11. Naysan J, Kodsí SR, Kristal L. Solitary mastocytoma of the eyelid. *J AAPOS.* 2013;17:443–444.
12. Scheck O, Horny HP, Ruck P, Schmelzle R, Kaiserling E. Solitary mastocytoma of the eyelid. A case report with special reference to the immunocytochemistry of human tissue mast cells, and a review of the literature. *Virchows Arch A Pathol Anat Histopathol.* 1987;412:31–36.
13. Allington HV, Allington JH. Eyelid tumors. *Arch Dermatol.* 1968;97:50–65.
14. Aurora AL, Blodi FC. Lesions of the eyelids: a clinicopathological study. *Surv Ophthalmol.* 1970;15:94–104.
15. Deprez M, Uffer S. Clinicopathological features of eyelid skin tumors. A retrospective study of 5504 cases and review of literature. *Am J Dermatopathol.* 2009;31:256–262.
16. Valent P, Akin C, Escribano L, et al. Standards and standardization in mastocytosis: consensus statements on diagnostics, treatment recommendations and response criteria. *Eur J Clin Invest.* 2007;37:435–453.
17. Requena L, Prieto VG, Requena C, et al. Primary signet-ring cell/histiocytoid carcinoma of the eyelid: a clinicopathologic study of 5 cases and review of the literature. *Am J Surg Pathol.* 2011;35:378–391.
18. Hollmann TJ, Brenn T, Hornick JL. CD25 expression on cutaneous mast cells from adult patients presenting with urticaria pigmentosa is predictive of systemic mastocytosis. *Am J Surg Pathol.* 2008;32:139–145.