



Increased proximal vertebral rotation is associated with shoulder imbalance after posterior spinal fusion for severe adolescent idiopathic scoliosis

Masayoshi Machida¹ · Brett Rocos¹ · David E. Lebel¹ · Reinhard Zeller¹

Received: 10 December 2021 / Accepted: 2 April 2022 / Published online: 18 April 2022
© The Author(s), under exclusive licence to Scoliosis Research Society 2022

Abstract

Purpose Residual shoulder imbalance is associated with suboptimal outcomes following the surgical correction of adolescent idiopathic scoliosis (AIS) including poor patient satisfaction. In this retrospective study, we evaluate the radiographic parameters and the relationship between the global and local indices of spinal alignment with shoulder balance pre- and postoperatively utilizing EOS imaging and 3D reconstruction.

Methods A retrospective radiographic analysis was performed on patients with AIS, treated with posterior spinal fusion. Postoperative radiographs were obtained immediately following surgery, at 6 months and final follow-up over 2 years postoperatively. 3D Radiographic measurements included in the coronal plane radiographic shoulder height difference (RSHD), proximal thoracic Cobb angle (PT) and main thoracic Cobb (MT), in the sagittal plane T4–T12 kyphosis, T12–L5 lordosis, in the axial plane proximal thoracic (PT AVR) and main thoracic apical vertebral rotation (MT AVR).

Results Sixty-six patients were included (63 females) with an average main thoracic curvature of 76 degrees. RSHD averaged 14 mm ± 14 preoperatively, −15 mm ± 12 postoperatively, −8.5 mm ± 11 at 6 months, and −8.3 mm ± 8.7 at final follow-up, respectively. Statistical analysis revealed a significant correlation between RSHD and proximal thoracic Cobb angle, between RSHD and proximal thoracic apical vertebral rotation (PTAVR) ($r > 0.20$, $p < 0.05$).

Conclusion The significant correlation presented in this study suggests that PT Cobb angle and PT AVR are involved in postoperative shoulder imbalance.

The level of evidence Level 4.

Keywords Radiographic shoulder height difference · Apical vertebral rotation · Adolescent idiopathic scoliosis · Correction loss · Shoulder balance

Introduction

Scoliosis is a three-dimensional (3D) deformity of the spinal column, consisting of coronal, sagittal, and axial rotation [1, 2]. As a result, the shoulders often become unbalanced, which influences the patient's perception of the severity of their deformity. The primary goal of corrective surgery is an improvement in each dimension of the deformity. Despite

long experience of correcting these deformities, there is a new appreciation that improving the apical vertebral rotation (AVR) as part of addressing shoulder imbalance is important for successful correction [3–8]. It is, therefore, useful to understand the relationship between AVR and shoulder balance.

The two-dimensional (2D) indices of spinal alignment, such as the Cobb angle, are the usual radiological measurement used when recommending and evaluating the success of surgical treatment. However, 2D imaging fails to completely represent the deformity. With the increasing availability and use of 3D imaging, it has become evident that persisting AVR is associated with postoperative decompensation and reduced patient-perceived cosmetic outcomes [9, 10]. Previous investigations have measured AVR using computed tomography (CT); however, a CT scan is usually

Dr. Machida and Dr. Rocos had equal contribution and, therefore, are considered as the primary authors.

✉ Masayoshi Machida
masayoshimachida1985@yahoo.co.jp

¹ Department of Orthopaedic Surgery, The Hospital for Sick Children, 555 University Ave., Toronto M5G 1X8, Canada

carried out with the patient supine which causes the magnitude of rotational deformity to be decreased which in turn leads to a failure to represent the erect spine [11–15]. The 3D reconstructions of the spine acquired with the sterEOS imaging system (EOS imaging SA, Paris, France), where patients are imaged while standing, overcome this and permits accurate measurement of every dimension of the deformity [16].

The immediate and long-term effect of posterior spinal fusion (PSF) on postoperative shoulder balance is

not understood in sufficient detail to predict its impact on patient-perceived cosmetic outcomes. It is not known if or how a reduction in AVR correlates with shoulder balance over the long term. To establish the nature of this relationship, this study aims to quantify the effect of PSF on AVR and shoulder balance to 2-year follow-up using 3D sterEOS imaging. The secondary aim is to determine the relationship between the global and local indices of spinal alignment with shoulder balance both pre- and postoperatively.

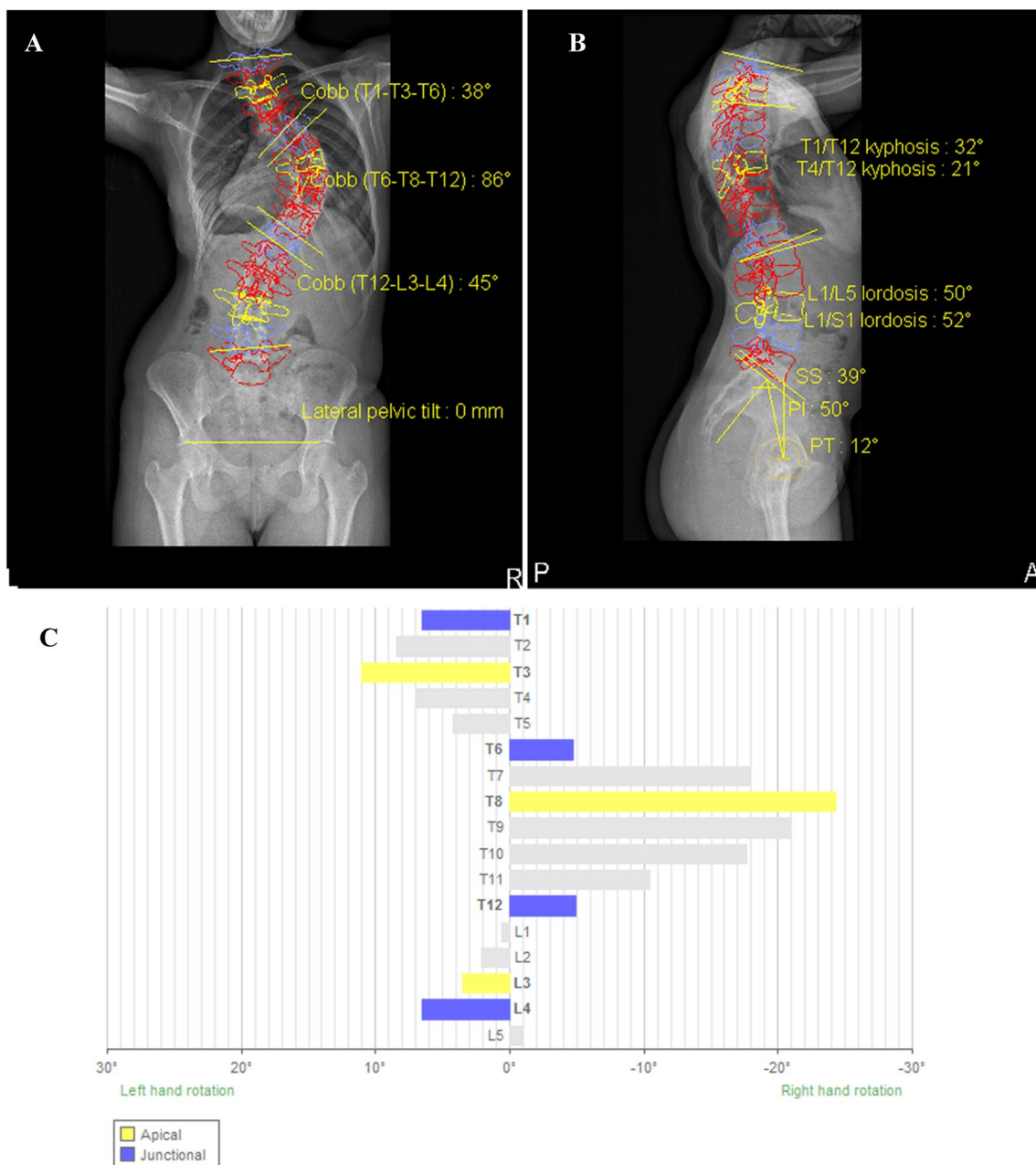


Fig. 1 sterEOS three-dimensional (3D) images of a representative clinical case of adolescent idiopathic scoliosis. EOS 3D reconstruction anteroposterior (AP) and lateral (LAT) X-ray images (**A**, **B**). **C** shows each vertebral rotation based on 3D reconstruction (Case 1)

Table 1 The patients demographics

Parameters	Mean \pm SD or <i>n</i> (%) <i>N</i> =66
Age (years)	14.8 \pm 1.5
Sex	
Female	63 (95%)
Male	3 (5%)
Risser sign	
Risser 0	4 (6.1%)
Risser 1	4 (6.1%)
Risser 2	7 (10.6%)
Risser 3	7 (10.6%)
Risser 4	21 (31.8%)
Risser 5	23 (34.8%)
Unfused tri-radiate cartilage	1 (1.5%)
Final follow-up (years)	2.8 \pm 1.1
Type of curve	
Lenke type 1	31 (47.0%)
Lenke type 2	10 (15.2%)
Lenke type 3	11 (16.7%)
Lenke type 4	3 (4.5%)
Lenke type 5	9 (13.6%)
Lenke type 6	2 (3.0%)

SD standard deviation

Methods

Local research ethics board approval was obtained. A retrospective radiographic analysis of consecutive patients diagnosed with adolescent idiopathic scoliosis (AIS) treated with PSF (incorporating direct rod translation and rod rotation) by a single surgeon at a single institution was carried out. The inclusion criteria comprised age less than 18 years at the time of surgery, a minimum of 2-years follow-up and sterEOS images at 1 week, 6 months, and final follow-up with shoulder assessment landmarks that were consistently

identifiable. The exclusion criteria were loss to follow-up before 2 years and any incidence of revision or anterior surgery prior to the PSF or in the subsequent 2 postoperative years. Alongside radiographic measurements, the patients' demographic data including sex, age, Risser sign and unfused tri-radiate cartilage were recorded.

The radiographs were then assessed by a board-certified spine surgeon independent of the treating surgical team on two occasions separated by 3 months using the sterEOS 3D method [17], and the measurements were averaged. The patient was standing with shoulders flexed forward in a relaxed position. The proximal thoracic (PT) and main thoracic (MT) coronal angular deformities, thoracic kyphosis (TK) from the superior endplate of T1 and T4 to the lower endplate of T12, and lumbar lordosis (LL) from the superior endplate of L1 to the endplate of L5 and S1 were measured using the Cobb method. AVR was defined as the rotational angle made between the longitudinal axis of the apical vertebra and the sagittal plane from the cranial perspective. A positive value indicated a counterclockwise rotation and a negative value a clockwise rotation. Radiographic shoulder height difference (RSHD) was defined as the difference of soft tissue shadows directly superior to the acromioclavicular joints between the right and left side [12, 18]. A positive RSHD indicated that the right shoulder side was higher, and a negative value indicated that the left was higher.

sterEOS software uses a semi-automated technique that integrates user input and a statistical model to generate a 3D representation of the spine [19]. In order to obtain a consistent reference plane independent from the positioning of the patient inside the EOS cage, the patient plane (PP) was chosen referenced to the manually identified femoral heads, thus defining a consistent reproducible reference plane for each patient. This patient plane passes through the bi-femoral head axis and is perpendicular to the axial plane. The 3D EOS software then automatically rotates the 3D model away from the original radiographic plane towards the patient plane. In doing so, the variations due to the positioning of the patient inside of the radiographic cage are eliminated.

Table 2 Radiographical summary of patient cohort

	Preoperative	Immediate postoperative	6 months postoperative	Final follow-up
PT Cobb angle (°)	32 \pm 13	18 \pm 7.1	17 \pm 8.1	17 \pm 7.4
MT Cobb angle (°)	76 \pm 14	21 \pm 7.3	21 \pm 7.4	22 \pm 7.4
TK(T4/12) (°)	20 \pm 16	17 \pm 9.4	18 \pm 9.2	20 \pm 8.5
LL(L1/5) (°)	48 \pm 12	43 \pm 8.8	45 \pm 7.4	49 \pm 7.7
RSHD (mm)	14 \pm 14	-15 \pm 12	-8.5 \pm 11	-8.3 \pm 8.7
PT AVR (°)	13 \pm 3.7	8.2 \pm 2.5	8.8 \pm 2.4	8.8 \pm 2.1
MT AVR (°)	-14 \pm 13	-6.8 \pm 7.3	-7.7 \pm 7.0	-6.8 \pm 6.9

PT proximal thoracic, MT main thoracic, TK thoracic kyphosis, LL lumbar lordosis, RSHD radiographic shoulder height difference, AVR apical vertebral rotation, Value: mean \pm standard deviation

Next, after defining the position of the sacroiliac (SI) joints and the S1 endplate, the positions of the T1 superior endplate and L5 inferior endplate were identified. The software then uses these data to generate a spline that is then adjusted manually for both the shape of the deformity and the width of the individual vertebrae [19, 20]. The system then uses 28 points, manually digitized on each vertebra, to determine the vertebral contour. Finally, these inputs are assembled to create a 3D model of the spine which was used to calculate T4–T12 Kyphosis and L1–L5 lordosis. The AVR was calculated as the angle between the planes, using the centroids of the end vertebrae of the curve and the apex of the curve defined by the orientation of the plane of maximum curvature of the thoracic and lumbar curves [21].

The data were analyzed using R (version 3.6.1, The R Foundation for Statistical Computing, Vienna, Austria). Distributions of variables are given as means, standard deviation (SD) and ranges. Pearson product-moment correlation coefficient was used to determine the relationship between

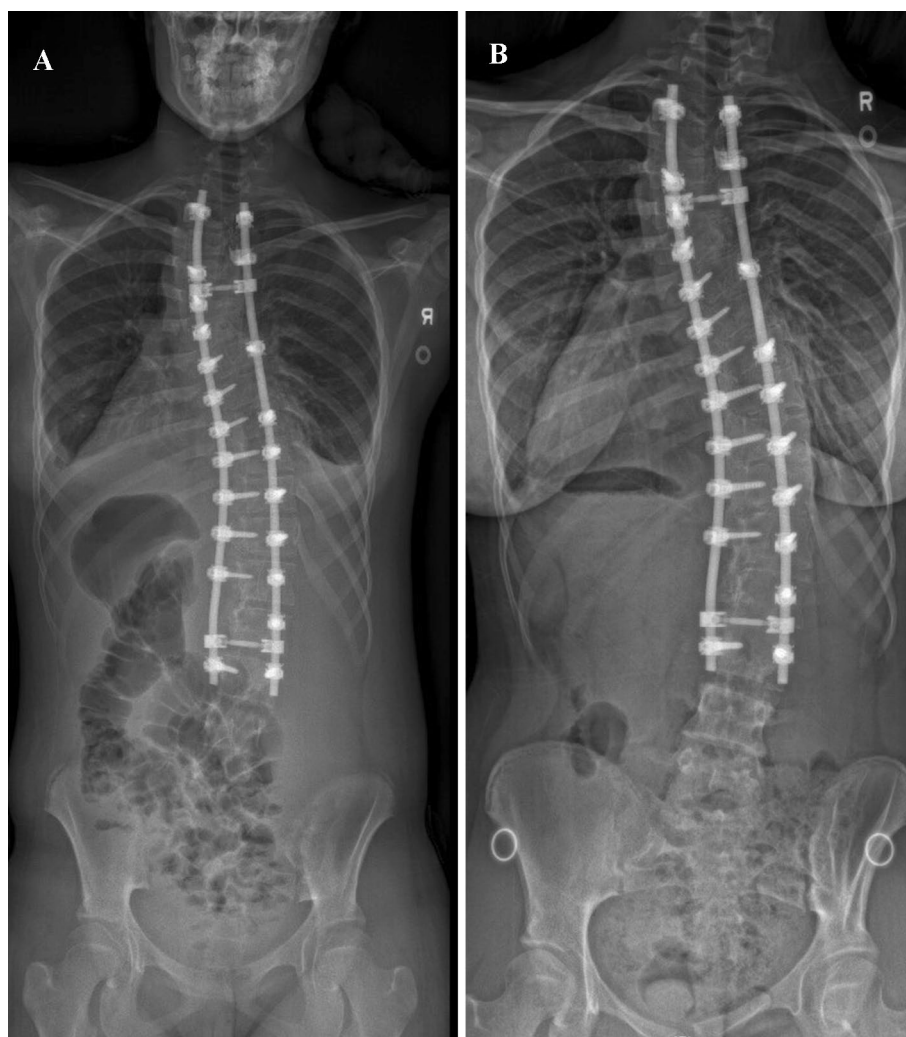RSHD at final follow-up and other radiological parameters at each period. *p*-values of less than 0.05 and correlation coefficient of more than 0.20 were considered to indicate statically significant correlation (Figs. 1).

Result

Sixty-six patients were included (63 females, 3 males) (Table 1). The mean age at surgery was 14.8 ± 1.5 years (range 11.5–17.4 years) and the mean follow-up was 2.8 ± 1.1 years. Thirty-one patients showed a Lenke type 1 deformity, 10 patients a Lenke type 2, 11 patients type 3, 3 patients type 4, 9 patients type 5 and 2 patients type 6.

The mean preoperative PT Cobb angle was 32° , 18° immediately postoperatively, 17° at 6 months postoperative, and 17° at final follow-up (Table 2). The mean preoperative MT Cobb angle was 76° , 21° immediately postoperatively, 21° at 6 months postoperatively, and 22° at final follow-up. The

Fig. 2 **A** The patient has undergone posterior spinal fusion (T2–L3). Preoperative radiographic shoulder height difference (RSHD) was -19.8 mm. Postoperatively, the residual shoulder height difference was -21.4 mm which deteriorated by final follow-up at 2 years (**B**) (Case 2)



mean RSHD was 14 mm preoperatively, -15 mm at immediate postoperatively, -8.5 mm at 6 months postoperatively, and -8.3 mm at final follow-up. The mean PT AVR angle was 13° preoperatively, 8.2° immediately postoperatively, 8.8° at 6 months postoperatively, and 8.8° at final follow-up. The mean MT AVR angle was -14° at preoperative, -6.8° at immediate postoperative, -7.7° at 6 months postoperative, and -6.8° at final follow-up, respectively. The analysis showed statistically significant correlations between PT Cobb angle and RSHD, PT AVR and RSHD ($r > 0.20$, $p < 0.05$) (Figs. 2, 3; Table 3).

Discussion

This analysis shows that there is a correlation between the postoperative RSHD and the residual PT AVR and coronal angular deformity after posterior spinal fusion for severe AIS, suggesting that addressing the AVR of the proximal curve is an important element in addressing a patient's perception of their postoperative deformity.

Perfectly symmetrical shoulder balance is rare, with Akel et al. finding a mean height difference of 7.5 ± 5.8 mm between shoulder in the normal population [22]. Postoperative shoulder imbalance is difficult

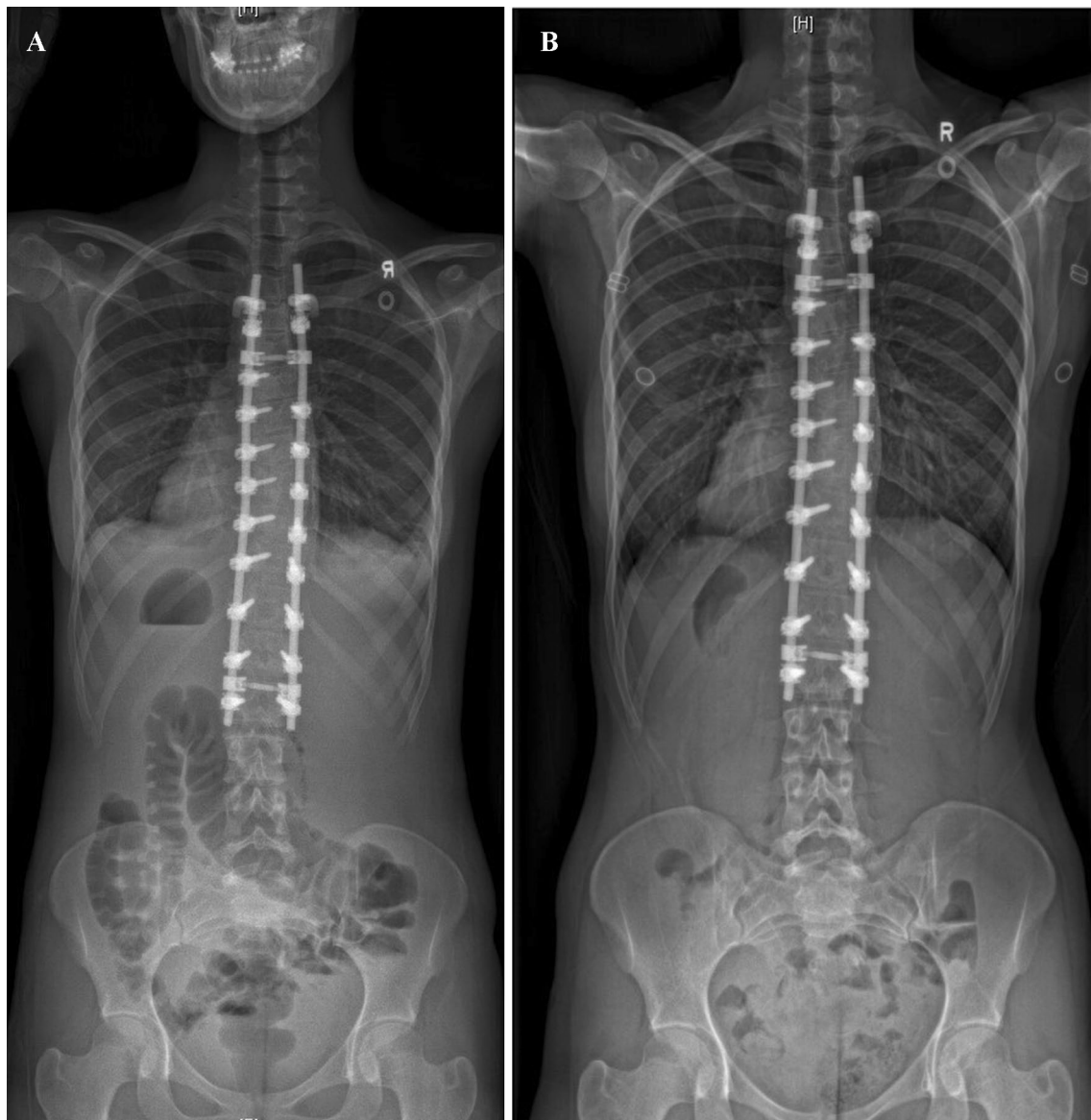

Fig. 3 **A** shows a patient who underwent posterior spinal fusion (T4–L2). The immediate postoperative RSHD was -14.0 mm. **B** Balanced shoulders (RSHD of 0 mm) at 3 years postoperatively (Case 3)

Table 3 Correlation coefficient between RSHD at final follow-up and other radiographic parameters at each period

	RSHD at preoperative	RSHD at immediate postoperative	RSHD at 6 months postoperative	RSHD at final follow-up
PT Cobb	$r = -0.22$ $p = 0.075$	$r = -0.27^*$ $p = 0.028$	$r = -0.34^*$ $p = 0.0048$	$r = -0.37^*$ $p = 0.0020$
MT Cobb	$r = -0.16$ $p = 0.20$	$r = -0.0083$ $p = 0.95$	$r = -0.020$ $p = 0.88$	$r = 0.061$ $p = 0.63$
TK(T4/12)	$r = -0.12$ $p = 0.32$	$r = 0.074$ $p = 0.55$	$r = 0.010$ $p = 0.94$	$r = 0.0035$ $p = 0.98$
LL(L1/5)	$r = -0.043$ $p = 0.73$	$r = 0.16$ $p = 0.21$	$r = -0.15$ $p = 0.22$	$r = 0.096$ $p = 0.44$
PT AVR	$r = -0.11$ $p = 0.36$	$r = -0.26^*$ $p = 0.037$	$r = -0.29^*$ $p = 0.017$	$r = -0.28^*$ $p = 0.022$
MT AVR	$r = 0.18$ $p = 0.14$	$r = 0.10$ $p = 0.41$	$r = 0.25^*$ $p = 0.046$	$r = 0.23$ $p = 0.066$

PT proximal thoracic, MT main thoracic, UIV upper instrumented vertebra, TK thoracic kyphosis, LL lumbar lordosis, RSHD radiographic shoulder height difference, AVR apical vertebral rotation

*Significant correlation ($r > 0.2$ and $p < 0.05$)

to manage because of the challenges in deciphering the relationship between spinal alignment and shoulder balance [23]. Many different solutions have been proposed to improve postoperative shoulder balance, ranging from different strategies for selecting the upper instrumented vertebra, to varying constructs (e.g., hooks versus screws) [24–26]. While some of these solutions offer better spinal alignment, their influence on shoulder balance remains inconsistent. When evaluated with complex tools, such as those recommended by Ilharreborde, including PT Cobb, bending radiographs, T1 tilt and pre-surgical shoulder balance, the shoulder imbalance persists in 14.9% of patients [27, 28].

The majority of clinicians rely on 2D radiography to assess spinal alignment and postoperative shoulder balance. To our knowledge, this is the first study that uses sterEOS 3D reconstruction to analyze the relationship of AVR to postoperative shoulder imbalance after surgical treatment of AIS. An important advantage of the analysis by EOS reconstruction is the repeatability of vertebral rotation measurements because the referential system is based on each patient's individual patient plane, which is not altered by the surgical correction [3]. The reliability of this technique is confirmed by Al-Aubaidi et al., who have reported that EOS measurement of rotational deformity in scoliosis patients is comparable with CT measurement [15]. However, the 3D steEOS has the added benefit of assessing the upright spine with less radiation exposure for the patient.

This study confirmed the influence of the residual proximal thoracic coronal deformity on shoulder balance. Furthermore, it demonstrates a statistically significant correlation between the residual spinal rotation in the proximal thoracic curve and final shoulder balance. Yagi et al. confirmed the relationship between RSHD and MT AVR, which must be in

the opposite direction to PT AVR [29]. It is possible to speculate that MT AVR could cause RSHD and that PT AVR in the opposite direction could cause the same effect, and these data might agree with the hypothesis that increased proximal spinal rotation might generate shoulder imbalance through increased rotation of the proximal rib cage. However, the correlation found in our study is too weak to confirm this hypothesis and that further studies are necessary.

There are several limitations in this study. One limiting factor is the possibility of variation in patients' posture as the radiograph is taken. During image acquisition, the EOS cage imposes a standard posture, though in some cases, patients elevated their arms, which may cause postural variations disturbing RSHD measurements. One might argue that the correlation factor of -0.28 for PT AVR and -0.37 for PT Cobb angle demonstrates only a moderate correlation between shoulder imbalance and those parameters. This could be explained by the complex nature of the underlying etiology of shoulder imbalance. Lastly, the current version of the EOS software does not allow to a reconstruction of the proximal rib cage to be made. An extension of this software allowing for a precise reconstruction of the chest wall might refine the analysis of the factors generating postoperative shoulder imbalance.

Conclusion

A significant correlation between postoperative RSHD and residual PT AVR and PT Cobb angle was found after posterior spinal fusion for severe AIS. These findings suggest that PT Cobb angle and PT AVR are significant elements among factors susceptible to generate postoperative shoulder imbalance in AIS.

Author contribution Masayoshi Machida, MD: Acquisition, analysis and interpretation of data, drafted the work, approved the version to be published and agrees to be accountable for all aspects of the work. Brett Rocos MD FRCS (Tr & Orth): Analysis and interpretation of data, drafted the work, approved the version to be published, and agrees to be accountable for all aspects of the work. David E. Lebel MD PhD: Made substantial contributions to the conception and design of the work, critically revised the manuscript, approved the version to be published, and agrees to be accountable for all aspects of the work. Reinhard Zeller MD FRCS: Made substantial contributions to the conception and design of the work, critically revised the manuscript, approved the version to be published, and agrees to be accountable for all aspects of the work.

Funding No funding was received in support of this work.

Availability of data and materials Data are available on request to the corresponding author.

Code availability Not applicable.

Declarations

Conflict of interest Masayoshi Machida, Brett Rocos, and David E Lebel declare that they have no conflict of interest. Reinhard Zeller declares fellowship support from Stryker and SpineVision.

Ethics approval Institutional research ethics board approval was granted for this study.

Consent to participate No applicable.

Consent for publication Not applicable.

References

- Mehta MH (1973) Radiographic estimation of vertebral rotation in scoliosis. *J Bone Joint Surg Br* 55(3):513–520
- Perdriolle R, Vidal J (1987) Morphology of scoliosis: three-dimensional evolution. *Orthopedics* 10(6):909–915
- Kato S, Debaud C, Zeller RD (2017) Three-dimensional EOS analysis of apical vertebral rotation in adolescent idiopathic scoliosis. *J Pediatr Orthop* 37(8):543–547. <https://doi.org/10.1097/BPO.0000000000000776>
- Gotfryd AO, Silber Caffaro MF, Meves R et al (2017) Predictors for postoperative shoulder balance in Lenke I adolescent idiopathic scoliosis: a prospective cohort study. *Spine Deform* 5(1):66–71. <https://doi.org/10.1016/j.jspd.2016.09.046>
- Kuklo TR, Lenke LG, Graham EJ et al (2002) Correlation of radiographic, clinical, and patient assessment of shoulder balance following fusion versus non fusion of the proximal thoracic curve in adolescent idiopathic scoliosis. *Spine (Phila Pa 1976)* 27(18):2013–2020. <https://doi.org/10.1097/00007632-200209150-00009>
- Asher MA, Burton DC (2006) Adolescent idiopathic scoliosis: natural history and long term treatment effects. *Scoliosis* 1(1):2. <https://doi.org/10.1186/1748-7161-1-2>
- Carlson BB, Asher MA, Burton DC (2013) Comparison of trunk and spine deformity in adolescent idiopathic scoliosis. *Scoliosis* 8(1):2. <https://doi.org/10.1186/1748-7161-8-2>
- Sanders AE, Baumann R, Brown H (2003) Selective anterior fusion of thoracolumbar/lumbar curves in adolescents: when can the associated thoracic curve be left unfused? *Spine (Phila Pa 1976)* 28(7):706–713. <https://doi.org/10.1097/01.BRS.0000051925.88443.85>
- Pratt RK, Burwell RG, Cole AA et al (2002) Patient and parental perception of adolescent idiopathic scoliosis before and after surgery in comparison with surface and radiographic measurements. *Spine (Phila Pa 1976)* 27(14):1543–1550. <https://doi.org/10.1097/00007632-200207150-00012>
- Behensky H, Cole AA, Freeman BJ et al (2007) Fixed lumbar apical vertebral rotation predicts spinal decompensation in Lenke type 3C adolescent idiopathic scoliosis after selective posterior thoracic correction and fusion. *Eur Spine J* 16(10):1570–1578. <https://doi.org/10.1007/s00586-007-0397-8>
- Lee SM, Suk SI, Chung ER (2004) Direct vertebral rotation: a new technique of three-dimensional deformity correction with segmental pedicle screw fixation in adolescent idiopathic scoliosis. *Spine (Phila Pa 1976)* 29(3):343–349. <https://doi.org/10.1097/01.brs.0000109991.88149.19>
- Asghar J, Samdani AF, Pahys JM et al (2009) Computed tomography evaluation of rotation correction in adolescent idiopathic scoliosis: a comparison of an all pedicle screw construct versus a hook-rod system. *Spine (Phila Pa 1976)* 34(8):804–807. <https://doi.org/10.1097/BRS.0b013e3181996c1b>
- Cui G, Watanabe K, Nishiwaki Y et al (2012) Loss of apical vertebral derotation in adolescent idiopathic scoliosis: 2-year follow-up using multi-planar reconstruction computed tomography. *Eur Spine J* 21(6):1111–1120. <https://doi.org/10.1007/s00586-012-2274-3>
- Abul-Kasim K, Overgaard A, Maly P et al (2009) Low-dose helical computed tomography (CT) in the perioperative workup of adolescent idiopathic scoliosis. *Eur Radiol* 19(3):610–618. <https://doi.org/10.1007/s00330-008-1178-4>
- Al-Aubaidi Z, Lebel D, Oudjhane K et al (2013) Three-dimensional imaging of the spine using the EOS system: is it reliable? A comparative study using computed tomography imaging. *J Pediatr Orthop B* 22(5):409–412. <https://doi.org/10.1097/BPB.0b013e328361ae5b>
- Dubouset J, Charpak G, Skalli W et al (2007) EOS stereo-radiography system: whole-body simultaneous anteroposterior and lateral radiographs with very low radiation dose. *Rev Chir Orthop Reparatrice Appar Mot* 93(6):141–143. [https://doi.org/10.1016/s0035-1040\(07\)92729-4](https://doi.org/10.1016/s0035-1040(07)92729-4)
- Pasha S, Cahill PJ, Dormans JP et al (2016) Characterizing the differences between the 2D and 3D measurements of spine in adolescent idiopathic scoliosis. *Eur Spine J* 25(10):3137–3145. <https://doi.org/10.1007/s00586-016-4582-5>
- Hwang SW, Samdani AF, Cahill PJ (2012) The impact of segmental and en bloc derotation maneuvers on scoliosis correction and rib prominence in adolescent idiopathic scoliosis. *J Neurosurg Spine* 16(4):345–350. <https://doi.org/10.3171/2011.11.SPINE.11277>
- Humbert L, De Guise JA, Aubert B et al (2009) 3D reconstruction of the spine from biplanar X-rays using parametric models based on transversal and longitudinal inferences. *Med Eng Phys* 31(6):681–687. <https://doi.org/10.1016/j.medengphy.2009.01.003>
- Gille O, Champain N, Benchikh-El-Fegoun A et al (2007) Reliability of 3D reconstruction of the spine of mild scoliotic patients. *Spine (Phila Pa 1976)* 32(5):568–573. <https://doi.org/10.1097/01.brs.0000256866.25747.b3>
- Sangole AP, Aubin CE, Labelle H et al (2009) Three-dimensional classification of thoracic scoliotic curves. *Spine (Phila Pa 1976)* 34(1):91–99. <https://doi.org/10.1097/BRS.0b013e3181877bbb>
- Akel I, Pekmezci M, Hayran M et al (2008) Evaluation of shoulder balance in the normal adolescent population and its correlation

- with radiological parameters. *Eur Spine J* 17(3):348–354. <https://doi.org/10.1007/s00586-007-0546-0>
23. Brooks JT, Bastrom TP, Bartley CE et al (2018) In search of the Ever-Elusive postoperative shoulder balance: is the T2 UIV the Key? *Spine Deform* 6(6):707–711. <https://doi.org/10.1016/j.jspd.2018.03.010>
 24. Lee CS, Hwang CJ, Lee DH et al (2019) Does fusion to T2 compared with T3/T4 lead to improved shoulder balance in adolescent idiopathic scoliosis with a double thoracic curve? *J Pediatr Orthop Bv* 28(1):32–39. <https://doi.org/10.1097/BPB.0000000000000520>
 25. Moorthy V, Goh GS, Guo CM et al (2021) Shoulder balance following correction surgery for adolescent idiopathic scoliosis: when is it achieved and does the type of construct matter? *Clin Spine Surg*. <https://doi.org/10.1097/BSD.0000000000001154>
 26. Kuroya S, Akazawa T, Kotani T et al (2019) Hooks at the upper instrumented vertebra can adjust postoperative shoulder balance in patients with adolescent idiopathic scoliosis: 5 years or more of follow-up. *Asian Spine J* 13(5):793–800. <https://doi.org/10.31616/asj.2018.0206>
 27. Bjerke BT, Cheung ZB, Shifflett GD et al (2015) do current recommendations for upper instrumented vertebra predict shoulder imbalance? An attempted validation of level selection for adolescent idiopathic scoliosis. *HSS J* 11(3):216–222. <https://doi.org/10.1007/s11420-015-9451-y>
 28. Ilharreborde B (2018) Sagittal balance and idiopathic scoliosis: does final sagittal alignment influence outcomes, degeneration rate or failure rate? *Eur Spine J* 27(suppl 1):48–58. <https://doi.org/10.1007/s00586-018-5472-9>
 29. Yagi M, Takemitsu M, Machida M (2013) Chest cage angle difference and rotation of main thoracic curve are independent risk factors of postoperative shoulder imbalance in surgically treated patients with adolescent idiopathic scoliosis. *Spine (Phila Pa 1976)* 38(19):E1209–15. <https://doi.org/10.1097/BRS.0b013e31829e0309>