

# Classifications for Adult Spinal Deformity and Use of the Scoliosis Research Society–Schwab Adult Spinal Deformity Classification

Shay Bess, MD<sup>a,\*</sup>, Frank Schwab, MD<sup>b</sup>,  
Virginie Lafage, PhD<sup>b</sup>, Christopher I. Shaffrey, MD<sup>c,d</sup>,  
Christopher P. Ames, MD<sup>a</sup>

## KEYWORDS

• Adult spinal deformity • Classification • Schwab Adult Spinal Deformity Classification • Disability

## KEY POINTS

- Classification systems should describe important features of disease states and provide clinical information regarding the classified disease state.
- Previous classifications for adult spinal deformity (ASD) neglected evaluation of sagittal spinopelvic parameters.
- Pelvic incidence/lumbar lordosis mismatch (PI-LL), increased sagittal vertical axis (SVA), and increased pelvic tilt (PT) correlate strongly with pain and disability in patients with ASD.
- The Scoliosis Research Society (SRS)–Schwab ASD Classification describes the location of the scoliotic curve and uses 3 sagittal modifiers (PI-LL, SVA, and PT) to evaluate the sagittal plane and correlate spinal deformity with patient pain and disability.
- Greater spinal deformity grade on the SRS–Schwab ASD Classification predicts patient disability.

---

Disclosures: Dr Bess consults for Alphatec, Allosource, DePuy Spine, and Medtronic; receives royalties from Pioneer Spine; receives research support from DePuy Spine, Medtronic, Orthopaedic Research and Education Foundation; and is on the Scientific Advisory Board for Allosource. Dr Schwab consults for Medtronic, DePuy Spine; receives royalties from Medtronic; is a shareholder of Nemaris Inc.; receives research support from DePuy Spine, NIH; and provides educational communication for Medtronic, DePuy Spine. Dr Lafage consults for Medtronic; receives research support from the Scoliosis Research Society; is a shareholder of Nemaris Inc.; and provides educational communication for Medtronic, K2M, and DePuy Spine. Dr Shaffrey consults for Biomet, DePuy-Synthes, Globus, Medtronic, and Nuvasive; receives royalties from Biomet, and Medtronic; receives research support from AO, DePuy-Synthes, Department of Defense, Medtronic, NACTN, and NIH.

Conflicts of interest: None.

<sup>a</sup> Departments of Orthopedics, Rocky Mountain Hospital for Children, Presbyterian/St Lukes Medical Center, Rocky Mountain Scoliosis and Spine, 2055 High Street, Suite 130, Denver, CO 80205, USA; <sup>b</sup> Departments of Orthopedics, NYU Hospital for Joint Diseases, 306 East 15th Street, New York, NY 10003, USA; <sup>c</sup> Department of Neurological Surgery, University of Virginia, Box 800212, Charlottesville, VA 22908, USA; <sup>d</sup> Department of Orthopaedic Surgery, University of Virginia, Box 800212, Charlottesville, VA 22908, USA

\* Corresponding author.

E-mail address: [shay\\_bess@hotmail.com](mailto:shay_bess@hotmail.com)

Neurosurg Clin N Am 24 (2013) 185–193

<http://dx.doi.org/10.1016/j.nec.2012.12.008>

1042-3680/13/\$ – see front matter © 2013 Elsevier Inc. All rights reserved.

## INTRODUCTION

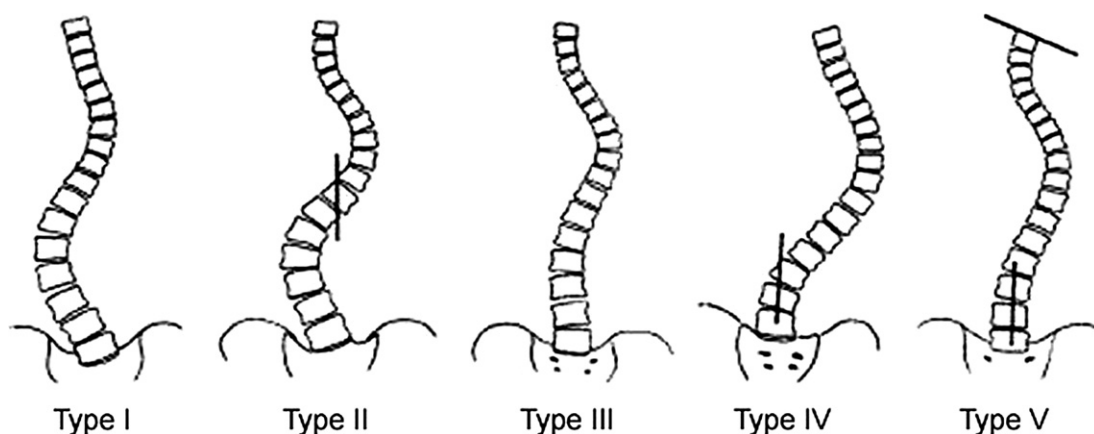
Classification systems are created to provide organization to pathologic conditions and provide treatment options for disease states that share a common theme. A classification ideally provides a cohesive approach to the disease state that (1) identifies different severities of the disease state (often in a hierarchical manner), (2) facilitates communication between health care providers and researchers to assure accuracy and reproducibility in describing the disease state, (3) allows for comparison of different treatment methods and, as a consequence, (4) allows for creation of accurate treatment recommendation guidelines. From a statistical standpoint, a classification system should have high construct validity (the extent to which classification accurately measures the disease state) and high reliability as shown by high intrarater reliability (consistent grading by 1 rater at different time points) and inter-rater reliability (consistent grading by different raters). The classification should also have high reproducibility (the degree of agreement between measurements on replicate specimens in different locations by different observers). This article provides an overview of existing classification systems for spinal deformity and highlights the challenges of creating an effective classification for adult spinal deformity (ASD). This article then focuses on the Scoliosis Research Society (SRS)–Schwab ASD Classification, including the rationale behind the development of the SRS–Schwab ASD Classification, guidelines for use of the SRS–Schwab ASD Classification, and initial data on use of the classification.

## BACKGROUND ON SPINAL DEFORMITY CLASSIFICATION SYSTEMS

Most classifications traditionally used to describe spinal deformity have been oriented toward pediatric spinal deformities. In the past, the King-Moe Classification for Adolescent Idiopathic Scoliosis (AIS) has been the standard to describe scoliosis.<sup>1</sup> The principle benefit of the King-Moe classification was that it provided a treatment algorithm based on curve type that allowed surgeons to determine the appropriate curves and vertebral levels for spinal fusion. Five types of curves were described in detail including type I, a double major curve, in which the thoracic and lumbar curves are considered structural and both curves should be included in the fusion; type II, a single major curve, in which the thoracic and lumbar curves cross the midline (center sacral vertical line [CSVL]), but the thoracic curve is larger and more rigid than the lumbar curve and therefore the thoracic

curve is structural and only the thoracic curve should be included in the fusion; type III, in which only the thoracic curve crosses the midline, and only the thoracic curve should be included in the fusion; type IV, a long, sweeping thoracic curve in which L4 is tilted toward the thoracic curve and L5 is centered over the sacrum, distal fusion level recommended to be the first vertebra bisected by the CSVL; type V, a double thoracic curve pattern in which the proximal and main thoracic curves are considered structural and are included in the fusion (Fig. 1).

The King-Moe system remained the principal classification for AIS for more than 20 years, guiding evaluation and treatment; however, several limitations of the King-Moe system have been highlighted. First, the King-Moe system is not comprehensive, because isolated thoracolumbar and triple major curves were not described. All patients in the King and colleagues<sup>1</sup> series received Harrington rod instrumentation that solely corrected deformity in the coronal plane via distraction, therefore the deformities were evaluated only in the coronal plane, failing to recognize scoliosis as a three-dimensional deformity and the need to assess the coronal, sagittal, and axial planes. The King-More system has also shown fair to poor interobserver and intraobserver validity, reliability, and reproducibility by 2 separate studies.<sup>2,3</sup> In response to these shortcomings, Lenke and colleagues<sup>4</sup> developed a classification system for the operative treatment of AIS. This classification was designed to be (1) comprehensive, to include all AIS curve types; (2) provide two-dimensional analysis with increased emphasis on evaluation of the sagittal plane; (3) treatment based, advocating selective arthrodesis only of the structural curves; and (4) provide objective criteria to differentiate individual curve types and provide guidelines for fusion. The Lenke classification describes 3 curve regions (proximal thoracic [PT], apex at T3, T4, or T5; main thoracic [MT], apex between T6 and the T11–T12 disc; and thoracolumbar/lumbar [TL/L], apex at T12 or L1 for thoracolumbar curves, and between the L1–L2 disc and L4 for lumbar curves) and 2 curve types (major curve, the largest measured curve; minor curve, the smaller curves). The minor curves are then established as structural or nonstructural by evaluating curve flexibility and sagittal alignment. Structural curves show coronal plane rigidity (do not reduce less than 25° on side bending radiographs) and/or are focally kyphotic in the sagittal plane (focal kyphosis >20°). Focal kyphosis for the described curve regions is measured in the following areas: PT, T2 to T5; MT, T10 to L2; and TL/L, T10 to L2. Using the



**Fig. 1.** King-Moe Classification for Thoracic Idiopathic Scoliosis. (Adapted from King HA, Moe JH, Bradford DS, et al. The selection of fusion levels in thoracic idiopathic scoliosis. *J Bone Joint Surg Am* 1983;65:1302–13; with permission.)

Lenke classification, 6 curve types can be assigned according to the identified major and minor structural curves, and are named according to the identified structural curves: type 1, MT curve (structural); type 2, double thoracic (PT and MT curves are structural); type 3, double major (MT and TL/L curves are structural, MT is larger on standing radiographs); type 4, triple major (PT, MT, and TL/L curves are structural); type 5, thoracolumbar/lumbar (TL/L curve structural); and type 6 (MT and TL/L are structural, TL/L is larger on standing radiographs). Treatment guidelines recommend selective fusion, advocating fusion only of those curves that are structural as per the classification guidelines (Fig. 2).

The Lenke classification has been widely adopted for evaluation and treatment of AIS, with excellent success. However, despite the initial usefulness of the King-Moe and, subsequently, the Lenke classifications to describe AIS, there have been attempts to apply many of these same classification guidelines to ASD. The error in applying AIS and/or pediatric spinal deformity assessment guidelines to creating an ASD classification lies in heterogeneity of the clinical and radiographic presentation of ASD. Although cosmetic deformity and coronal malalignment are the most common reasons for presentation and treatment of pediatric patients with spinal deformity, especially AIS, pain is the primary complaint for patients with ASD.<sup>5–8</sup> Effective AIS classifications have therefore focused on strategies to evaluate and treat scoliosis and coronal malalignment; however, classifications for ASD must quantify the major predictors of pain in the ASD population. Early attempts at developing ASD classifications by Aebi<sup>10</sup> and by the SRS failed to integrate this clinical component of pain in the ASD population,

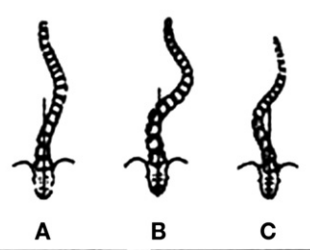
and therefore, despite being descriptive of the cause and observed radiographic parameters, these classifications lacked clinical relevance.<sup>9,10</sup> Scoliosis and coronal plane deformities are common for both AIS and ASD; however, it has been repeatedly shown that sagittal malalignment is a fundamental component of ASD, and that sagittal malalignment is a primary determinant of pain and disability in the ASD population.<sup>6,11–14</sup> One advantage of the Lenke classification is that it calls for greater attention to the sagittal plane, although it does so within the confines of defining the structural behavior of a coronal deformity (idiopathic scoliosis) rather than purely quantifying the amount of sagittal plane deformity. Based on these concepts, initial work by Schwab and colleagues<sup>8</sup> established a foundation for a clinical impact classification for ASD that integrated radiographic parameters correlating with poor health-related quality of life (HRQOL) parameters.<sup>15–17</sup> This initial classification by Schwab and colleagues<sup>17</sup> described 5 types of scoliosis based on the apical level of the curve: type I, thoracic only; type II, upper thoracic major (apex T4–T8); type III, lower thoracic major (apex T9–T10); type IV, thoracolumbar major curve (apex T11–L1); type V, lumbar major curve (apex L2–L4). Two radiographic parameters were then added as modifiers to the curve type: lumbar lordosis and intervertebral subluxation. Loss of lumbar lordosis and increased intervertebral subluxation correlated with poor HRQOL scores, so it is these modifiers that denoted the clinical impact of this classification. Soon after publication, it was recognized that global sagittal malalignment, measured by sagittal vertical axis (SVA; distance from the C7 plumb line to the posterior, superior corner of S1) is an equally important predictor of poor HRQOL

Curve Type				
Type	Proximal Thoracic	Main Thoracic	Thoracolumbar/Lumbar	Curve Type
1	Non-Structural	Structural (Major*)	Non-Structural	Main Thoracic (MT)
2	Structural	Structural (Major*)	Non-Structural	Double Thoracic (DT)
3	Non-Structural	Structural (Major*)	Structural	Double Major (DM)
4	Structural	Structural (Major*)	Structural	Triple Major (TM)
5	Non-Structural	Non-Structural	Structural (Major*)	Thoracolumbar/Lumbar (TL/L)
6	Non-Structural	Structural	Structural (Major*)	Thoracolumbar/Lumbar—Main Thoracic (TL/L—MT)


  

<p><b>STRUCTURAL CRITERIA</b> (Minor Curves)</p> <p><i>Proximal Thoracic:</i> —Side Bending Cobb <math>\geq 25^\circ</math> —T2–T5 Kyphosis <math>\geq +20^\circ</math></p> <p><i>Main Thoracic:</i> —Side Bending Cobb <math>\geq 25^\circ</math> —T10–L2 Kyphosis <math>\geq +20^\circ</math></p> <p><i>Thoracolumbar/Lumbar:</i> —Side Bending Cobb <math>\geq 25^\circ</math> —T10–L2 Kyphosis <math>\geq +20^\circ</math></p>	<p>*Major = Largest Cobb Measurement, always structural Minor = all other curves with structural criteria applied</p> <p style="text-align: center;"><b>LOCATION OF APEX</b> (SRS definition)</p> <table border="0" style="width: 100%;"> <tr> <td style="text-align: center;"><b>CURVE</b></td> <td style="text-align: center;"><b>APEX</b></td> </tr> <tr> <td>THORACIC</td> <td>T2–T11–12 DISC</td> </tr> <tr> <td>THORACOLUMBAR</td> <td>T12–L1</td> </tr> <tr> <td>LUMBAR</td> <td>L1–2 DISC–L4</td> </tr> </table>	<b>CURVE</b>	<b>APEX</b>	THORACIC	T2–T11–12 DISC	THORACOLUMBAR	T12–L1	LUMBAR	L1–2 DISC–L4
<b>CURVE</b>	<b>APEX</b>								
THORACIC	T2–T11–12 DISC								
THORACOLUMBAR	T12–L1								
LUMBAR	L1–2 DISC–L4								

Modifiers		
Lumbar Spine Modifier	CSVL to Lumbar Apex	
A	CSVL Between Pedicles	A
B	CSVL Touches Apical Body(ies)	B
C	CSVL Completely Medial	C

Thoracic Sagittal Profile T5–T12		
– (Hypo)		$<10^\circ$
N (Normal)		$10^\circ\text{--}40^\circ$
+ (Hyper)		$>40^\circ$

Curve Type (1–6) + Lumbar Spine Modifier (A, B, or C) + Thoracic Sagittal Modifier (–, N, or +)  
Classification (e.g. 1B+): \_\_\_\_\_

Fig. 2. Lenke Classification for Adolescent Idiopathic Scoliosis. (Adapted from Lenke LG, Betz RR, Harms J, et al. Adolescent idiopathic scoliosis: a new classification to determine extent of spinal arthrodesis. J Bone Joint Surg Am 2001;83:1169–81; with permission.)

scores as regional sagittal malalignment (loss of lumbar lordosis). Therefore the classification added a third modifier, termed the global balance modifier, as a final component to describe the radiographic deformity and predict the associated disability (Box 1).

**SRS-SCHWAB ASD CLASSIFICATION**

The Schwab Clinical Impact Classification represented an advance in the manner by which ASD is classified because it highlighted radiographic parameters that correlate with pain and disability in ASD. However, further research has shown that lumbar lordosis (LL) and SVA alone do not provide a complete picture of the disorders leading to sagittal malalignment.<sup>18–20</sup> The importance of pelvic alignment to the maintenance of

upright posture has been increasingly emphasized, leading to the concept of spinopelvic alignment as a more complete description of the physiologic mechanisms used to maintain standing upright posture.<sup>21–24</sup> Pelvic measurements include pelvic incidence (PI), which is a fixed, morphologic parameter, and 2 dynamic parameters that reflect compensatory changes within the pelvis to maintain upright posture: pelvic tilt (PT) and sacral slope (SS; Fig. 3). Pelvic retroversion is a compensatory mechanism used to maintain upright posture in the setting of sagittal malalignment. Increased PT indicates pelvic retroversion, and has been shown to correlate with poor HRQOL.<sup>12</sup> PT has also been described to normalize (relaxation of pelvic retroversion) in conjunction with improved SVA following lumbar osteotomy procedures.<sup>25</sup> PI is a morphologic

**Box 1****Schwab Clinical Impact Classification for ASD**

Type: location of the deformity (apical level of the major curve or sagittal plane only)

Type I: thoracic-only scoliosis (no thoracolumbar or lumbar component)

Type II: upper thoracic major, apex T4 to T8 (with thoracolumbar or lumbar curve)

Type III: lower thoracic major, apex T9 to T10 (with thoracolumbar/lumbar curve)

Type IV: thoracolumbar major curve, apex T11 to L1 (with any other minor curve)

Type V: lumbar major curve, apex L2 to L4 (with any other minor curve)

Type K: deformity in the sagittal plane only

Lordosis modifier: sagittal Cobb angle from T12 to S1

A: marked lordosis greater than 40°

B: moderate lordosis 0°–40°

C: no lordosis present Cobb less than 0°

Subluxation modifier: frontal or sagittal plane (anterior or posterior), maximum value

0: no subluxation

+ : subluxation 1 to 6 mm

+ + : subluxation greater than 7 mm

Global balance modifier: sagittal plane C7 offset from posterior superior corner S1

N: normal (0–4 cm)

P: positive (4–9.5 cm)

VP: very positive (>9.5 cm)

*Adapted from Schwab F, Lafage V, Farcy JP, et al. Surgical rates and operative outcome analysis in thoracolumbar and lumbar major adult scoliosis: application of the new adult deformity classification. Spine 2007;32:2723–30; with permission.*

parameter, and therefore, as an isolated measure, PI provides limited information; however, the relationship of PI to LL provides valuable information regarding the patient's sagittal spinopelvic alignment and provides surgeons with reconstructive requirements to restore a physiologic sagittal profile. In line with these findings, work by Lafage and colleagues<sup>12</sup> and Schwab and colleagues<sup>13,14,26</sup> has led to the discovery of threshold spinopelvic parameters for pain and severe disability. Values including PT greater than 22°, PI-LL greater than 11°, and SVA greater than 46 mm have been shown to correlate with Oswestry Disability Index (ODI) scores greater than

40 (severe disability) in a prospective cohort of patients with ASD.<sup>26</sup> The Schwab classification, in conjunction with efforts through the SRS, was consequently updated to reflect these data and create the SRS-Schwab ASD Classification.<sup>27</sup>

## RADIOGRAPHIC ANALYSIS AND CLASSIFICATION

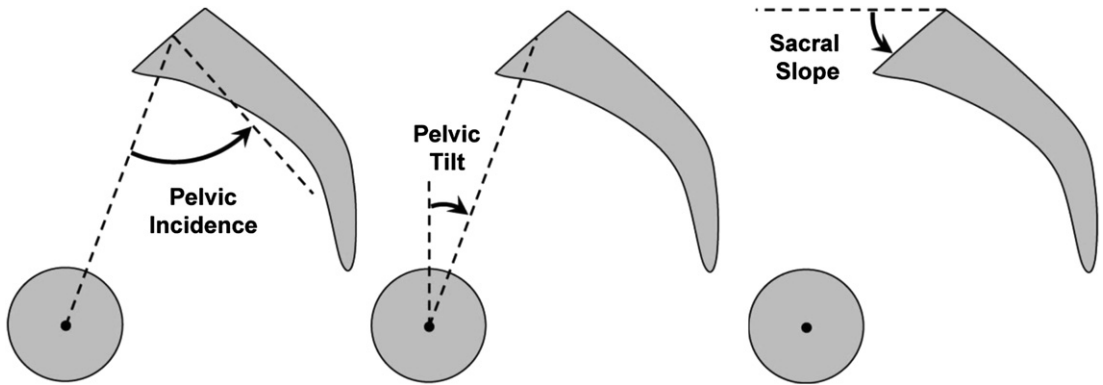
Accurate radiographic analysis of ASD requires full-length frontal and lateral radiographs that visualize C7 and the bilateral femoral heads. As an overview of the SRS-Schwab ASD Classification, the 2 primary components of the classification include (1) coronal curve type (assessment of the frontal plane deformity by denoting the location and magnitude of scoliotic curves) and (2) sagittal modifiers (assessment of the sagittal plane deformity via PI-LL, SVA, and PT as referenced earlier). The sagittal modifiers are then graded by the severity of the deformity (**Fig. 4**).<sup>12–14,22,26</sup>

The curve type is assigned based on the location and Cobb angle of the scoliotic curve(s). Only curves greater than 30° are considered for classification. Curve types include type T (isolated major thoracic curve >30°, curve apex at T9 or cranial), type L (isolated thoracolumbar or lumbar curve >30°, curve apex at T10 or caudal), type D (double major curve in which the thoracic and thoracolumbar/lumbar curves are >30°), and type N (normal; no scoliotic curve >30°).

The first sagittal modifier, PI-LL modifier, measures the PI/LL mismatch, providing an assessment of the amount of disharmony between the patient's morphologic PI and corresponding LL. LL should be within 10° of PI, consequently patients with PI-LL less than 10° are assigned a PI-LL modifier of 0. Patients with PI-LL between 10° and 20° are assigned PI-LL modifier of +, and patients with PI-LL greater than 20° are assigned PI-LL modifier of ++.

Global alignment is the second sagittal modifier and is assessed by SVA. As indicated earlier, SVA should be greater than 40 mm of PI, consequently patients with SVA less than 40 mm are assigned the global alignment modifier 0. Patients with SVA between 40 and 95 mm are assigned global alignment modifier +, and patients with SVA greater than 95 mm are assigned global alignment modifier ++.

Pelvic tilt is the third sagittal modifier. As indicated earlier, PT greater than 20° reflects compensatory pelvic retroversion to maintain upright posture, and has also correlated with pain and disability. Patients with PT less than 20° are assigned PT modifier 0. Patients with PT between 20° and 30° are assigned PT modifier +, and

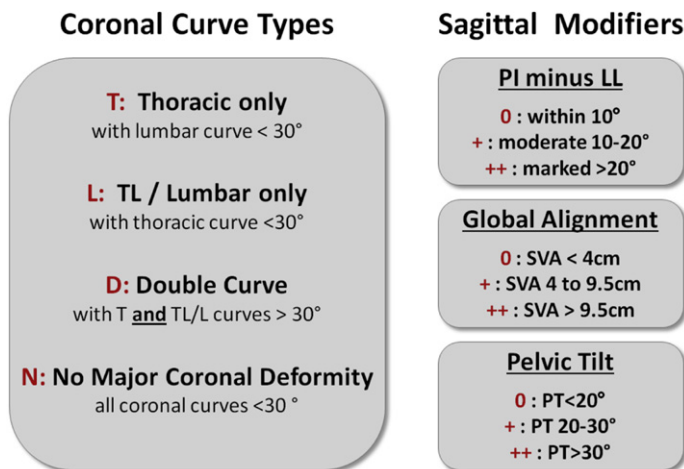


**Fig. 3.** Sagittal spinopelvic parameters. PI, the angle between the line drawn perpendicular to the sacral end plate at its midpoint and the line drawn from the midpoint of the sacral end plate to the midpoint of the bicoxofemoral axis; PT, the angle between the line connecting the midpoint of the sacral end plate to the midpoint of the bicoxofemoral axis and the vertical; and SS, the angle between the horizontal and the upper sacral endplate. (Adapted from Schwab F, Patel A, Ungar B, et al. Adult spinal deformity-postoperative standing imbalance: how much can you tolerate? An overview of key parameters in assessing alignment and planning corrective surgery. *Spine (Phila Pa 1976)* 2010;35:2224–31; with permission.)

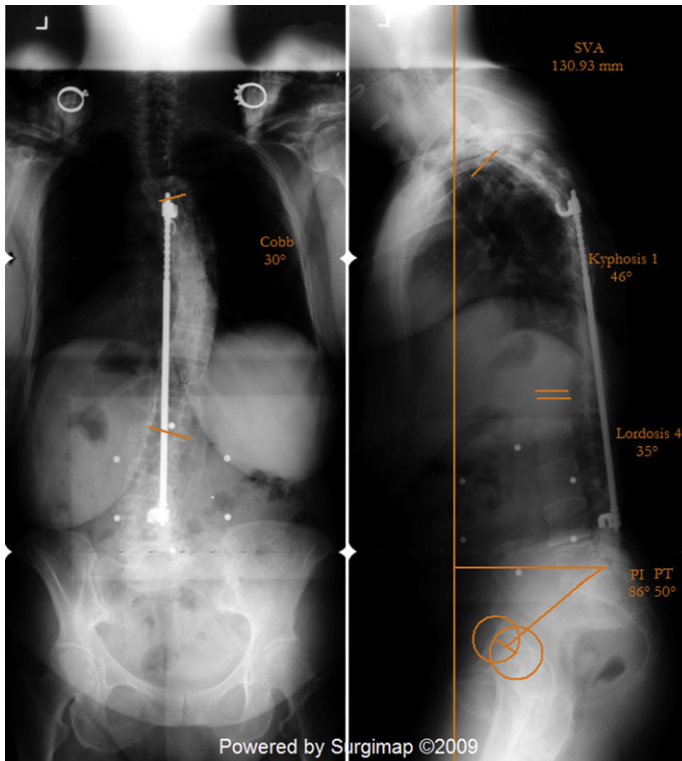
patients with PT greater than  $30^\circ$  are assigned PT modifier ++ (Figs. 5 and 6).

In addition to correlating with pain and disability, the sagittal modifiers can be used as a guideline for surgical planning, because the modifiers provide an objective measure for the amount of sagittal spinopelvic deformity. Patients with a PI-LL modifier ++, by definition, require an addition of at least  $10^\circ$  of LL to restore the normal physiologic relationship between PI and LL. The global alignment and PT modifiers, together, also provide a guide for surgical planning, by denoting the amount of sagittal plane deformity and compensatory mechanisms the patient is using to maintain

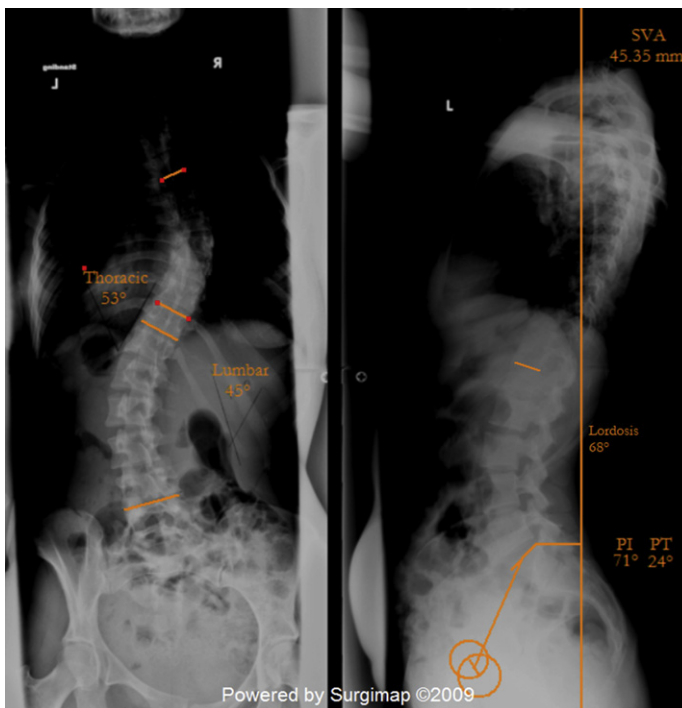
upright posture. Patients with a high SVA and high pelvic tilt have a greater sagittal deformity and require larger sagittal plane correction than patients with high SVA and normal pelvic tilt, because effective correction for the patient with high SVA and high PT requires not only reduction of SVA but also normalization of PT. Evaluation of patients having lumbar pedicle subtraction osteotomy (PSO) showed that PT reduces following PSO procedures; however, high PT is also a risk factor for residual sagittal deformity following PSO.<sup>28</sup> Patients with high PT and high SVA consequently require a greater degree of osteotomy resection at the PSO site and/or a combination



**Fig. 4.** SRS-Schwab ASD Classification. (Adapted from Schwab F, Ungar B, Blondel B, et al. Scoliosis Research Society-Schwab Adult Spinal Deformity Classification: a validation study. *Spine* 2012;37:1077–82; with permission.)



**Fig. 5.** Example of SRS-Schwab ASD Classification. Patient has a thoracic curve of  $30^\circ$ , a PI-LL of  $51^\circ$  (PI =  $86^\circ$ , LL =  $35^\circ$ ), a pelvic tilt of  $50^\circ$ , and an SVA of 13.1 cm. The patient therefore has a classification grade of T, PI-LL++, PT++, SVA++.



**Fig. 6.** Example of SRS-Schwab ASD Classification. Patient has thoracic and lumbar curves greater than  $30^\circ$ , a PI-LL of  $26^\circ$  (PI =  $71^\circ$ , LL =  $68^\circ$ ), a pelvic tilt of  $24^\circ$ , and an SVA of  $-4.5$  cm. The patient therefore has a classification grade of D, PT+.

of other corrective techniques to prevent residual postoperative sagittal deformity.

In order to have practical value, a classification must balance information provided, ease of use, and ability to generate consistent classification ratings for the same user and between users. Initial data on the use of the SRS-Schwab ASD Classification reported good to excellent intrarater reliability (mean kappa score range 0.88–0.97 for curve type and sagittal modifiers; mean kappa total grade 0.87) and good to excellent inter-rater reliability (mean kappa score range 0.75–0.98 for curve type and sagittal modifiers; mean kappa total grade 0.70–0.79), reflecting relative ease of use and consistent user scores.<sup>27</sup> As a consequence of the methodology used to create the classification, the classification has been shown to predict patient disability and patient preference for operative versus nonoperative treatment. Prospective evaluation of a consecutive cohort of operatively and nonoperatively treated patients with ASD using the SRS-Schwab Classification showed that operatively treated patients had worse HRQOL scores and worse sagittal modifier grades on all sagittal modifier categories than patients treated nonoperatively.<sup>29</sup> The classification has also been shown to be responsive to change in disability and disease state as a result of treatment. Smith and colleagues<sup>30</sup> evaluated whether the classification could predict changes in HRQOL values following treatment using a prospective, consecutive cohort of operatively treated patients with ASD. Change in SVA modifier at 1 year was associated with changes in ODI, Short Form 36 (SF-36) physical component score (PCS), and SRS-22 questionnaire total and all subscores. Change in PI-LL modifier at 1 year was associated with changes in SF-36 PCS and SRS-22 total score and subscores. Changes in SVA and PI-LL modifiers were associated with likelihood of achieving minimal clinically important difference for ODI and SRS subscores.

## SUMMARY

Classifications for spinal deformity provide a common language for surgeons, health care providers, and researchers to effectively identify and communicate details regarding specific subsets of the disease state. Most existing spinal deformity classifications are rooted in pediatric spinal deformity, and, more specifically, AIS. Although these classifications have improved care for pediatric patients, the fundamental concepts behind these classifications do not effectively evaluate ASD, and therefore cannot fully describe the diverse disease states of ASD.

A primary goal when treating pediatric spinal deformity is preventing scoliosis progression, therefore the classifications have focused on identifying structural curves most at risk for progression and requiring treatment. Relief of pain and disability is the primary treatment goal for ASD, therefore classifications that describe ASD should identify features most predictive of pain and disability. The clinical impact classifications developed first by Schwab and colleagues and then collaboratively between Schwab and the SRS represent an attempt to communicate these clinical aspects of ASD.

Sagittal spinopelvic alignment has emerged as a critically important concept for ASD, because sagittal spinopelvic malalignment has repeatedly been shown to correlate with pain and disability in ASD. Assessment of sagittal spinopelvic parameters and integration of these parameters into a classification for ASD are consequently as fundamentally important as scoliosis assessment is for AIS classification. The SRS-Schwab ASD Classification assesses deformity in the coronal and sagittal plane, but the distinctive feature of the classification is the use of the sagittal modifiers (PI-LL, SVA, and PT) to both quantify the deformity and correlate with patients' pain. This HRQOL predictive component of the classification has been demonstrated in a prospective cohort of patients with ASD.<sup>29</sup> The classification has also shown responsiveness to changes in disease state, because improvement in sagittal modifiers following deformity correction has been shown to correlate with improvement in HRQOL scores.<sup>30</sup> Further research using the SRS-Schwab ASD Classification will focus on widespread adoption of the classification and further validating the clinical usefulness of the classification by identifying the deformity parameters that are most responsive to different treatment modalities.

## REFERENCES

1. King HA, Moe JH, Bradford DS, et al. The selection of fusion levels in thoracic idiopathic scoliosis. *J Bone Joint Surg Am* 1983;65:1302–13.
2. Cummings RJ, Loveless EA, Campbell J, et al. Interobserver reliability and intraobserver reproducibility of the system of King et al. for the classification of adolescent idiopathic scoliosis. *J Bone Joint Surg Am* 1998;80:1107–11.
3. Lenke LG, Betz RR, Bridwell KH, et al. Intraobserver and interobserver reliability of the classification of thoracic adolescent idiopathic scoliosis. *J Bone Joint Surg Am* 1998;80:1097–106.
4. Lenke LG, Betz RR, Harms J, et al. Adolescent idiopathic scoliosis: a new classification to determine



- extent of spinal arthrodesis. *J Bone Joint Surg Am* 2001;83:1169–81.
5. Bess S, Boachie-Adjei O, Burton D, et al. Pain and disability determine treatment modality for older patients with adult scoliosis, while deformity guides treatment for younger patients. *Spine (Phila Pa 1976)* 2009;34:2186–90.
  6. Glassman SD, Berven S, Bridwell K, et al. Correlation of radiographic parameters and clinical symptoms in adult scoliosis. *Spine (Phila Pa 1976)* 2005;30:682–8.
  7. Schwab F, Dubey A, Pagala M, et al. Adult scoliosis: a health assessment analysis by SF-36. *Spine* 2003;28:602–6.
  8. Schwab FJ, Smith VA, Biserni M, et al. Adult scoliosis: a quantitative radiographic and clinical analysis. *Spine (Phila Pa 1976)* 2002;27:387–92.
  9. Lowe T, Berven SH, Schwab FJ, et al. The SRS classification for adult spinal deformity: building on the King/Moe and Lenke classification systems. *Spine (Phila Pa 1976)* 2006;31:S119–25.
  10. Aebi M. The adult scoliosis. *Eur Spine J* 2005;14:925–48.
  11. Glassman SD, Bridwell K, Dimar JR, et al. The impact of positive sagittal balance in adult spinal deformity. *Spine* 2005;30:2024–9.
  12. Lafage V, Schwab F, Patel A, et al. Pelvic tilt and truncal inclination: two key radiographic parameters in the setting of adults with spinal deformity. *Spine (Phila Pa 1976)* 2009;34:E599–606.
  13. Schwab F, Lafage V, Patel A, et al. Sagittal plane considerations and the pelvis in the adult patient. *Spine (Phila Pa 1976)* 2009;34:1828–33.
  14. Schwab F, Patel A, Ungar B, et al. Adult spinal deformity-postoperative standing imbalance: how much can you tolerate? An overview of key parameters in assessing alignment and planning corrective surgery. *Spine (Phila Pa 1976)* 2010;35:2224–31.
  15. Schwab F, el-Fegoun AB, Gamez L, et al. A lumbar classification of scoliosis in the adult patient: preliminary approach. *Spine (Phila Pa 1976)* 2005;30:1670–3.
  16. Schwab F, Farcy JP, Bridwell K, et al. A clinical impact classification of scoliosis in the adult. *Spine (Phila Pa 1976)* 2006;31:2109–14.
  17. Schwab F, Lafage V, Farcy JP, et al. Surgical rates and operative outcome analysis in thoracolumbar and lumbar major adult scoliosis: application of the new adult deformity classification. *Spine* 2007;32:2723–30.
  18. Sarwahi V, Boachie-Adjei O, Backus SI, et al. Characterization of gait function in patients with postsurgical sagittal (flatback) deformity: a prospective study of 21 patients. *Spine (Phila Pa 1976)* 2002;27:2328–37.
  19. Yang BP, Chen LA, Ondra SL. A novel mathematical model of the sagittal spine: application to pedicle subtraction osteotomy for correction of fixed sagittal deformity. *Spine J* 2008;8:359–66.
  20. Angevine PD, McCormick PC. The importance of sagittal balance: how good is the evidence? *J Neurosurg Spine* 2007;6:101–3 [discussion: 3].
  21. Duval-Beaupere G, Robain G. Visualization on full spine radiographs of the anatomical connections of the centres of the segmental body mass supported by each vertebra and measured in vivo. *Int Orthop* 1987;11:261–9.
  22. Lafage V, Schwab F, Skalli W, et al. Standing balance and sagittal plane spinal deformity: analysis of spinopelvic and gravity line parameters. *Spine (Phila Pa 1976)* 2008;33:1572–8.
  23. Legaye J, Duval-Beaupere G. Sagittal plane alignment of the spine and gravity: a radiological and clinical evaluation. *Acta Orthop Belg* 2005;71:213–20.
  24. Legaye J, Duval-Beaupere G, Hecquet J, et al. Pelvic incidence: a fundamental pelvic parameter for three-dimensional regulation of spinal sagittal curves. *Eur Spine J* 1998;7:99–103.
  25. Schwab F, Lafage V, Patel A, et al. Does vertebral level of pedicle subtraction osteotomy correlate with degree of spinopelvic parameter correction? In: North American Spine Society 23rd Annual Meeting. Austin, September 10-13, 2008.
  26. Schwab F, Bess S, Blondel B, et al. Combined Assessment of pelvic tilt, pelvic incidence/lumbar lordosis mismatch and sagittal vertical axis predicts disability in adult spinal deformity: a prospective analysis. Louisville (KY): Scoliosis Research Society; September 14-17, 2011.
  27. Schwab F, Ungar B, Blondel B, et al. Scoliosis Research Society-Schwab adult spinal deformity classification: a validation study. *Spine* 2012;37:1077–82.
  28. Schwab F, Lafage V, Shaffrey C, et al. Pre-operative pelvic parameters must be considered to achieve adequate sagittal balance after lumbar osteotomy. In: international meeting for advanced spinal techniques. Vienna. July 15-18, 2009.
  29. Schwab F, Lafage V, Shaffrey C, et al. The SRS-Schwab Adult Spinal Deformity Classification: assessment and clinical correlations based on a prospective operative and non-operative cohort. Chicago: Scoliosis Research Society; September 5-8, 2012.
  30. Smith J, Klineberg E, Schwab F, et al. Change in classification grade by the SRS-Schwab Adult Spinal Deformity (ASD) classification predicts impact on health related quality of life (HRQOL) measures: prospective analysis of operative and nonoperative treatment. Chicago: Scoliosis Research Society; September 5-8, 2012.