



## Clinical Research Article

Korean J Anesthesiol 2020;73(5):417-424  
<https://doi.org/10.4097/kja.20269>  
pISSN 2005-6419 • eISSN 2005-7563

Received: May 28, 2020  
Revised: August 2, 2020  
Accepted: August 25, 2020

### Corresponding author:

Jeff C. Gadsden, M.D., FRCPC, FANZCA  
Department of Anesthesiology, Duke  
University Medical Center 2301 Erwin Road  
Durham, NC 27710, USA  
Tel: +1-919-681-6437  
Fax: +1-919-668-6265  
Email: [jeff.gadsden@duke.edu](mailto:jeff.gadsden@duke.edu)  
ORCID: <https://orcid.org/0000-0003-3971-3879>

# The relative analgesic value of a femoral nerve block versus adductor canal block following total knee arthroplasty: a randomized, controlled, double-blinded study

Jeff C. Gadsden<sup>1</sup>, Siddharth Sata<sup>1</sup>, W. Michael. Bullock<sup>1</sup>,  
Amanda H. Kumar<sup>1</sup>, Stuart A. Grant<sup>1</sup>, Joshua R. Dooley<sup>2</sup>

Department of Anesthesiology, <sup>1</sup>Duke University Medical Center, Duke University, Durham,  
<sup>2</sup>University of North Carolina Medical Center, University of North Carolina, Chapel Hill, NC,  
USA

**Background:** Multiple comparative studies report that adductor canal blocks provide similar pain relief to femoral nerve blocks following total knee arthroplasty. However, adductor canal blockade fails to anesthetize several important femoral nerve branches that contribute to knee innervation. We sought to clarify this anatomic discrepancy by performing both blocks in sequence, using patients as their own controls. We hypothesized that patients would experience additional pain relief following a superimposed femoral nerve block, demonstrating that these techniques are not equivalent.

**Methods:** Sixteen patients received continuous adductor canal block before undergoing knee arthroplasty under general anesthesia. In the recovery room, patients reported their pain score on a numeric scale of 0–10. Once a patient reached a score of five or greater, he/she was randomized to receive an additional femoral nerve block using 2% chloroprocaine or saline sham, and pain scores recorded every 5 min for 30 min. Patients received opioid rescue as needed. Anesthesiologists performing and assessing block efficacy were blinded to group allocation.

**Results:** Patients randomized to chloroprocaine versus saline reported significantly improved median pain scores 30 min after the femoral block (2.0 vs. 5.5,  $P < 0.001$ ). Patients receiving chloroprocaine also required significantly fewer morphine equivalents during the 30 min post-femoral block (1.0 vs. 4.5 mg,  $P = 0.032$ ).

**Conclusions:** Adductor canal block is a useful technique for postoperative pain following total knee arthroplasty, but it does not provide equivalent analgesic efficacy to femoral nerve block. Future studies comparing efficacy between various block sites along the thigh are warranted.

**Keywords:** Acute pain; Adductor canal block; Femoral nerve block; Ropivacaine; Total knee arthroplasty; Ultrasound.

## Introduction

Adductor canal block is a common analgesic intervention for postoperative pain control following total knee arthroplasty [1,2]. This block is typically performed by depositing local anesthetic anterolateral to the femoral artery at approximately the mid-thigh in a musculofascial space bounded by the sartorius, adductor longus and vastus medialis muscles. Local anesthetic deposited here anesthetizes the saphenous nerve and the nerve to vastus medialis [2]. Both of these small nerves contribute to sensory innervation of the

© The Korean Society of Anesthesiologists, 2020

© This is an open-access article distributed under the terms of the Creative Commons Attribution license (<http://creativecommons.org/licenses/by/4.0/>), which permits unrestricted use, distribution, and reproduction in any medium, provided the original work is properly cited.

medial knee joint [3]. A principal advantage of the adductor canal block is the relative absence of quadriceps weakness that is almost universal with femoral nerve block [4]. This muscle-sparing quality has been shown to facilitate early ambulation and recovery [5–7], and studies of block use for total knee arthroplasty show that the adductor canal block has largely replaced the femoral nerve block as the regional analgesic modality of choice [1,8].

Multiple investigations have suggested that the analgesic effect of the adductor canal block is equivalent to femoral nerve block following total knee arthroplasty, both in reported pain scores and opioid consumption [9–13]. However, femoral nerve block differs from adductor canal block in the number and distribution of individual nerves blocked. Specifically, the adductor canal block does not anesthetize either the nerve to vastus intermedius or the nerve to vastus lateralis, both of which contribute substantially to the sensory innervation of the knee joint [3,14]. Given this anatomic disparity, the results of the comparative trials [9–13] showing equivalence are somewhat puzzling. We questioned whether comparative studies of femoral nerve block and adductor canal block in separate cohorts of patients represented the most precise method of quantifying the relative analgesic effect of these two block techniques. To test that hypothesis, we designed a prospective, randomized, controlled study to evaluate this question using both blocks in each patient. Our hypothesis was that following total knee arthroplasty, the superimposition of a femoral nerve block to an existing adductor canal block would significantly reduce postoperative pain within 30 min of the intervention. If pain scores did not change after the femoral nerve block, this would support the widely held contention that femoral nerve block and adductor canal block provide equivalent analgesic effect following total knee arthroplasty.

## Materials and Methods

Approval for this prospective, randomized, blinded clinical trial was obtained by the Duke University Institutional Review Board (IRB number: PRO00067430). This study was registered on clinicaltrials.gov, identifier number NCT03395990, on December 18, 2017. The study was conducted in accordance with the Declaration of Helsinki and Good Clinical Practice.

Eligibility criteria for the study were age 56–85, American Society of Anesthesiologists physical status I–III, BMI 18–40 kg/m<sup>2</sup> and undergoing elective primary total knee arthroplasty. Patients were excluded if they had an allergy to local anesthetic, a contraindication to either femoral nerve block or adductor canal block, had chronic opioid consumption (defined as the use of  $\geq$  30 mg morphine equivalents per day in the seven days preceding sur-

gery), had an inability to understand English, or were unable to cooperate with the protocol. All enrolled patients signed a written informed consent. Our primary outcome was pain intensity on an 11-point Numeric Rating Scale (NRS-11) at 30 min following the block intervention. Secondary outcomes included opioid consumption in the post-anesthesia care unit (in morphine milliequivalents), the presence of quadriceps spasm at any time during the post-anesthesia care unit stay, and the reported location of any pain in the knee area before the block and at 30 min following the block intervention.

## Sample size

We defined a significant reduction in pain intensity as three points on a NRS-11. This value was chosen deliberately as is both clinically meaningful and validated as a measure of effectiveness of pain therapy in this population [15,16]. Our hypothesis was that the reported pain intensity would be reduced by three points with a femoral block compared to sham at the 30-minute time point following the block. To power a t-test with an assumed decrease of three points on the NRS-11, a standard deviation of two points at 80% power and an alpha = 0.05, we calculated that 8 patients per group would be required.

## Standard interventions

In the preoperative block area, all patients received oral multimodal analgesia consisting of acetaminophen 975 mg, celecoxib 400 mg, and pregabalin 75 mg. Patients were then sedated with midazolam 2 mg IV and fentanyl 50  $\mu$ g IV before receiving two peripheral nerve blocks in the operative limb. The first was infiltration of 20 ml of 0.2% ropivacaine with 1 : 400,000 epinephrine between the popliteal artery and the capsule of the knee (iPACK) using a technique described by Sinha [17]. Following this, an adductor canal perineural catheter was placed. A high-frequency linear ultrasound transducer (FlexFocus 400, BK medical, USA) was placed on the anteromedial thigh at the midpoint between the inguinal crease and the proximal aspect of the patella. Following skin infiltration with 1% lidocaine, a 100 mm, 18 gauge Tuohy needle (Contiplex B, B.Braun, USA) was inserted in-plane from lateral to medial through the skin and vastus medialis muscle and advanced toward the femoral artery in the plane immediately deep to the sartorius muscle. When the needle tip was directly adjacent to the artery (at approximately the position of the saphenous nerve), a small aliquot (0.5–1 ml) of 0.2% ropivacaine was injected and the ultrasound screen observed for evidence of the bolus adjacent to the artery and saphenous nerve. Small adjust-

ments were made to the needle tip position to obtain this result. Ropivacaine 0.2% 15 ml was then administered through the needle as the primary block, to create a pocket of injectate for the catheter. A 19 gauge perineural catheter was then passed through the needle and the needle withdrawn. The catheter position was adjusted as required until a 1 ml bolus through the catheter demonstrated the spread of injectate on the anterolateral aspect of the artery, directly adjacent to the saphenous nerve. The catheter was then secured to the skin with octylcyanoacrylate surgical glue (Dermabond, Ethicon Inc., USA), Steri-Strip™ wound closures (3M, USA), and a sterile transparent adhesive dressing (Tegaderm™, 3M, USA). The patient was then taken to the operating room for surgery. Each patient received a total of 20 ml of 0.2% ropivacaine for the adductor canal block. The catheter was capped off, and no additional infusate was administered until all of the study interventions were completed in the post-anesthesia care unit. Block success was tested immediately prior to induction of anesthesia by evaluating pinprick sensation on the medial calf just proximal to the medial malleolus using a three-point scale (0 = no sensation; 1 = partial sensation; 2 = full sensation).

General anesthesia was performed in order to rapidly and easily assess the effect of the adductor canal block and study blocks in the post-anesthesia care unit as well as reduce the potential bias from a neuraxial block. Anesthesia was induced with fentanyl 1 µg/kg IV, propofol 2.5 mg/kg IV, and rocuronium 0.6 mg/kg IV. A supraglottic airway was then placed and anesthesia maintained with sevoflurane in an oxygen/air mixture, titrated to a bispectral index of 40–60. Ketamine 0.5 mg/kg IV of ideal body weight (up to a 40 mg maximum) and dexamethasone 10 mg IV were administered before incision as a part of the routine multimodal analgesic regimen. Fentanyl 25 mg IV was administered as needed to maintain heart rate and blood pressure within 20% of baseline. A pneumatic tourniquet was used on the thigh in all cases. Following cementing of the implant, residual neuromuscular blockade was reversed with neostigmine and glycopyrrolate, and ventilation switched from controlled to spontaneous; fentanyl was thereafter titrated in 25 µg aliquots to maintain a respiratory rate of 12–16 breaths/min. At the conclusion of the surgical procedure, sevoflurane was discontinued and the supraglottic airway removed.

## Study interventions

Upon arrival to post-anesthesia care unit, a blinded investigator asked patients to report their pain quality, location, and intensity on the NRS-11 every 5 min. Success of the previously placed adductor canal block was tested again by the absence of sensation to

pinprick on the medial calf. The contralateral calf was also tested as a control. Once the patient's pain intensity reached five or greater or at time = 30 min post-arrival in the post-anesthesia care unit (whichever came first), the femoral nerve block intervention was initiated. We chose a pain intensity trigger of five based on pilot data from our institution demonstrating that knee arthroplasty patients who received general anesthesia and our standard nerve blocks had a mean peak pain score in the recovery room of  $6.2 \pm 1.4$  (NRS scale 0–10).

Patients were randomly allocated into two groups using computer-generated random numbers. The group allocation was concealed in sealed opaque envelopes that were opened by an unblinded investigator prior arrival to the post-anesthesia care unit. Group C patients received a postoperative single-injection femoral nerve block with 15 ml of 2% chloroprocaine, and Group S patients received a sham femoral nerve block with 15 ml of normal saline. The study solution was prepared by the unblinded investigator. Chloroprocaine was chosen as the study local anesthetic so any associated motor block of the quadriceps muscles would resolve quickly and not impair overall recovery and physical therapy.

The ultrasound-guided femoral nerve block was performed by a blinded investigator on the operative limb using a standard technique [4]. A total of 15 ml of the study solution was deposited immediately adjacent to the femoral nerve at the level of the inguinal crease. Following the block procedure, the blinded investigator repeated the pain assessment every 5 min for 30 min. Patients were permitted intravenous hydromorphone in the post-anesthesia care unit 0.2–0.4 mg every 8 min as needed to treat pain intensity greater than five. Sensory testing of the ipsilateral saphenous nerve was repeated at 30 min post-block.

The presence of quadriceps spasm, opioid use in the post-anesthesia care unit, and any opioid-related adverse effects were also recorded.

## Statistical methods

Statistical analysis was performed with SPSS for Windows (Ver. 24.0, IBM Corp., USA). Categorical variables were reported as count and frequency while continuous variables were reported as either mean and standard deviation or median and interquartile range depending on their respective distribution. Due to the low sample size, either Wilcoxon sum rank test or Fishers exact test was used to test the differences between continuous and categorical variables, respectively. The alpha level was set at 0.05 for statistical significance.

## Results

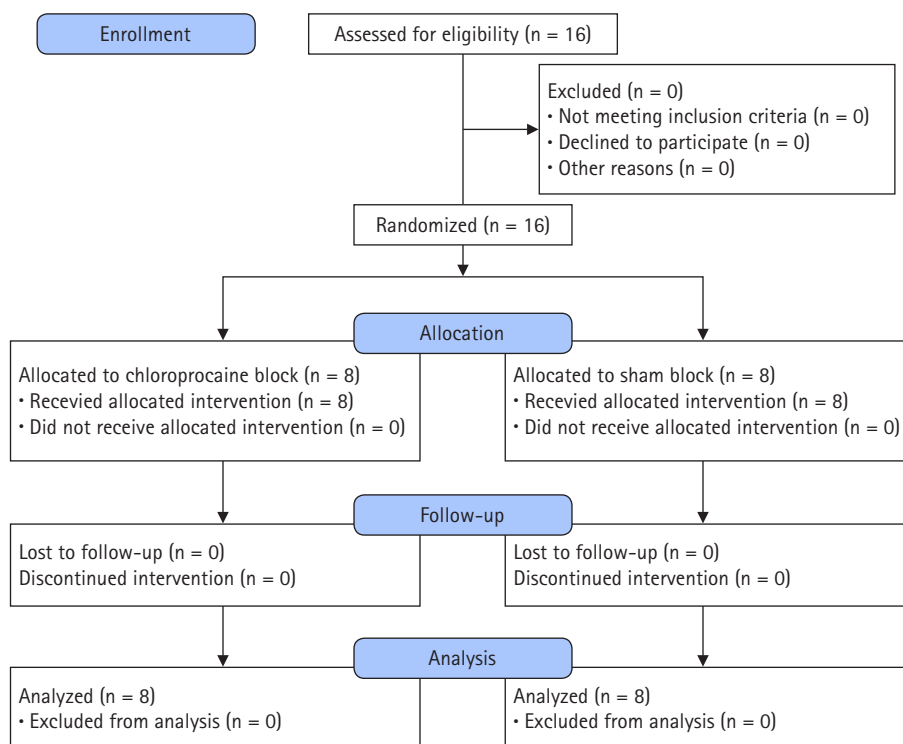
Eight patients were randomized to each group. Patient demographics and pre-intervention data are shown in Table 1 and Fig. 1 depicts the CONSORT flow diagram of patient progress through the study. There were no differences between groups in age, body mass index, laterality of procedure, intraoperative fentanyl use, or time from removal of the supraglottic airway to placement of

block in post-anesthesia care unit. Height and weight were higher in the chloroprocaine group, possibly due to a higher proportion of males. The adductor canal blocks were all successful as demonstrated by the loss of sensation proximal to the medial malleolus prior to induction of general anesthesia as well as in the post-anesthesia care unit. Compared to those receiving sham block (sham group), the patients receiving femoral nerve block with chloroprocaine (chloroprocaine group) experienced a significantly re-

**Table 1.** Characteristics and Pre-intervention Data of Patients Receiving Chloroprocaine (Group C) or Sham (Group S) Femoral Block

	Group C (n = 8)	Group S (n = 8)	P value
Sex (M/F)	2/6	6/2	-
Laterality (left/right)	4/4	2/6	-
Age (yr)	65.5 ± 5.9	68.6 ± 7.8	0.324
Height (cm)	176.1 ± 8.6	162 ± 13.6	0.029*
Weight (kg)	93.3 ± 8.1	77.6 ± 15.7	0.007*
BMI (kg/m <sup>2</sup> )	30.7 ± 1.8	29.5 ± 4.3	0.510
Duration of surgery (incision to removal of supraglottic device) (min)	94.8 ± 11.9	86.3 ± 6.3	0.128
Intraoperative fentanyl (µg)	215.6 ± 99.0	190.6 ± 105.2	0.570
Time from removal of supraglottic airway device to the block in PACU (min)	25.9 ± 7.7	23.8 ± 4.7	0.521
Number of patients who reported pain score 5 (NRS 0–10) in PACU	8 (100)	8 (100)	-
Pre-intervention block success (yes)	8 (100)	8 (100)	-

Values are presented as number of patients or mean ± SD, number (%). BMI: body mass index, PACU: post-anesthesia care unit, NRS: numeric rating scale. \*Presents statistical significance.



**Fig. 1.** CONSORT flow diagram.

duced overall pain intensity. Median pain intensity was similar at the time of block and at 5 min post-block, but the chlorprocaine group showed a significant improvement after 10 min, and this reduction in pain intensity continued until data collection stopped at 30 min, at which point median (IQR) pain intensity was 2.0 (1.5–2.8) vs. 5.5 (4.0–6.5) for the chlorprocaine and sham groups, respectively (Fig. 2).

Intravenous opioid consumption (median morphine milliequivalent in mg [IQR]) during the post-anesthesia care unit stay was significantly lower in the chlorprocaine group (1.0 [0–2.25 mg]) versus the sham group (4.5 [2.5–6 mg],  $P = 0.032$ ). Two patients (one in each group) were identified as having quadriceps spasm pre-block. The spasm was completely relieved by the femoral nerve block in the chlorprocaine group, but not by the sham block. Pre-block knee pain location was characterized by patients as either ‘top of knee/anterior’ (12 patients), ‘diffuse/all over’ (three patients), or ‘medial knee’ (one patient). The primary location of pain remained anterior or diffuse after the femoral nerve block in 14 patients but changed to ‘posterior’ for two patients in the chlorprocaine group.

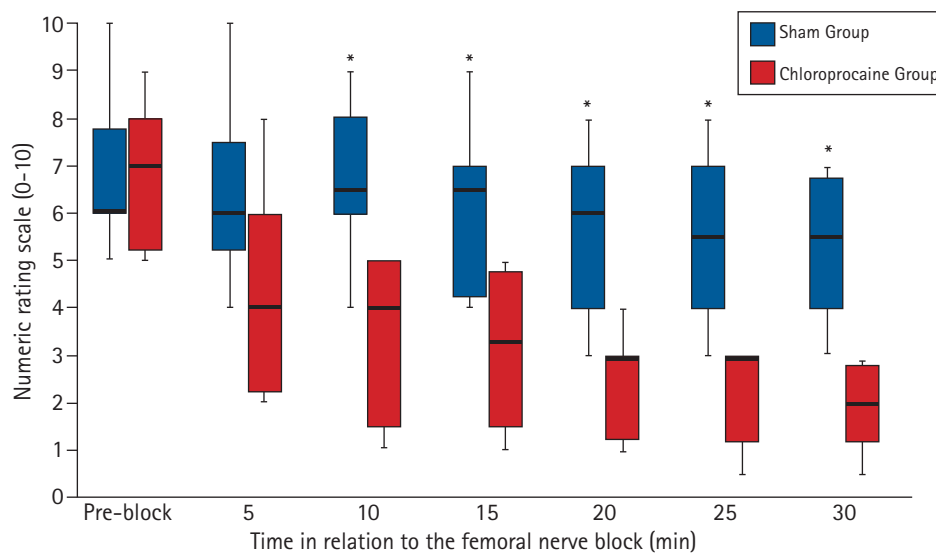
## Discussion

Our results confirm the hypothesis that femoral nerve block and adductor canal block do not provide an equivalent analgesic effect for patients undergoing total knee arthroplasty. In this randomized, double-blinded controlled experiment, we were able to demonstrate that patients who had a carefully conducted and tested adductor canal block were able to benefit by  $> 3$  points on the

NRS-11 when femoral nerve block with chlorprocaine was superimposed, a result that is both statistically significant and clinically meaningful.

These results validate what is known about the innervation of the knee. The adductor canal block is thought to provide an effect by anesthetizing the saphenous nerve and the nerve to vastus medialis [14,18]. Blockade of these two specific nerves is theoretically attractive, as the principal approaches to total knee arthroplasty involve accessing the joint space via a medial (parapatellar, subvastus or midvastus) arthrotomy [19]. In addition, some studies have shown that, depending on the degree of distal spread in the adductor canal, this technique may result in blockade of genicular branch of the obturator nerve, which may provide additional analgesia [14,20].

However, knee arthroplasty involves more than simply incising the joint capsule, and there are multiple sources of postoperative pain that are transmitted by various branches of the femoral nerve. For example, the osteotomies performed on both the tibia and femur as well as the impaction of joint prostheses onto the bone surfaces involve periosteum that is innervated by all of the distal branches of the femoral nerve, including the nerves to vastus intermedius and lateralis [21]. Patellar resurfacing involves periosteum innervated by branches from the nerve to vastus lateralis [22]. Postoperative inflammation and edema of periarticular soft tissues stimulate nociceptive afferents that are transmitted by all branches of the femoral nerve, in addition to the sciatic and obturator nerves. Finally, quadriceps muscle spasm is a known complication following total knee arthroplasty that is associated with severe pain and unlikely to be relieved solely by a targeted



**Fig. 2.** Numeric rating scale (NRS-11) pain scores prior to and after the block intervention. Values are presented as median with error bars showing interquartile range. Chlorprocaine block (red), Sham block (blue). \* $P < 0.05$ .

block of the nerve to vastus medialis [23].

The femoral nerve block, which for many years was the gold standard analgesic therapy for total knee arthroplasty, relieves pain through blockade of its three principal motor/articular branches (nerves to vastus medialis, intermedius, and lateralis) as well as the saphenous nerve, and the intermediate and medial cutaneous nerves of the thigh. The articular, osteal, musculofascial, and cutaneous structures of the knee joint are innervated by a complex combination of all of these (in addition to sciatic and obturator branches) [3], and the contention that blockade of just two branches is equivalent to blockade of every branch of the femoral nerve is anatomically questionable [3,24].

Our patients served as their own controls, eliminating inter-rater variability as a confounder. Comparing pain intensity between two groups can be challenging due to the subjective nature of pain, especially when extensive multimodal therapies are employed [25]. Our methodology permitted the patients to ‘anchor’ their pain intensity after receiving an effective adductor canal block, and immediately prior to the femoral nerve block, allowing a meaningful determination of the effect, if any, of the intervention. We clearly observed two distinct patterns of pain intensity: patients in the chlorprocaine group experienced a linear decrease in pain intensity over the subsequent 30 min, whereas the median pain score in the sham group remained virtually unchanged. This finding verifies our contention that there is a significant analgesic value to the femoral nerve block above and beyond that achieved with adductor canal block alone. The fact that pain scores in the sham group showed little change, while receiving significantly more opioids in post-anesthesia care unit, only strengthens our conclusion that femoral nerve block provides superior analgesia to adductor canal block after total knee arthroplasty.

Indeed, not all studies of adductor canal block show equivalency to femoral nerve block. Memtsoudis et al. [26] performed both adductor canal and femoral nerve blocks (one in each thigh) in 60 patients undergoing bilateral total knee arthroplasty. Although overall pain scores on the visual analogue scale were similar at all time points, at 24 h, a significant proportion of patients reported more pain in the limb that had received an adductor canal block compared to the limb that received a femoral nerve block (50.9% vs. 25.4%,  $P = 0.017$ ). In addition, a Cochrane database review of 8 trials comparing adductor canal block versus sham block revealed no differences in postoperative pain intensity at rest or with movement [27]. Moreover, multiple studies have reported that while maximum voluntary isometric contraction force of the quadriceps is preserved with adductor canal block, there is no clinical difference in ambulation or rehabilitation outcomes between adductor canal block and femoral nerve block [10,13,28–

30]. Finally, long-term outcomes may also differ depending on the block used: in a retrospective study of over 5,900 patients undergoing unilateral total knee arthroplasty, the use of adductor canal block (vs. femoral nerve block) was associated with 2.87 (95% CI: 1.00–8.26) increased odds of developing persistent postoperative pain, a finding that supports the notion that there is a difference in the overall quality of acute pain control each technique provides [31].

Our study has several limitations. Firstly, our blocks were performed at mid-thigh. There exists some controversy as to the optimal location on the thigh for adductor canal block (as well as the nomenclature) [9,14], but since this is the approach that most investigators report [10,32–34], we determined it was a valid model. Notwithstanding, our results should be interpreted with this specific anatomic location in mind, and we cannot be certain that femoral nerve block would be superior to an adductor canal block performed at a substantially more proximal location. Secondly, we employed a general anesthetic in order to quickly evaluate the effect of our intervention. While this avoided the confounding effect of a neuraxial block, it may limit the interpretation of our results in cases where a spinal anesthetic is used and the pain experience is potentially less abrupt. Thirdly, we used 2% chlorprocaine at the femoral nerve in order to produce a short-acting block and prevent any extended quadriceps motor weakness, since our practice is to have patients ambulate within 1 to 2 h of surgery. It is possible that the chlorprocaine produced a different sensory effect than would have a femoral block using 0.2% ropivacaine. Finally, we only investigated the relative pain intensity and opioid consumption, so we cannot comment on the effect of femoral nerve block versus adductor canal block on any other outcomes. Certainly, there are surgical and anesthetic imperatives to providing motor-sparing blocks in order to enhance and accelerate recovery. We are not advocating for an abandonment of the adductor canal block for total knee replacement in favor of femoral nerve block as there is clearly a central place for this motor-sparing block in modern knee arthroplasty practice, especially with an increasing number of outpatient knee replacement procedures being performed. Rather, our research question was whether these two techniques, in fact, provide the same analgesia under very controlled conditions. Despite what appears to be the prevailing trend in the literature, the answer seems to be that these blocks are quite different in terms of pain relief.

In conclusion, the femoral nerve block confers superior analgesia following total knee arthroplasty compared to adductor canal block. While the adductor canal block is motor-sparing, it also appears to be partially sensory-sparing, as confirmed by the anatomic facts as well as our results. Further research into the role of

femoral nerve block versus adductor canal block for populations at particularly high risk for prolonged pain and/or opioid use is indicated, as well as the comparative value of femoral nerve block with adductor canal block when performed at various locations along the thigh.

## Acknowledgements

The authors wish to thank John Hunting, MPH for his invaluable assistance with the statistics.

## Conflicts of Interest

No potential conflict of interest relevant to this article was reported.

## Author Contributions

Jeff C. Gadsden (Conceptualization; Data curation; Methodology; Project administration; Writing – original draft; Writing – review & editing)

Siddharth Sata (Conceptualization; Investigation; Methodology; Project administration; Writing – review & editing)

W. Michael. Bullock (Project administration; Writing – review & editing)

Amanda H. Kumar (Writing – review & editing)

Stuart A. Grant (Investigation; Methodology; Project administration; Writing – review & editing)

Joshua R. Dooley (Investigation; Project administration; Writing – review & editing)

## ORCID

Jeff C. Gadsden, <https://orcid.org/0000-0003-3971-3879>

Siddharth Sata, <https://orcid.org/0000-0002-8630-1861>

W. Michael. Bullock, <https://orcid.org/0000-0002-8088-8390>

Amanda H. Kumar, <https://orcid.org/0000-0002-3571-0788>

Stuart A. Grant, <https://orcid.org/0000-0001-9214-5175>

Joshua R. Dooley, <https://orcid.org/0000-0002-4147-8233>

## References

- Masaracchia MM, Herrick MD, Barrington MJ, Hartmann PR, Sites BD. Adductor canal blocks: changing practice patterns and associated quality profile. *Acta Anaesthesiol Scand* 2017; 61: 224-31.
- Bauer MC, Pogatzki-Zahn EM, Zahn PK. Regional analgesia

techniques for total knee replacement. *Curr Opin Anaesthesiol* 2014; 27: 501-6.

- Tran J, Peng PW, Lam K, Baig E, Agur AMR, Gofeld M. Anatomical study of the innervation of anterior knee joint capsule: implication for image-guided intervention. *Reg Anesth Pain Med* 2018; 43: 407-14.
- Kwofie MK, Shastri UD, Gadsden JC, Sinha SK, Abrams JH, Xu D, et al. The effects of ultrasound-guided adductor canal block versus femoral nerve block on quadriceps strength and fall risk: a blinded, randomized trial of volunteers. *Reg Anesth Pain Med* 2013; 38: 321-5.
- Shah NA, Jain NP. Is continuous adductor canal block better than continuous femoral nerve block after total knee arthroplasty? Effect on ambulation ability, early functional recovery and pain control: a randomized controlled trial. *J Arthroplasty* 2014; 29: 2224-9.
- Kuang MJ, Ma JX, Fu L, He WW, Zhao J, Ma XL. Is adductor canal block better than femoral nerve block in primary total knee arthroplasty? A GRADE analysis of the evidence through a systematic review and meta-analysis. *J Arthroplasty* 2017; 32: 3238-48.
- Li D, Yang Z, Xie X, Zhao J, Kang P. Adductor canal block provides better performance after total knee arthroplasty compared with femoral nerve block: a systematic review and meta-analysis. *Int Orthop* 2016; 40: 925-33.
- Hannon CP, Keating TC, Lange JK, Ricciardi BF, Waddell BS, Della Valle CJ. Anesthesia and analgesia practices in total joint arthroplasty: a survey of the American Association of Hip and Knee Surgeons Membership. *J Arthroplasty* 2019; 34: 2872-7.
- Meier AW, Auyong DB, Yuan SC, Lin SE, Flaherty JM, Hanson NA. Comparison of continuous proximal versus distal adductor canal blocks for total knee arthroplasty: a randomized, double-blind, noninferiority trial. *Reg Anesth Pain Med* 2018; 43: 36-42.
- Jæger P, Zaric D, Fomsgaard JS, Hilsted KL, Bjerregaard J, Gyrn J, et al. Adductor canal block versus femoral nerve block for analgesia after total knee arthroplasty: a randomized, double-blind study. *Reg Anesth Pain Med* 2013; 38: 526-32.
- Kim DH, Lin Y, Goytizolo EA, Kahn RL, Maalouf DB, Manohar A, et al. Adductor canal block versus femoral nerve block for total knee arthroplasty. *Anesthesiology* 2014; 120: 540-50.
- Grevstad U, Mathiesen O, Valentiner LS, Jaeger P, Hilsted KL, Dahl JB. Effect of adductor canal block versus femoral nerve block on quadriceps strength, mobilization, and pain after total knee arthroplasty. *Reg Anesth Pain Med* 2015; 40: 3-10.
- Wiesmann T, Piechowiak K, Duderstadt S, Haupt D, Schmitt J, Eschbach D, et al. Continuous adductor canal block versus con-

- tinuous femoral nerve block after total knee arthroplasty for mobilisation capability and pain treatment: a randomised and blinded clinical trial. *Arch Orthop Trauma Surg* 2016; 136: 397-406.
14. Burckett-St Laurant D, Peng P, Girón Arango L, Niazi AU, Chan VW, Agur A, et al. The nerves of the adductor canal and the innervation of the knee: an anatomic study. *Reg Anesth Pain Med* 2016; 41: 321-7.
  15. Farrar JT, Berlin JA, Strom BL. Clinically important changes in acute pain outcome measures: a validation study. *J Pain Symptom Manage* 2003; 25: 406-11.
  16. Danoff JR, Goel R, Sutton R, Maltenfort MG, Austin MS. How much pain is significant? Defining the minimal clinically important difference for the visual analog scale for pain after total joint arthroplasty. *J Arthroplasty* 2018; 33: S71-5.
  17. Sinha SK, Suter S. New blocks for the same old joints. *Curr Opin Anaesthesiol* 2018; 31: 630-5.
  18. Grevstad U, Jæger P, Sørensen JK, Gottschau B, Ilfeld B, Ballegaard M, et al. The effect of local anesthetic volume within the adductor canal on quadriceps femoris function evaluated by electromyography. *Anesth Analg* 2016; 123: 493-500.
  19. Liu HW, Gu WD, Xu NW, Sun JY. Surgical approaches in total knee arthroplasty: a meta-analysis comparing the midvastus and subvastus to the medial peripatellar approach. *J Arthroplasty* 2014; 29: 2298-304.
  20. Runge C, Moriggl B, Børglum J, Bendtsen TF. The spread of ultrasound-guided injectate from the adductor canal to the genicular branch of the posterior obturator nerve and the popliteal plexus: a cadaveric study. *Reg Anesth Pain Med* 2017; 42: 725-30.
  21. Brooks P. Seven cuts to the perfect total knee. *Orthopedics* 2009; 32. Available from <https://doi.org/10.3928/01477447-20090728-27>.
  22. Maralcan G, Kuru I, Issi S, Esmer AF, Tekdemir I, Evcik D. The innervation of patella: anatomical and clinical study. *Surg Radiol Anat* 2005; 27: 331-5.
  23. Anastase DM, Cionac Florescu S, Munteanu AM, Ursu T, Stoica CI. Analgesic techniques in hip and knee arthroplasty: from the daily practice to evidence-based medicine. *Anesthesiol Res Pract* 2014; 2014: 569319.
  24. Egeler C, Jayakumar A, Ford S. Adductor canal block is useful but does not achieve a complete block of the knee. *Reg Anesth Pain Med* 2014; 39: 81-2.
  25. Agostinho M, Canaipa R, Honigman L, Treister R. No relationships between the within-subjects' variability of pain intensity reports and variability of other bodily sensations reports. *Front Neurosci* 2019; 13: 774.
  26. Memtsoudis SG, Yoo D, Stundner O, Danninger T, Ma Y, Poultsides L, et al. Subartorial adductor canal vs femoral nerve block for analgesia after total knee replacement. *Int Orthop* 2015; 39: 673-80.
  27. Schnabel A, Reichl SU, Weibel S, Zahn PK, Kranke P, Pogatzki-Zahn E, et al. Adductor canal blocks for postoperative pain treatment in adults undergoing knee surgery. *Cochrane Database Syst Rev* 2019; 2019: CD012262.
  28. Runner RP, Boden SA, Godfrey WS, Premkumar A, Samady H, Gottschalk MB, et al. Quadriceps strength deficits after a femoral nerve block versus adductor canal block for anterior cruciate ligament reconstruction: a prospective, single-blinded, randomized trial. *Orthop J Sports Med* 2018; 6: 2325967118797990.
  29. Brennan PT, Villa JM, Rossi MD, Sanchez-Gonzalez MA, Lavernia CJ. Rehabilitation outcomes for total knee arthroplasties: continuous adductor canal block versus continuous femoral nerve block. *Geriatr Orthop Surg Rehabil* 2018; 9: 2151458518756190.
  30. Elkassabany NM, Antosh S, Ahmed M, Nelson C, Israelite C, Badiola I, et al. The risk of falls after total knee arthroplasty with the use of a femoral nerve block versus an adductor canal block: a double-blinded randomized controlled study. *Anesth Analg* 2016; 122: 1696-703.
  31. Gungor S, Fields K, Aiyer R, Valle AG, Su EP. Incidence and risk factors for development of persistent postsurgical pain following total knee arthroplasty: a retrospective cohort study. *Medicine (Baltimore)* 2019; 98: e16450.
  32. Jæger P, Nielsen ZJK, Henningsen MH, Hilsted KL, Mathiesen O, Dahl JB. Adductor canal block versus femoral nerve block and quadriceps strength. *Anesthesiology* 2013; 118: 409-15.
  33. Hanson NA, Allen CJ, Hostetter LS, Nagy R, Derby RE, Slee AE, et al. Continuous ultrasound-guided adductor canal block for total knee arthroplasty: a randomized, double-blind trial. *Anesth Analg* 2014; 118: 1370-7.
  34. Monahan AM, Sztain JF, Khatibi B, Furnish TJ, Jæger P, Sessler DI, et al. Continuous adductor canal blocks: does varying local anesthetic delivery method (automatic repeated bolus doses versus continuous basal infusion) influence cutaneous analgesia and quadriceps femoris strength? a randomized, double-masked, controlled, split-body volunteer study. *Anesth Analg* 2016; 122: 1681-8.