

Assessment of Symptomatic Rod Fracture After Posterior Instrumented Fusion for Adult Spinal Deformity

Justin S. Smith, MD, PhD*
 Christopher I. Shaffrey, MD*
 Christopher P. Ames, MD‡
 Jason Demakakos, MS¶
 Kai-Ming G. Fu, MD, PhD||
 Sassan Keshavarzi, MD#
 Carol M. Y. Li, BA‡
 Vedat Deviren, MDS
 Frank J. Schwab, MD¶
 Virginie Lafage, PhD¶
 Shay Bess, MD**
 International Spine Study
 Group

*Department of Neurosurgery, University of Virginia, Charlottesville, Virginia; Departments of ‡Neurological Surgery and §Orthopaedic Surgery, University of California, San Francisco, San Francisco, California; ¶Department of Orthopaedic Surgery, NYU Hospital for Joint Diseases, New York, New York; ||Department of Neurosurgery, Weill Cornell Medical College, New York, New York; #Department of Neurosurgery, University of California, San Diego, San Diego, California; **Rocky Mountain Hospital for Children, Denver, Colorado

Correspondence:

Justin S. Smith, MD, PhD,
 Department of Neurosurgery,
 University of Virginia Health Sciences
 Center, PO Box 800212,
 Charlottesville, VA 22908.
 E-mail: jss7f@virginia.edu

Received, February 25, 2012.

Accepted, June 20, 2012.

Published Online, July 11, 2012.

Copyright © 2012 by the
 Congress of Neurological Surgeons

BACKGROUND: Improved understanding of rod fracture (RF) in adult spinal deformity could be valuable for implant design, surgical planning, and patient counseling.

OBJECTIVE: To evaluate symptomatic RF after posterior instrumented fusion for adult spinal deformity.

METHODS: A multicenter, retrospective review of RF in adult spinal deformity was performed. Inclusion criteria were spinal deformity, age older than 18 years, and more than 5 levels posterior instrumented fusion. Rod failures were divided into early (≤ 12 months) and late (> 12 months).

RESULTS: Of 442 patients, 6.8% had symptomatic RF. RF rates were 8.6% for titanium alloy, 7.4% for stainless steel, and 2.7% for cobalt chromium. RF incidence after pedicle subtraction osteotomy (PSO) was 15.8%. Among patients with a PSO and RF, 89% had RF at or adjacent to the PSO. Mean time to early RF (63%) was 6.4 months (range, 2-12 months). Mean time to late RF (37%) was 31.8 months (range, 14-73 months). The majority of RFs after PSO (71%) were early (mean, 10 months). Among RF cases, mean sagittal vertical axis improved from preoperative (163 mm) to postoperative (76.9 mm) measures ($P < .001$); however, 16 had postoperative malalignment (sagittal vertical axis > 50 mm; mean, 109 mm).

CONCLUSION: Symptomatic RF occurred in 6.8% of adult spinal deformity cases and in 15.8% of PSO patients. The rate of RF was lower with cobalt chromium than with titanium alloy or stainless steel. Early failure was most common after PSO and favored the PSO site, suggesting that RF may be caused by stress at the PSO site. Postoperative sagittal malalignment may increase the risk of RF.

KEY WORDS: Adult, Complication, Fracture, Instrumentation failure, Pedicle subtraction osteotomy, Spinal deformity, Surgery

Neurosurgery 71:862–868, 2012

DOI: 10.1227/NEU.0b013e3182672aab

www.neurosurgery-online.com

Advances in spinal instrumentation have enabled greater correction of spinal deformities and increased fusion rates. Instrumentation failures, however, continue to be problematic and remain poorly understood.¹⁻⁵ The inherent limitations of the durability of spinal implants have been well described, from the early systems of Harrington and Luque^{6,7} to the current systems of segmental pedicle screws and rods.⁸⁻¹²

The occurrence of rod fracture (RF) can have substantial impact on the patient. It may risk the

development of pseudarthrosis if it occurs early, or it may reflect instrumentation fatigue resulting from pseudarthrosis. Pain and loss of deformity correction may also be associated with RF. Of substantial impact on the patient is the frequent need to undergo revision surgery in the setting of RF. Although there are no standard criteria of when to use the various rod metal compositions, the added rigidity of cobalt chromium rods, compared with titanium alloy rods, has been suggested to be of benefit for constructs exposed to high stress, such as multilevel fusions and osteotomies.¹³

A limited number of previous reports have noted the rates of RF associated with modern posterior instrumentation for spinal deformity.^{1,2,4,5,14-21} These previous reports have many limitations,

ABBREVIATIONS: BMI, body mass index; PSO, pedicle subtraction osteotomy; RF, rod fracture

including relatively small numbers of patients, inclusion of patients restricted to a single surgeon or institution, or only inclusion of patients operated on with a specific surgical procedure or type of instrumentation. In addition, previous reports rarely include indication of rod composition or diameter, and cases of RF are rarely discussed beyond noting their occurrence.

Improved understanding of the rates of RF and potential factors associated with the occurrence of these fractures could be valuable for the design of improved implants, surgical planning, and patient counseling. Our objective was to evaluate the etiology, rates, and time course of symptomatic RF after multilevel posterior instrumented fusion for adult spinal deformity.

METHODS

Patient Population

This study was a multicenter retrospective review of posterior RF after surgical treatment for adult spinal deformity during a 6-year time period (2004-2010) from 3 contributing sites. Adult spinal deformity was defined based on the presence of at least 1 of the following: coronal Cobb angle greater than 20 degrees, sagittal vertical axis (plumbline from C7 to S1) greater than 50 mm, thoracic kyphosis greater than 60 degrees, pelvic tilt greater than 25 degrees, and lumbar lordosis greater than 20 degrees. Inclusion criteria for the current study included age older than 18 years and surgical treatment for adult spinal deformity that included 5 or more levels of posterior instrumented spinal fusion. Exclusion criteria included spinal fusion for posttraumatic or neuromuscular deformity, tumor, or infection. All patients had either a minimum of 1 year of postoperative follow-up or were identified as having early RF that occurred before 1 year of postoperative follow-up. All patients who met the inclusion criteria were included for analysis.

Symptomatic RFs were defined as those in which patients presented with symptoms referable to and prompting evaluation that demonstrated RF; these symptoms included pain, prominence at the surgical site, and/or worsening spinal deformity with loss of correction. Fractures noted in a purely incidental fashion and without apparent symptoms referable to the fracture were not included in these analyses. This study was approved by the institutional review boards of all participating institutions.

Data Collection

For all patients meeting inclusion criteria, surgical records and case logs were reviewed. A more comprehensive review of the clinical and surgical records was performed for the patients demonstrating a symptomatic RF. For patients demonstrating RF, the data evaluated included baseline demographics, details of the index surgical procedure, change in sagittal vertical axis after the index procedure, time to presentation with symptomatic RF, symptoms and circumstances associated with RF, level(s) of RF, whether one or both rods were fractured, and management of the RF. Rod failures were divided into early (<12 months) and late (>12 months) failures.

Statistical Analysis

Frequency distributions and summary statistics were calculated for all clinical, operative, and radiographic variables. For categorical variables, cross-tabulations were generated, and the Fisher exact or Pearson χ^2 test

were used to compare distributions. For continuous variables, *t* tests were used to investigate differences between subsets of patients classified by categorical data. Statistical analyses were 2 sided, and *P* < .05 was considered statistically significant.

RESULTS

Patient Population

A total of 442 surgically treated patients met inclusion criteria for adult spinal deformity based on preoperative imaging. Rod composition and diameter were as follows: 210 titanium alloy (5.5 mm [n = 128], 6.0 mm [n = 69], and 6.35 mm [n = 13]), 122 stainless steel (5.5 mm [n = 112] and 6.35 mm [n = 10]), and 110 cobalt chromium (5.5 mm [n = 52] and 6.0 mm [n = 58]). Asymptomatic RF developed in 30 of 442 patients (6.8%). Rates of RF were not significantly different based on composition when comparing across all 3 compositions (*P* = .136), when comparing titanium alloy and stainless steel (*P* = .836), and when comparing stainless steel and cobalt chromium (*P* = .142). There was a nonsignificant trend toward lower fracture rates with cobalt chromium compared with titanium alloy (*P* = .056).

The mean age of patients with symptomatic RF was 61 years (range, 29-79 years), and the group included 13 men and 17 women. Surgical diagnoses included scoliosis (n = 21; 70%) and positive sagittal malalignment (n = 26; 87%). The upper instrumented vertebra was cephalad to T6 in 20 patients (67%), and 26 patients (87%) had terminal pelvic fixation.

Baseline height and weight were recorded for 28 and 22 of the patients with RF, respectively. For the patients with documented measures, the mean height was 1.66 m (range, 1.52-1.88 m), and the mean weight was 85.2 kg (range, 52.7-120.5 kg). For the 22 patients with both height and weight assessments available, the mean body mass index (BMI) was 30.0 (range, 17.6-41.4), corresponding to a BMI category of obese.

Pain was the primary symptom in 29 patients (97%) with symptomatic RF. The remaining patient (n = 1; 3%) reported progressively worsening positive sagittal malalignment. Postoperative loss of deformity correction was also noted in 5 additional patients. Eleven patients (37%) noted a "cracking" or "popping" noise in the back immediately preceding development of pain. In 3 of these patients, this noise was preceded by a fall from standing, and in another patient it was preceded by bending forward.

Analysis of RF Patients

Figure 1 provides a summary of the 30 patients who developed symptomatic RF, including the rod composition and diameter. Rod composition in fracture cases included titanium alloy (n = 18), stainless steel (n = 9), and cobalt chromium (n = 3). The distribution of rod diameters included 5.5 mm (n = 22), 6.0 mm (n = 2), and 6.35 mm (n = 6). Based on all 442 patients meeting inclusion criteria, the rates of RF based on composition were 8.6% for titanium alloy, 7.4% for stainless steel, and 2.7% for

cobalt chromium. Based on rod diameter, these rates were 7.6% for 5.5-mm rods and 5.3% for 6.0- or 6.35-mm rods.

The majority of RFs occurred in the lumbar spine or thoracolumbar junction (n = 26; 87%; Figure 1). A unilateral RF was identified in 21 (70%) patients, and bilateral RF was identified in the remaining patients, including 3 patients in whom the 2 rods were fractured at different vertebral levels. One or more crosslinks were placed in 22 of 30 patients. In 3 patients, RF occurred at the level of a crosslink (Figure 1: patients 19, 25, 28). Interbody grafting was performed at 1 or more levels in the majority of patients for anterior column support and enhanced arthrodesis. Despite interbody grafting, RF occurred at a level corresponding to the interbody graft in 6 of 8 patients treated with anterior lumbar interbody fusion and in 3 of 8 patients treated with transforaminal lumbar interbody fusion.

Pedicle subtraction osteotomy (PSO) was performed in 114 (25.8%) of the total 442 patients who met inclusion criteria. Of the 30 cases complicated by symptomatic RF, 18 (60%) of the patients had at least 1 PSO. Although the overall rate of symptomatic RF in this series was 6.8%, the incidence of RF after PSO was 15.8% (18 of 114 patients). RF occurred at or adjacent to the level of the PSO site in 16 (89%) of the total 18 patients with a PSO. The rate of RF in patients with a PSO based on rod composition was 7.0% for cobalt chromium, 17% for stainless steel, and 25% for titanium alloy.

Figure 2 provides a graphical summary of the time that elapsed between surgery and development of RF. The overall mean time from surgery to development of symptomatic RF was 15.7 months (range, 2-73 months). Early RFs occurred in 19 (63%) of the patients at a mean of 6.4 months (range,

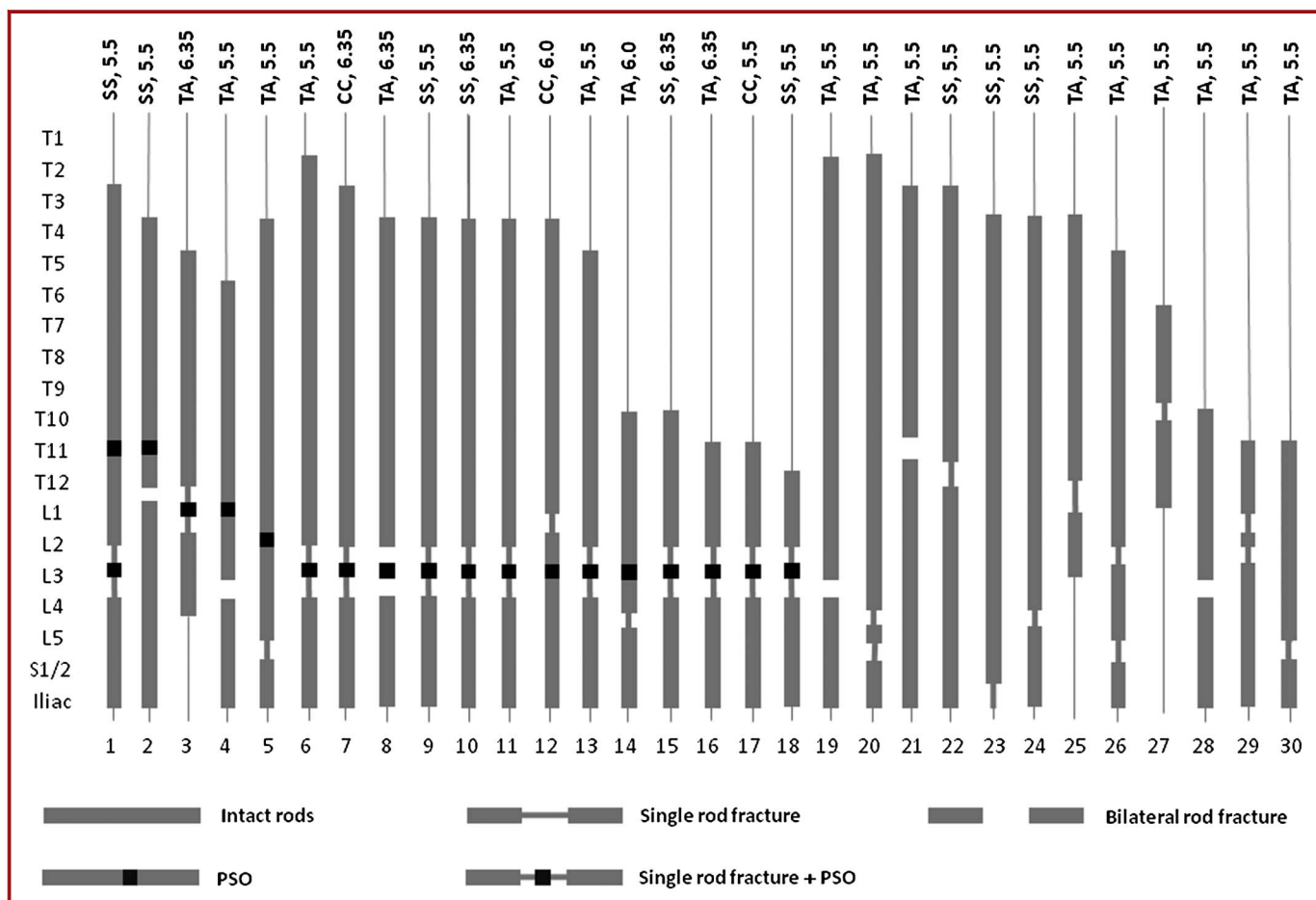


FIGURE 1. Rod composition, diameter, and location(s) of rod fracture(s) encountered in 30 adults treated surgically for spinal deformity. Distributed vertically along the left side are spinal levels, including thoracic (T) and lumbar (L), as well as the sacrum (S) and ilium. Each vertically oriented bar indicates a separate patient, and the extent of the gray bar reflects the levels instrumented and arthrodesed. Vertical gaps in the bars reflect locations of rod fracture, and gaps spanned by a single vertical line indicate that only 1 of the rods fractured, whereas gaps without a spanning vertical line indicate that both rods fractured. For patients with a pedicle subtraction osteotomy, the levels of these osteotomies are indicated by solid black squares. The rod composition, including stainless steel (SS), titanium alloy (TA), and cobalt chromium (CC), and the rod diameter (mm) are indicated along the top of the figure. Patients 20, 26, and 29 have single rod fractures indicated at different levels; for each of these patients, both rods were fractured, 1 side at 1 of the levels and the contralateral side at the other level.

2-12 months), and late RFs occurred in 11 (37%) of the patients at a mean of 31.8 months (range, 14-73 months). The majority of rod failures after PSO (n = 12; 71%) were early failures (mean, 10 months; range, 2.0-29.3 months).

Among the RF patients, the sagittal vertical axis improved from preoperative (mean, 163 mm, range, 0-300 mm) to postoperative (mean, 76.9 mm; range, -25-233 mm) measures ($P < .001$); however, 16 patients had residual postoperative sagittal malalignment (sagittal vertical axis >50 mm; mean, 109 mm; range, 50-233 mm).

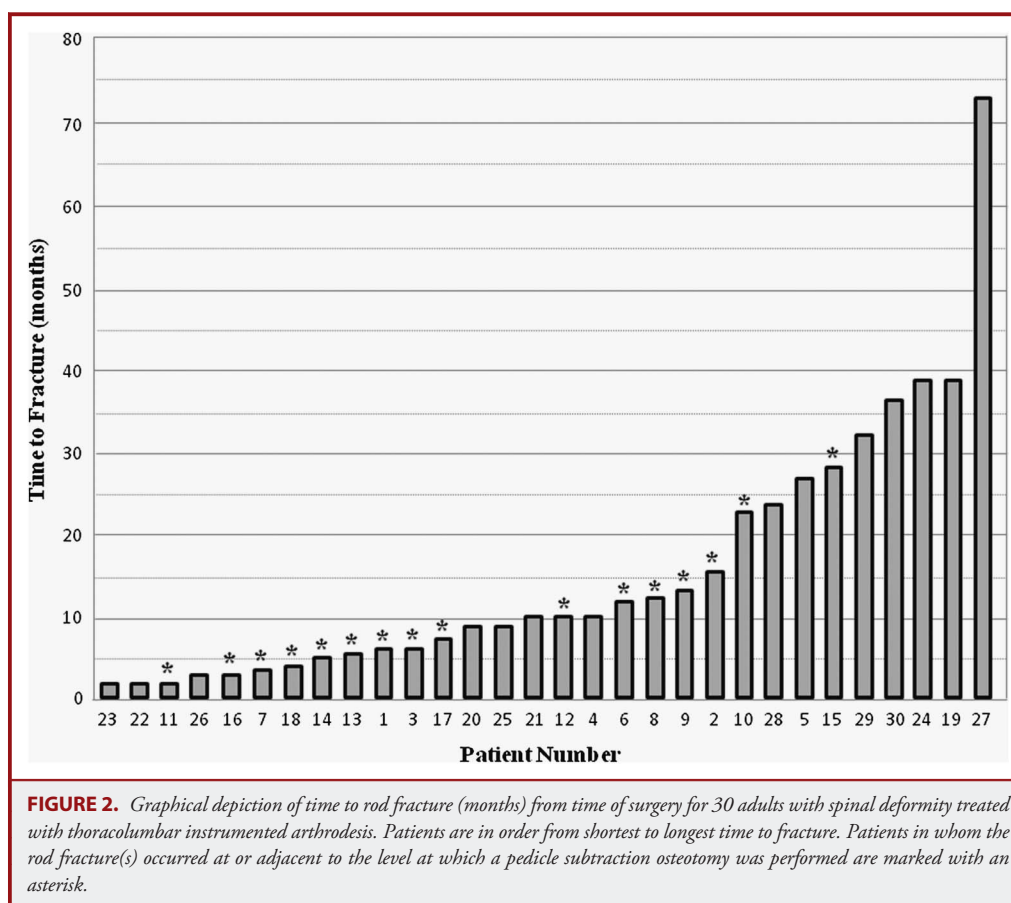
At last follow-up, 26 RF patients (87%) had undergone revision surgery to address the instrumentation failure. Of the 4 remaining patients, 3 (patients 4, 17, 28) had modest, but satisfactory, improvement in symptoms with nonoperative treatments and declined revision surgery (Figure 1), and 1 patient (patients 29) was deemed to not be a surgical candidate because of significant medical comorbidities (Figure 1). A variety of strategies were used to revise the 26 patients who were treated surgically. All patients underwent replacement of rods, either the entire rod or a portion of the rod with use of connectors, along with upsizing of any pedicle screws with evidence of loosening and rearthrodesis. For 7 patients, this was the entire revision strategy. In 5 patients, posterior osteotomies were performed to further correct positive

sagittal malalignment, including PSO in 4 patients and multilevel Smith-Peterson osteotomies in 1 patient. Interbody fusions were part of the revision strategy in 12 patients, including transforaminal lumbar interbody fusion in 2, anterior lumbar interbody fusion in 5, and lateral interbody fusion in 5 patients (Figure 3). Supplementation of replaced rods with additional satellite rods, using an approach such as that described by Scheer et al,¹² was used in 6 revision cases. At the time of revision, lack of arthrodesis was confirmed surgically for all patients, except for patient 23 (Figure 1).

Notably, revision procedures were not without complications. A total of 8 perioperative complications occurred in 6 of the 26 patients (23%) who underwent revision surgery. These included significant postoperative anemia (n = 3), airway obstruction requiring early reintubation (n = 1), postoperative pleural effusion (n = 1), durotomy (n = 1) with associated symptomatic pneumocephalus (n = 1), and a mild stroke (n = 1).

DISCUSSION

This study provides rates and time course of symptomatic RF after multilevel posterior instrumented fusion for adult spinal deformity based on a multicenter consecutive cases series. Most



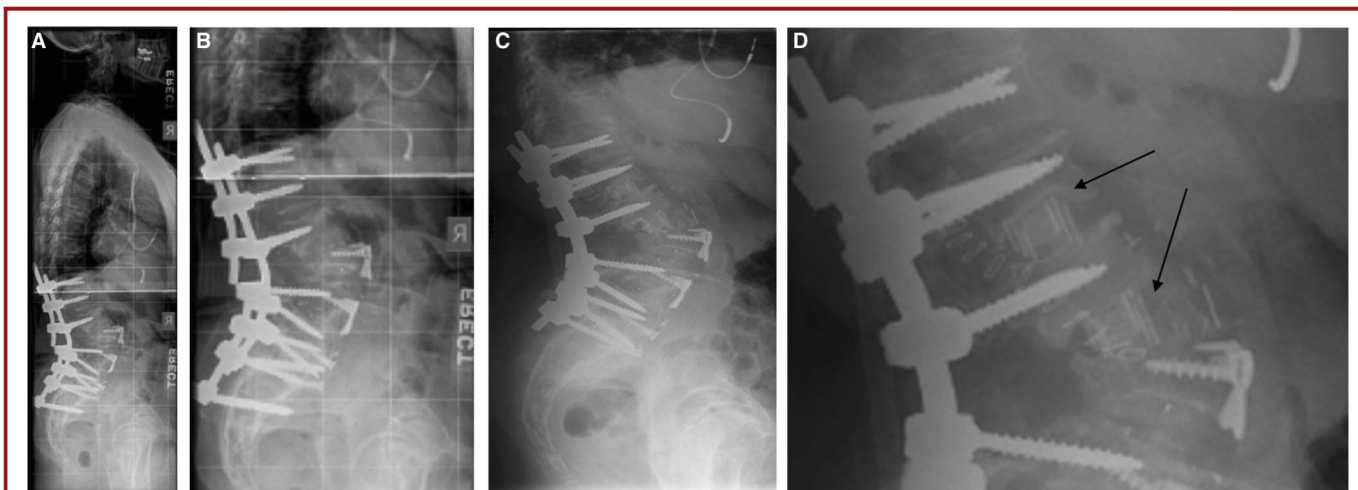


FIGURE 3. Case example of rod fracture revision strategy. An elderly woman presented with rod fracture 22 months after a posterior thoracolumbar instrumented arthrodesis. The procedure included an L3 pedicle subtraction osteotomy (PSO), L3-4 and L4-5 anterior lumbar interbody fusions, and pelvic fixation. The rod fracture occurred at the level of the PSO and was associated with pseudarthrosis (A and B). The revision strategy included placement of lateral interbody grafts at L1-2 and L2-3 for arthrodesis and placement of new rods bilaterally (C and D).

rod failures occurred within 1 year and occurred with all rod compositions and diameters and all fusion lengths. The data also demonstrate a rate of RF that is more than twofold higher for cases that included a PSO as part of the surgical procedure. In addition, the data also suggest that use of interbody grafting is not infallible in its ability to protect from pseudarthrosis or rod failure.

With few exceptions, RFs in patients with a PSO occurred at or immediately adjacent to the level of the osteotomy and typically occurred relatively early in the postoperative period, before arthrodesis may have been expected. Collectively, these observations suggest that the RFs associated with PSO may relate to excessive biomechanical stress at the PSO site, excessive rod contouring,^{8,10} or a combination of these factors. Other reports have also noted the occurrence of rod failure at the level of a PSO.^{5,16,21} Among 28 patients treated with a lumbar PSO, Yang et al⁵ reported an RF rate of 10.7%, with the failures occurring at the level of the PSO. Reports from Bridwell et al¹⁶ and Upadhyaya et al²¹ also document cases of RF at a PSO level. Other reports documented high rates of rod failure in patients treated with PSO, but do not note a preponderance of these failures at the level of the PSO.^{2,18,19}

The current study also suggests that the occurrence of RF may be associated with sagittal malalignment. The mean preoperative sagittal vertical axis of the RF cases (>160 mm) suggests that, as a group, these patients had significant positive sagittal malalignment. The mean amount of sagittal vertical axis correction of the group was substantial (86 mm); however, 16 of the 30 RF patients had residual postoperative sagittal malalignment. It is possible that this malalignment may have negatively affected the durability of the rods, but further study is necessary to confirm this potential risk factor.

The overall rate of rod failure observed in this study was lower for patients in whom cobalt chromium rods were used (2.7%) compared with rods composed of titanium alloy (8.6%) or stainless steel (7.4%). A similar trend was also observed for the subset of patients in whom a PSO was performed, for which the rate of RF was 7.0% for cobalt chromium, 17% for stainless steel, and 25% for titanium alloy. Collectively, these findings suggest that the greater strength of cobalt chromium rods may result in low rates of rod failure, especially in patients in whom a PSO is performed. Further study of the role of cobalt chromium rods in the setting of PSO is warranted, including biomechanical and prospective clinical assessments.

The subset of patients for whom a BMI could be calculated demonstrated a mean BMI in the obese category. Although this may simply be reflective of a general population with an increasing prevalence of obesity, it also very possible that added stress from greater body mass may contribute to the instrumentation failure observed in this study.

RF occurred over a substantial range of time after surgery, from 2 months to more than 6 years. Although it was not always clear, early fractures were generally attributed to primary failure of the instrumentation, whereas late failures were typically attributed to development of pseudarthrosis, with resulting stresses leading to instrumentation fatigue.

The rate at which RF occurs and the impact on affected patients suggests that further investigation of approaches to decrease its occurrence is warranted. Placement of a third rod (satellite rod) spanning PSO sites has been suggested as a means of increasing fatigue resistance.¹² Development of rods that are precontoured during the manufacturing process may also prove beneficial in reducing metal deformation that otherwise occurs with contouring

of rods in the operating room. In addition, use of plate benders instead of French benders for rod contouring may reduce the number of surface irregularities, such as notching.

The primary limitation of this study is the retrospective design. In addition, sagittal alignment parameters and BMI assessment were not analyzed for the patients without symptomatic RF, and explanted fractured rods were not available for assessment of notching or other features that may contribute to fracture. Because this study focused on the rates of symptomatic RF, these rates do not reflect any rod failures that may have occurred without symptoms. In addition, because the minimum follow-up for some patients was 1 year and the mean late RF occurred at 31.8 months, longer follow-up would likely show a higher incidence of late RF.

CONCLUSION

The incidence of RF after multilevel posterior instrumented arthrodesis for adult spinal deformity was 6.8%. For patients with a PSO, this rate was 15.8%. Most rod failures occurred within 1 year and occurred with all rod compositions and diameters and all fusion lengths. Cobalt chromium rods had lower rates of fracture compared with titanium alloy and stainless steel rods, especially in patients in whom a PSO was performed. Early failure was most common after PSO and, with few exceptions, occurred at or adjacent to the PSO site. Residual postoperative sagittal malalignment and greater BMI may increase the risk of RF, but additional study is necessary to further assess these potential risk factors.

Disclosures

Dr Smith is consultant to and has received honorarium for teaching and research study group support from DePuy and Medtronic; is a consultant to and has received honorarium from Biomet; has received honorarium for teaching from Globus; and is a former consultant to Axial Biotech. Dr Shaffrey is a consultant to, has received royalties from, and holds patents with Medtronic; is a consultant to DePuy; is a consultant to and holds a patent with Biomet; is a consultant to Nuvasive; has received honorarium from Globus; has received grants from the NIH and the Department of Defense; and has received fellowship support from NREF and AO. Dr Ames is a consultant to and has received research support from DePuy, Medtronic, and Stryker. Dr Fu has received honorarium from Synthes. Dr Schwab is a stock holder in Nemaris Inc; has received research support from DePuy Spine; is a consultant to and has received research support from Medtronic; and is a recipient of a grant from NIH. Dr LaFage is a stockholder in Nemaris Inc; a recipient of a grant from SRS; has received research support from DePuy; and is a consultant to Medtronic. The other authors have no personal financial or institutional interest in any of the drugs, materials, or devices described in this article. The International Spine Study Group is funded through research grants from DePuy Spine.

REFERENCES

- Chang KW, Cheng CW, Chen HC, Chang KI, Chen TC. Closing-opening wedge osteotomy for the treatment of sagittal imbalance. *Spine (Phila Pa 1976)*. 2008;33(13):1470-1477.
- Hyun SJ, Rhim SC. Clinical outcomes and complications after pedicle subtraction osteotomy for fixed sagittal imbalance patients: a long-term follow-up data. *J Korean Neurosurg Soc*. 2010;47(2):95-101.
- Machino M, Yukawa Y, Ito K, Nakashima H, Kato F. Posterior/anterior combined surgery for thoracolumbar burst fractures—posterior instrumentation with pedicle screws and laminar hooks, anterior decompression and strut grafting. *Spinal Cord*. 2011;49(4):573-579.
- Tsuchiya K, Bridwell KH, Kuklo TR, Lenke LG, Baldus C. Minimum 5-year analysis of L5-S1 fusion using sacropelvic fixation (bilateral S1 and iliac screws) for spinal deformity. *Spine (Phila Pa 1976)*. 2006;31(3):303-308.
- Yang BP, Ondra SL, Chen LA, Jung HS, Koski TR, Salehi SA. Clinical and radiographic outcomes of thoracic and lumbar pedicle subtraction osteotomy for fixed sagittal imbalance. *J Neurosurg Spine*. 2006;5(1):9-17.
- Cook SD, Barrack RL, Georgette FS, et al. An analysis of failed Harrington rods. *Spine (Phila Pa 1976)*. 1985;10(4):313-316.
- Johnston CE II, Ashman RB, Sherman MC, et al. Mechanical consequences of rod contouring and residual scoliosis in sublaminar segmental instrumentation. *J Orthop Res*. 1987;5(2):206-216.
- Dick JC, Bourgeault CA. Notch sensitivity of titanium alloy, commercially pure titanium, and stainless steel spinal implants. *Spine (Phila Pa 1976)*. 2001;26(15):1668-1672.
- Haheer T, Ottaviano D, Lapman P, Goldfarb B, Merola A, Valdevit A. A comparison of stainless steel and CP titanium rods for the anterior instrumentation of scoliosis. *Biomed Mater Eng*. 2004;14(1):71-77.
- Lindsey C, Deviren V, Xu Z, Yeh RF, Puttlitz CM. The effects of rod contouring on spinal construct fatigue strength. *Spine (Phila Pa 1976)*. 2006;31(15):1680-1687.
- Villarraga ML, Cripton PA, Teti SD, et al. Wear and corrosion in retrieved thoracolumbar posterior internal fixation. *Spine (Phila Pa 1976)*. 2006;31(21):2454-2462.
- Scheer JK, Tang JA, Deviren V, et al. Biomechanical analysis of revision strategies for rod fracture in pedicle subtraction osteotomy. *Neurosurgery*. 2011;69(1):164-172.
- Scheer JK, Tang JA, Deviren V, et al. Biomechanical analysis of cervicothoracic junction osteotomy in cadaveric model of ankylosing spondylitis: effect of rod material and diameter. *J Neurosurg Spine*. 2011;14(3):330-335.
- Albers HW, Hresko MT, Carlson J, Hall JE. Comparison of single- and dual-rod techniques for posterior spinal instrumentation in the treatment of adolescent idiopathic scoliosis. *Spine (Phila Pa 1976)*. 2000;25(15):1944-1949.
- Bago J, Ramirez M, Pellise F, Villanueva C. Survivorship analysis of Cotrel-Dubouset instrumentation in idiopathic scoliosis. *Eur Spine J*. 2003;12(4):435-439.
- Bridwell KH, Lewis SJ, Edwards C, et al. Complications and outcomes of pedicle subtraction osteotomies for fixed sagittal imbalance. *Spine (Phila Pa 1976)*. 2003;28(18):2093-2101.
- Glassman SD, Bazzi J, Puno RM, Dimar JR. The durability of small-diameter rods in lumbar spinal fusion. *J Spinal Disord*. 2000;13(2):165-167.
- Kim YJ, Bridwell KH, Lenke LG, Cheh G, Baldus C. Results of lumbar pedicle subtraction osteotomies for fixed sagittal imbalance: a minimum 5-year follow-up study. *Spine (Phila Pa 1976)*. 2007;32(20):2189-2197.
- O'Shaughnessy BA, Kuklo TR, Hsieh PC, Yang BP, Koski TR, Ondra SL. Thoracic pedicle subtraction osteotomy for fixed sagittal spinal deformity. *Spine (Phila Pa 1976)*. 2009;34(26):2893-2899.
- Wattenbarger JM, Richards BS, Herring JA. A comparison of single-rod instrumentation with double-rod instrumentation in adolescent idiopathic scoliosis. *Spine (Phila Pa 1976)*. 2000;25(13):1680-1688.
- Upadhyaya CD, Berven S, Mumaneni PV. Spondylolisthesis following a pedicle subtraction osteotomy. Case report. *Neurosurg Focus*. 2010;28(3):E16.

COMMENTS

The authors retrospectively studied symptomatic rod fracture (RF) in 442 adult spinal deformity patients treated with posterior instrumented fusion. In my opinion, the most interesting part of the study compares the rate of rod fracture among cobalt chromium, stainless steel, and titanium. The authors noted RF rates of 2.7% for cobalt chromium, 7.4% for stainless steel, and 8.6% for titanium. A similar trend was observed when comparing the rates in the subgroup of 114 patients in whom a pedicle subtraction osteotomy (PSO) was performed. The RF rate

after PSOs based on rod composition was 7% for cobalt chromium, 17% for stainless steel, and 25% for titanium.

Because this is a retrospective study performed by surgeons at 3 different centers, the authors are unable to describe why a certain rod composition was chosen for a particular patient in this series. In other words, there may have been different indications for using cobalt chromium vs stainless steel vs titanium among the different centers. Despite this shortcoming, I think the trend toward a lower RF rate in the cobalt chromium group should be taken seriously. Spinal deformity correction is a major operation that carries a high incidence of postoperative complications, even in the best of hands. Despite great efforts, most of these risks cannot be reduced and are attributed to factors that cannot be significantly modified, such as the length and complexity of the surgery as well as the comorbidities of the patient. Using a cobalt chromium rod instead of titanium or stainless steel could be a very simple improvement. It does not require more complex deformity correction techniques, it does not lengthen the operation, and it does not require any additional training. It also is not an expensive modification. I informally asked 2 spinal implant vendors for the price difference between titanium rods and cobalt chromium rods. One vendor had them equally priced, whereas the other vendor charged 43% more for the cobalt chromium rods.

This retrospective study suggests that cobalt chromium rods may lower the rate of a major complication, namely RF, after spinal deformity surgery. A prospective study in which spinal deformity patients undergoing surgical correction are randomized to different rod compositions would be very helpful to see whether cobalt chromium is truly superior to the other available options.

Ron I. Riesenburger

Boston, Massachusetts

This is a well-written study evaluating symptomatic rod breakage in adult spinal deformity (ASD). In addition to its increased stiffness compared with titanium alloys, cobalt chromium (CC) is less prone to fatigue from rod contouring, which is a significant advantage in ASD

surgery. This study did find that CC rods had lower fracture rates, although this difference did not quite reach statistical significance. Beyond rod composition, the authors' suggestion that residual positive sagittal malalignment and increased BMI can increase the risk of rod fracture (RF) should be considered cautiously. Although 16 of the 30 RF patients had residual malalignment, SVA data from patients who did not have symptomatic RF was unavailable, so statistical analysis to support this claim could not be done. Similarly, BMI data were known for only a majority of the RF patients and none of the nonsymptomatic RF patients. The BMI values of the RF patients that were known also varied widely (17.6-41.4) with a mean of 30 that would barely meet the "obese" threshold.

Paul Park

Ann Arbor, Michigan

The authors wrote an interesting paper on symptomatic rod fracture following posterior instrumented fusion for adult spinal deformity. The article is well written, interesting to read and the results are noteworthy. It is particularly interesting that the rod fracture percentage in pedicle subtraction ostiotomy is high. 89% of de patients with PSO and rod fracture had the fracture at or adjacent to the PSO, and occurred in the majority of cases within the first 10 months after surgery. As the authors state in the discussion, rod fracture is suggestive to be related to excessive biomechanical stress at the PSO site, excessive rod contouring or a combination of these factors. The authors suggest placement of a third rod spanning PSO sites as a means of increasing fatigue resistance. This suggestion may be a good solution for scoliotic deformities that have an indication to be redressed. If redression is not necessary, too much stress on the spondylodesis material should be avoided. The results stress the inability of spondylodesis material to force the spinal column in a shape that it does not naturally adopt.

Carmen LA Vleggeert-Lankamp

Leiden, The Netherlands

Reproduced with permission of copyright owner. Further reproduction prohibited
without permission.