



Treatment of Severe Unilateral Pulmonary Interstitial Emphysema in a Preterm Infant

Sharla M Rent and Steven M Donn*

Department of Pediatrics, Division of Neonatal-Perinatal Medicine, C.S. Mott Children's Hospital, Michigan Medicine, University of Michigan, Ann Arbor, Michigan, USA

Abstract

An extremely preterm infant developed severe unilateral pulmonary interstitial emphysema of the left lung. The marked heterogeneity of the patient's lung disease made traditional high frequency ventilation strategies ineffective. Selective right mainstem intubation was attempted, and after 24 h of treatment there was nearly total resolution on the radiograph imaging and noted clinical improvement following the intervention. Single bronchial intubation (SBI) is a protective ventilation strategy utilized in cases of severe lung injury, including pulmonary interstitial emphysema, whereby a single lung is ventilated in isolation, allowing the injured lung to decompress and heal. Use of SBI in the neonate has been described in the literature since the 1970s, but there remains a lack of cases detailing its use in extremely preterm infants.

Keywords: Prematurity; Respiratory distress syndrome; Pulmonary interstitial emphysema; High frequency ventilation

Abbreviations

ELBW: Extremely Low Birth Weight; HFJV: High Frequency Jet Ventilation; HFOV: High Frequency Oscillatory Ventilation; ILV: Independent Lung Ventilation; IP: Inspiratory Pressure; PEEP: Positive End Expiratory Pressure; PIE: Pulmonary Interstitial Emphysema; PIP: Peak Inspiratory Pressure; RDS: Respiratory Distress Syndrome; SBI: Single Bronchial Intubation

Case Presentation

An extremely preterm female infant was delivered at 23 weeks and 5 days of gestation. The mother was a 27-year-old Gravida-5, Para-3 woman, whose obstetrical history was significant for tobacco and cocaine use during pregnancy, and very limited prenatal care. The mother presented in labor and precipitously delivered the baby before antenatal maternal steroids could be administered. The infant required extensive resuscitation including endotracheal intubation and mechanical ventilation. She was given surfactant but her respiratory condition quickly necessitated the use of high frequency oscillatory ventilation (HFOV) for impaired gas exchange. Her initial chest radiograph (Figure 1) revealed an appropriately placed endotracheal tube and lung disease consistent with Respiratory Distress Syndrome (RDS). The infant was treated with ampicillin and gentamicin for presumed early onset sepsis and admitted to the NICU for further care.

Pulmonary interstitial emphysema (PIE) was first seen in this infant at 24 h of age (Figure 2). The area of PIE initially observed in the left lung continued to worsen over the next 48 h and was accompanied by wide fluctuations in arterial blood gas results. The baby was trialed first on high frequency jet ventilation (HFJV) on her third day of life. Moderate improvement in oxygenation and ventilation were noted on the HFJV, with less dramatic swings in pH and pCO₂.

Daily chest radiographs showed continued worsening of PIE with gas trapping and hyperinflation on the left lung and atelectasis of the right lung (Figure 3). The heterogeneous nature of the lung disease made it challenging to adequately expand and ventilate the right lung without overdistending and further damaging the left lung. A variety of ventilation strategies were attempted, including manipulations of HFJV settings, and a short course of high frequency oscillatory ventilation (HFOV) but to no avail. Hypercapnia and hypoxemia persisted.

With continued worsening of PIE in the left lung and atelectasis of the right lung, a decision was made to selectively intubate the right mainstem bronchus (single bronchial intubation, SBI) and the position of the endotracheal tube within the right main bronchus was confirmed radiographically

OPEN ACCESS

*Correspondence:

Steven M Donn, 8-621 C.S. Mott Children's Hospital, 1540 E. Hospital Drive, Ann Arbor, MI 48109-4254, USA, Tel: 734 763-4109; Fax: 734 763-7728; E-mail: smdonnm@med.umich.edu

Received Date: 16 Aug 2017

Accepted Date: 31 Aug 2017

Published Date: 07 Sep 2017

Citation:

Rent SM, Donn SM. Treatment of Severe Unilateral Pulmonary Interstitial Emphysema in a Preterm Infant. *Ann Med Case Rep.* 2017; 1: 1019.

Copyright © 2017 Steven M Donn.

This is an open access article distributed under the Creative Commons Attribution License, which permits unrestricted use, distribution, and reproduction in any medium, provided the original work is properly cited.

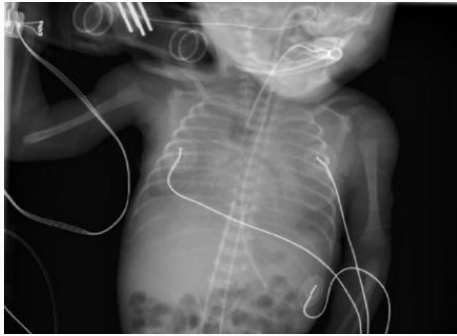


Figure 1: Chest radiograph within 1 hour of birth, demonstrating premature lungs with signs of RDS.

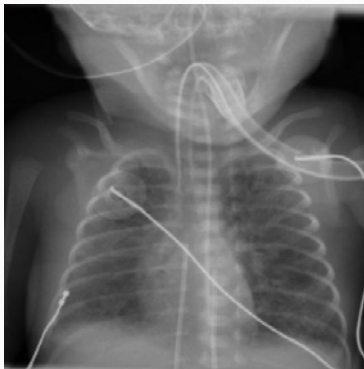


Figure 2: Chest radiograph on DOL 1, demonstrating early signs of pulmonary interstitial emphysema in the left lung.

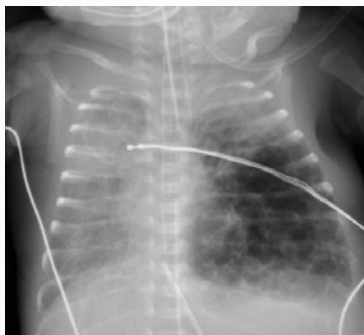

Figure 3: Chest radiograph on DOL 15, demonstrating worsening PIE with significant gas trapping noted in the left lung.

(Figure 4). The baby was placed on HFJV with low background conventional support. After 24 h of SBI, the PIE had resolved and the right lung had been reinflated. The endotracheal tube was retracted to its original position for resumed ventilation of both lungs. After reinitiating dual lung ventilation, subsequent chest radiographs showed improved aeration of the left lung with near resolution of PIE. The baby had decreasing ventilator and FiO_2 requirements with no recurrence of PIE seen on follow-up chest radiographs (Figure 5). At 35 days of age, HFJV was discontinued.

Discussion

Pulmonary interstitial emphysema is characterized by dissection of air into the pulmonary interstitial space, high airway resistance, gas trapping, and pulmonary overdistention. The development of PIE is a relatively common consequence of mechanical ventilation

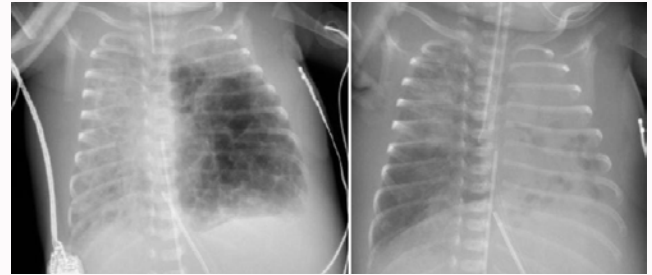


Figure 4: Chest radiograph on DOL 18, just prior to (left) and 24 hours after (right) selective right mainstem intubation and single lung ventilation.

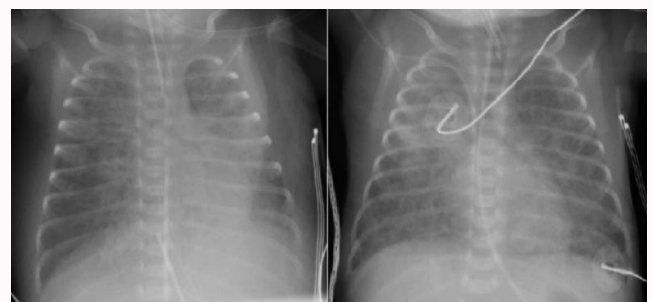

Figure 5: Chest radiograph on DOL 19 & 23, immediately following return to dual lung ventilation (left) and 4 days later (right).

in premature infants, especially those with underlying respiratory distress syndrome, and leads to worsening respiratory status in an already compromised infant. As PIE progresses, increasing ventilator pressures are necessary to support gas exchange; unfortunately, these increased pressures further worsen the interstitial air collections and gas trapping. PIE can affect any area of the lung, and is not uncommon in premature infants to have one lung significantly more affected than the other. The resultant heterogeneity of lung involvement makes it difficult to find optimal settings of mechanical ventilation to appropriately ventilate the more collapsed, but healthier, lung without causing further damage to the side affected by PIE, as occurred in our patient.

HFJV is often used in the setting of air leaks, including PIE, because of its ability to improve ventilation/perfusion matching and facilitate healing of the injured lung areas by providing rapid small tidal volumes, therefore reducing mechanical stretching of these high resistance injured lung regions. As with any ventilator modality, HFJV has its limitations, especially in severe cases of PIE. In our case, with worsening PIE despite optimization of HFJV settings, SBI of the right mainstem bronchus was chosen as a treatment modality over further manipulation of the ventilator settings. SBI facilitated the delivery of adequate pressure to the atelectatic right lung, allowing for satisfactory gas exchange, while avoiding the transmission of these higher pressures to the already over-expanded left lung. The left lung was therefore allowed to decompress and heal from the pulmonary interstitial emphysema.

Single bronchial intubation (SBI) involves the selective intubation of either the right or the left mainstem bronchus to enable ventilation of a single lung. SBI is rarely used in the neonate, although it has been previously described. Initial reports from the 1970s suggest SBI as a viable treatment modality for severe PIE and as a way to avoid lobectomy in this population [1]. Later cases highlight the benefit of unilateral ventilation in cases of PIE, pneumonia, Respiratory Syncytial

Virus infections, and bronchial tears [2-5]. These publications show a trend toward positive outcomes; however, the use of SBI in the neonate remains infrequent, more so since the advent of HFJV.

Independent lung ventilation (ILV) strategies have been described in infants and children, but not in premature infants. This treatment modality facilitates the ventilation of one lung in isolation of the other, allowing different modalities of ventilation to be used in each lung. ILV was initially used for adult asymmetric lung injury and was applied to the pediatric population in the setting of thoracic surgery and, less commonly, severe heterogeneous pulmonary disease [5-7]. In our case of SBI, the baby was born at 23 weeks' gestation and weighed of 595 g, considerably smaller than other SBI or ILV patients previously described in the literature.

While the majority of recent literature focuses on successful use of ILV, rather than SBI, this form of ventilation could not be used in our case. Reports of ILV in neonates have been described with simultaneous intubation with 2 separate endotracheal tubes [4], with one in the trachea, providing ventilation to the left lung, and one in the right main bronchus, providing ventilation to the right lung. While this method was successful in term neonates, the size of our patient precluded consideration of ILV. Other reports detail the use of a double lumen tube to achieve a similar endpoint [7]; however, with an internal diameter of approximately 5.4 mm for the smallest available tube pairing, this method was also not applicable to the extremely preterm population.

Despite not being a common practice in the NICU, evidence in support of SBI dates back several decades [1,2], and a handful of more recent publications [3,8] support revisiting this intervention, especially in patients in whom ILV is not feasible. Not every patient can tolerate SBI, and temporary hypercarbia and vital sign lability have been described. The duration of SBI varies between cases, ranging from 24 h to 10 days [1,8], with radiographic and clinical improvement guiding the length of SBI in each case. Both right and left mainstem intubations have been described [8]. While the majority of published cases describe the use of SBI in term or later-preterm infants, one prior case of its use in the ELBW exists and similarly reported favorable outcomes [8].

Our case demonstrates the feasibility and efficacy of SBI for treating unilateral PIE in an extremely preterm infant unresponsive to high frequency ventilation. The success of this treatment should encourage consideration of this intervention before moving to surgical interventions such as lobectomy.

References

1. Brooks JG, Bustamante SA, Koops BL, Hilton S, Cooper D, Wesenberg RL, et al. Selective bronchial intubation for the treatment of severe localized pulmonary interstitial emphysema in newborn infants. *J Pediatr.* 1977;91(4):648-52.
2. Milner AD, Field D, Hopkin IE, Tyrell J. Selective bronchial intubation for pulmonary emphysema. *Arch Dis Child.* 1985;60(1):83-4.
3. O'Donovan D, Wearden M, Adams J. Unilateral pulmonary interstitial emphysema following pneumonia in a perterm infant successfully treated with prolonged selective bronchial intubation. *Am J Perinatol.* 1999;16(7):327-31.
4. Nardo MD, Perrotta D, Stoppa F, Cecchetti C, Marano M, Pirozzi N. Independent lung ventilation in a newborn with asymmetric acute lung injury due to respiratory syncytial virus: a case report. *J Med Case Rep.* 2008;2:212-6.
5. Pizov R, Shir Y, Eimerl D, Uretzky G, Milgater E, Cotev S. One-lung high frequency ventilation in the management of traumatic tear of bronchus in a child. *Crit Care Med.* 1987;15(12):1160-1.
6. Plotz FB, Hassing MBF, Sibarani-Ponsen RD, Markhorst DG. Differentiated HFO and CMV for independent lung ventilation in a pediatric patient. *Intensive Care Med.* 2003;29(10):1855.
7. Pawar DK, Marraro GA. One lung ventilation in infants and children: Experience with Marraro double lumen tube. *Pediatr Anesth.* 2005;15(3):204-8.
8. Chalak LF, Kaiser JR, Arrington RW. Resolution of pulmonary interstitial emphysema following selective left mainstem intubation in a premature newborn: An old procedure revisited. *Pediatr Anesth.* 2007;17(2):183-6.