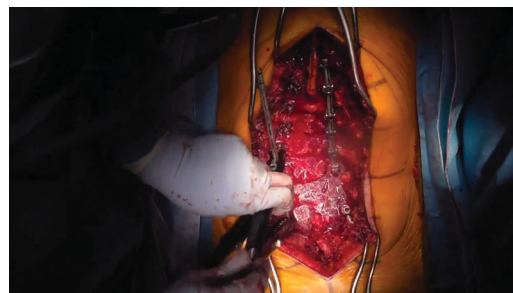


Deformity Correction Through the Use of Reduction Towers: 2-Dimensional Operative Video

Avery L. Buchholz, MD*, Thomas J. Buell, MD*, Mark E. Shaffrey, MD*, Regis W. Haid, MD[‡], Christopher I. Shaffrey, MD[§]

*University of Virginia, Department of Neurosurgery, Charlottesville, Virginia; [‡]Atlanta Brain and Spine, Atlanta, Georgia; [§]Duke Medical Center, Department: Duke Spine Center, Durham, North Carolina



Watch now at <https://academic.oup.com/ons/article-lookup/doi/10.1093/ons/oz356>

Correspondence: Avery L. Buchholz, MD, MPH, University of Virginia, Department of Neurosurgery, PO BOX 800212, Charlottesville, VA 22908-0212, USA. Email: buchholz@virginia.edu

Spinal deformity management can be difficult. The decision for surgery, approach, number of levels, and surgical technique all present challenges. Even when other issues are managed appropriately the process of how to correct the deformity needs special consideration.

Numerous techniques have been studied including vertebra-to-rod, rod de-rotation, 3-rod-techniques, and cantilever maneuvers. While cantilever is the preferred technique when treating sagittal plane deformity, scoliosis often requires a combination of techniques due to the complexity of deformity in coronal and transverse planes.

This video illustrates an adult scoliosis correction using sequential reduction towers and de-rotation techniques. Using this method the step of hook holders is eliminated and tension is distributed evenly across the rod using sequential reduction of the reduction towers across the length of the rod. This has led to a very efficient correction

of our deformity as well as a powerful de-rotation tool. We routinely use this technique for flexible and rigid deformities, which is assessed pre-op with a computed tomography.

The patient is a 67-yr-old female with prior lumbar decompressions and worsening back pain with radiculopathy. No significant sagittal malalignment is present but pelvic tilt is elevated and a coronal deformity exists. pelvic incidence measures 59°, LL50°, PT28° and lumbar scoliosis shows a coronal Cobb angle of 50.8°. Briefly, surgery involved transpedicular instrumentation from T10-S1 with bilateral iliac screw fixation. To achieve mobility posterior column osteotomies were performed at T12-L1, L1-2, L2-3, L3-4, L4-5, and L5-S1 levels. TLIF was performed at L4-5, L5-S1 for fusion. Postoperative scoliosis X-rays demonstrated improved sagittal and coronal alignment with PI59°, LL59°, PT22°, and coronal Cobb angle of 12°.

KEY WORDS: Deformity, Scoliosis, Reduction

Operative Neurosurgery 19:E157–E158, 2020

DOI:10.1093/ons/oz356

Received, June 25, 2019. Accepted, September 12, 2019. Published Online, December 12, 2019.

Disclosures

The authors have no personal, financial, or institutional interest in any of the drugs, materials, or devices described in this article. Dr Buchholz is a consultant for Siemens and Medtronic and teaches for NuVasive. Dr Haid is a consultant for NuVasive, receives royalties from Medtronic Sofamor Danek, Elsevier, NuVasive, and Globus Medical, and holds stock in Spine Wave, Vertical Health, NuVasive, and Globus Medical. Dr Shaffrey is a consultant for Medtronic, NuVasive, Stryker (educational), EOS, and Siemens, receives royalties from Medtronic, NuVasive, and Zimmer Biomet, holds patents with Medtronic, NuVasive, and Zimmer Biomet, is a stockholder in NuVasive, has research grants

from the NIH, Department of Defense, NATCN, DePuy Synthes, and AO, and has fellowship support from AO and NREF.

COMMENT

The authors present an operative video detailing the use of reduction towers for deformity correction in a degenerative scoliosis patient with primarily a coronal deformity. Through judicious use of posterior column osteotomies and transforaminal interbody work at the distal

segments, this paper illustrates the amount of correction that one can expect to achieve in coronal alignment with the utilization of these towers. One key aspect of the technique involves contouring the rod to the desired alignment prior to reduction, and minimizing the amount of stress placed at the proximal end of the construct. The authors are to be commended for the video quality with good use of time lapse to provide a concise overview of what is oftentimes a challenging aspect of

deformity surgery. This paper clearly illustrates the potential of corrective techniques with reduction towers, and with this video can be readily incorporated into the armamentarium of any surgeon who wishes to treat such pathology.

Victor Chang
Detroit, Michigan