



Case report

COVID-19-associated brief psychotic disorder

Colin M Smith ^{1,2}, Jonathan R Komisar,^{1,2} Ahmad Mourad ², Brian R Kincaid^{1,2}

¹Department of Psychiatry and Behavioral Sciences, Duke University Medical Center, Durham, North Carolina, USA
²Department of Medicine, Duke University Medical Center, Durham, North Carolina, USA

Correspondence to
 Dr Colin M Smith;
 colin.smith@duke.edu

Accepted 29 July 2020

SUMMARY

A 36-year-old previously healthy woman with no personal or family history of mental illness presented with new-onset psychosis after a diagnosis of symptomatic COVID-19. Her psychotic symptoms initially improved with antipsychotics and benzodiazepines and further improved with resolution of COVID-19 symptoms. This is the first case of COVID-19-associated psychosis in a patient with no personal or family history of a severe mood or psychotic disorder presenting with symptomatic COVID-19, highlighting the need for vigilant monitoring of neuropsychiatric symptoms in these individuals.

BACKGROUND

The novel coronavirus (severe acute respiratory syndrome coronavirus 2; SARS-CoV-2), the causative agent of the COVID-19, is rapidly emerging. From 29 December 2019, when the first cases of COVID-19 were documented in Wuhan, China, COVID-19 has resulted in more than 3.9 million infections in the USA, representing nearly 30% of cases worldwide.^{1,2}

Typical symptoms of COVID-19 are dyspnoea, cough, fever, myalgia and sore throat, though nervous system involvement, resulting in cerebrovascular diseases, encephalopathy, encephalitis and new-onset anosmia and dysgeusia, has been documented.^{3–5}

Recent cases of reactive psychosis in the context of the COVID-19 pandemic have emerged in the literature, but less attention has been given to incident psychosis affecting patients with COVID-19.⁶ Although a recent report documented cases of COVID-19-related psychosis in Madrid, this did not include a clinical description of affected patients.⁷ Ferrando *et al*⁸ described three cases of new-onset psychosis in patients with asymptomatic COVID-19, though two of these patients had a pre-existing psychiatric illness, and there were concerns for concurrent delirium.

Here, we report a case of symptomatic COVID-19-related psychosis in a patient with no personal or family history of mental illness and briefly discuss the relevant literature on coronavirus-associated psychosis.

CASE PRESENTATION

A 36-year-old African-American woman employed at a skilled nursing facility with a remote history of erythema multiforme, and no psychiatric history, was diagnosed with COVID-19 by nasopharyngeal swab after a known exposure at work. Symptoms at the time of diagnosis with COVID-19 were notable for rhinorrhoea and nasal congestion without any concomitant dyspnoea or documentation of anosmia or dysgeusia. Approximately 4 days following onset of upper respiratory symptoms, she was noted to have

an acute, rapidly progressive change in her behaviour characterised by prominent persecutory delusions and decreased sleep. Her delusions were primarily directed at her partner and focused on the safety of her children and personal finances. She believed her partner was attempting to kidnap her children and steal her COVID-19 stimulus money. Collateral information from the patient's family revealed that she had been engaging in ruminative, persecutory thought patterns centring around being 'tracked by cell phones' in the days preceding hospitalisation. This began after a domestic dispute with her partner. Her symptoms culminated in the patient attempting to pass her children through a local fast-food restaurant drive-through in an effort to prevent their kidnapping, at which time first responders were notified and she was transported to the hospital.

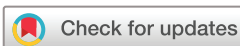Due to the acute onset of psychosis of unclear aetiology and her positive COVID-19 status, the patient was initially admitted to the general medicine service, whereupon psychiatry was consulted for further evaluation and management. At the time of her initial psychiatric interview, she was avoiding eye contact, but had no psychomotor agitation or retardation. She did not appear to be responding to internal stimuli. Her speech was noted to be increased in rate, though interruptible with repeated prompts. She described her mood as 'worried', and her affect was congruent to mood. She exhibited a tangential thought process with content notable for persecutory delusions. At the time of initial assessment she denied any suicidality or homicidality. Attention, concentration and orientation were intact on bedside testing.

INVESTIGATIONS

Vital signs on admission were: temperature 36.8°C, heart rate 79 beats per minute, respiratory rate 19 breaths per minute and blood pressure 114/85 mm Hg. Laboratory testing revealed positive SARS-CoV-2 nasopharyngeal swab, mild leucocytosis (white cell count $11.5 \times 10^9/L$, 86.4% neutrophils), elevated C-reactive protein (2.37 mg/dL), elevated D-dimer (2274 ng/mL fibrinogen equivalent units), but otherwise normal electrolytes, ferritin, renal function, urine analysis and toxicology. Interleukin levels were not measured as it was not part of the standard of care at our institution. CT scan and MRI of the head were normal. A lumbar puncture revealed: cerebrospinal fluid colour was colourless, hazy, red cell count $187 \times 10^{12}/L$, and nucleated cell count $1/\mu L$ in tube 1, glucose 69 mg/dL and protein 20 mg/dL. Extended meningitis PCR panel was negative.

DIFFERENTIAL DIAGNOSIS

Given the paucity of alternative aetiologies for her development of acute psychosis, it was felt that the



© BMJ Publishing Group Limited 2020. No commercial re-use. See rights and permissions. Published by BMJ.

To cite: Smith CM, Komisar JR, Mourad A, *et al*. *BMJ Case Rep* 2020;**13**:e236940. doi:10.1136/bcr-2020-236940

patient's symptoms were either representative of a first-episode psychosis, triggered by psychosocial stressors secondary to her recent COVID-19 diagnosis, a brief psychotic disorder in the setting of an obvious stressor, or a direct sequela of COVID-19 infection and representative of a brief psychotic disorder. Delirium was also considered, but she lacked alterations in attention or awareness on bedside evaluation and did not screen positive using our institution's nursing delirium observation scale.

TREATMENT

Due to the severity of the patient's psychiatric symptoms, inability to engage in reality testing and perceived elevated risk of both harm to self and others (as her acute illness limited her ability to engage in and appreciate the need for social isolation as an active carrier of COVID-19), the patient was initially involuntarily committed, and pharmacotherapy was initiated. She was initially treated with two daily doses of olanzapine 2.5 and 5 mg in an effort to target both her underlying psychotic symptoms and aid in sedation to promote restoration of the patient's sleep-wake cycle. Despite initiation of olanzapine, the patient remained paranoid with prominent delusional thinking and minimal insight, leading to an episode of acute agitation. Given the severity of her ongoing symptoms, clonazepam 0.5 mg twice daily was added for acute anxiolysis and reduced to once daily. Considering the possibility that she would need to be on antipsychotics at discharge, and that olanzapine is not recommended as first-line therapy in psychosis (due to metabolic side effects) she was transitioned to risperidone. With titration to 3 mg of risperidone daily, the patient had significant improvement in her persecutory delusions and subsequently exhibited improvement in her insight and judgement. Clonazepam was discontinued and she was discharged on hospital day 7 on risperidone 3 mg nightly with a plan for close outpatient follow-up with psychiatry. Of note, she did not require any therapy for her COVID-19 infection as she remained on room air after hospitalisation with resolution of her respiratory symptoms.

OUTCOME AND FOLLOW-UP

Follow-up documentation from her outpatient provider 1 week after discharge noted that she had not attended her psychiatry intake appointment, though she had noted near resolution of her psychiatric symptoms and had self-discontinued the risperidone without return of her persecutory delusions.

DISCUSSION

To our knowledge, this case represents the first description of symptomatic COVID-19-associated brief psychotic disorder in an individual with no personal or family history of primary psychiatric illness. A case series in Madrid noted an unspecified number of potential cases of COVID-19-related psychosis in their hospital, but did not detail the clinical course of affected patients.⁷ A recent case series in New York described three cases of new-onset psychosis in patients with COVID-19.⁸ However, all patients were incidentally found to have positive SARS-CoV-2 test and did not present with other symptoms to suggest infection, calling into question whether the diagnosis of COVID-19 was related to the psychosis. Further, one patient had a comorbid panic disorder, which may lead to heightened vulnerability to psychotic illness, and another was experiencing homelessness and was on 120 mg of methadone for opioid use disorder, again confounding the diagnosis of COVID-19 psychosis.⁹

In the case presented herein, there was no history of prodromal symptoms, no personal or family history of mental illness and a relatively rapid resolution of psychosis. Further, she did not have a history of substance use or propsychotic medication (such as steroids) use, and the onset of psychosis coincided with upper respiratory symptoms. Given the temporality between infection and psychiatric

symptoms, along with the resolution of symptoms with improvement of COVID-19-related symptoms, a working diagnosis of brief psychotic disorder associated with COVID-19 was given.¹⁰ The mechanism by which COVID-19 may have precipitated psychosis in this patient is not entirely clear, but could be related to the diagnosis of COVID-19, increased stress in the setting of ongoing infection or a viral mediated psychosis.

Indeed, respiratory viruses have been associated with psychosis since the 1918 influenza pandemic when Menninger published a report of 100 patients with neuropsychiatric sequelae associated with influenza infection, including 25 with 'dementia praecox' and 23 with 'other psychoses'.^{11 12} Coronaviruses, too, have been linked to psychosis. A recent rapid review of epidemic and pandemic literature identified five papers (four observational studies and one case series) reporting incident psychosis in SARS and one paper reporting psychosis in Middle East respiratory syndrome.¹³⁻¹⁹ The incident rate of psychotic symptoms across observational studies was between 0.9% and 11.8%.^{14-16 19} SARS-related psychotic symptoms were associated with higher doses of corticosteroids, severity of SARS symptoms and family history of psychiatric illness and psychosocial stressors.^{14 15} The single case series of three patients with SARS-related psychosis suggested that SARS severity, steroid treatment and social isolation were contributing factors.¹⁸

Severance *et al*¹⁷ reported an association between coronaviruses and psychotic symptoms by measuring immunoglobulin G (IgG) response against four human coronavirus strains in patients with recent onset of psychotic illness compared with healthy controls. The authors found that patient IgG levels for two strains of coronavirus (HKU1 and NL63) were significantly higher in patients with psychotic symptoms when compared with controls, suggesting these two coronaviruses may be risk factors for neuropsychiatric illness.

Although heightened stress of a COVID-19 diagnosis or medications (such as corticosteroids) may unmask an underlying primary psychotic disorder in a vulnerable individual, the idea that SARS-CoV-2 may itself trigger psychosis through direct neurotoxicity or a heightened immune response is not unreasonable.¹³ Coronaviruses are neurotropic, for example, and SARS-CoV-2 RNA has recently been isolated from the central nervous system of a patient.^{4 20} Moreover, the antipsychotics haloperidol and chlorpromazine have displayed antiviral activity against SARS-CoV-2 in vitro and in a mice model, respectively.^{21 22} In a review of the literature, Troyer *et al*²³ offer direct infection, blood circulation, neuronal involvement, hypoxic injury, immune injury and ACE2 binding as possible culprits of coronavirus nervous system damage.

With these data in mind, we contend that a relevant neuropsychiatric review of systems and full exam should be completed in patients presenting with suspected or confirmed COVID-19. New-onset psychosis in a patient with suspected or confirmed COVID-19, without personal or family history of mental illness and no other clear precipitant, should prompt further medical workup (eg, head imaging and lumbar puncture). This is consistent with the the American Psychiatric Association's draft 2019 guidelines for schizophrenia treatment, which state that clinicians should be alert to features that suggest a need for additional physical or laboratory evaluation in first-episode psychosis.²⁴

Although studies investigating the treatment of COVID-19 psychosis have not been undertaken, treatment of secondary psychosis should be geared towards treating the underlying illness while managing psychotic symptoms with antipsychotics and benzodiazepines at the lowest possible dose.²⁵ Given concerns for dysrhythmias in patients with pre-existing cardiac injury and COVID-19, intravenous haloperidol should be avoided in this population, where possible.²⁶

Learning points

- ▶ Individuals with COVID-19 may be at risk of developing neuropsychiatric symptoms, including psychosis.
- ▶ COVID-19 diagnosis could predispose vulnerable patients to psychosis and clinicians should be aware of this.
- ▶ A diagnosis of COVID-19 should prompt a neuropsychiatric review of systems and psychiatric exam.
- ▶ In individuals presenting with new-onset psychosis in areas endemic to COVID-19, consideration should be made for testing in the absence of respiratory symptoms.

Acknowledgements We appreciate Lisa Vann, MD and Kristen Shirey, MD for their clinical guidance in the care of this patient.

Contributors CMS wrote the draft of the introduction and discussion of the manuscript, while JRK and AM wrote the draft of the case presentation, while participating in clinical care and clinical data extraction for the case. CMS, JRK, AM and BRK reviewed the literature and participated in data interpretation. BRK oversaw the clinical care of the patient. All authors contributed to the final writing, analysis and revising of the article, gave approval for the final version to be published and agree to be accountable for all aspects of the work.

Funding The authors have not declared a specific grant for this research from any funding agency in the public, commercial or not-for-profit sectors.

Disclaimer The views expressed in the article are solely the opinions of the authors and do not necessarily reflect the official policies of the U.S. Department of Health and Human Services or the Indian Health Service.

Competing interests None declared.

Patient consent for publication Obtained.

Provenance and peer review Not commissioned; externally peer reviewed.

This article is made freely available for use in accordance with BMJ's website terms and conditions for the duration of the covid-19 pandemic or until otherwise determined by BMJ. You may use, download and print the article for any lawful, non-commercial purpose (including text and data mining) provided that all copyright notices and trade marks are retained.

ORCID iDs

Colin M Smith <http://orcid.org/0000-0002-5758-4698>

Ahmad Mourad <http://orcid.org/0000-0002-3149-597X>

REFERENCES

- 1 Zhu N, Zhang D, Wang W, *et al.* A novel coronavirus from patients with pneumonia in China, 2019. *N Engl J Med Overseas Ed* 2020;382:727–33.
- 2 Johns Hopkins University Center for Systems Science and Engineering. Coronavirus COVID-19 global cases by the center for systems science and engineering Johns Hopkins University coronavirus resource center website, 2020. Available: <https://coronavirus.jhu.edu/map.html> [Accessed 30 May 2020].
- 3 Guan W-J, Ni Z-Y, Hu Y, *et al.* Clinical characteristics of coronavirus disease 2019 in China. *N Engl J Med* 2020;382:1708–20.
- 4 Moriguchi T, Harii N, Goto J, *et al.* A first case of meningitis/encephalitis associated with SARS-Coronavirus-2. *Int J Infect Dis* 2020;94:55–8.
- 5 Mao L, Jin H, Wang M, *et al.* Neurologic manifestations of hospitalized patients with coronavirus disease 2019 in Wuhan, China. *JAMA Neurol* 2020. doi:10.1001/jamaneurol.2020.1127. [Epub ahead of print: 10 Apr 2020].
- 6 Valdés-Flórida MJ, López-Díaz Álvaro, Palermo-Zeballos FJ, *et al.* Reactive psychoses in the context of the COVID-19 pandemic: clinical perspectives from a case series. *Rev Psiquiatr Salud Ment* 2020;13:90–4.
- 7 Rentero D, Juanes A, Losada CP, *et al.* New-Onset psychosis in COVID-19 pandemic: a case series in Madrid. *Psychiatry Res* 2020;290:113097.
- 8 Ferrando SJ, Klepacz L, Lynch S, *et al.* COVID-19 psychosis: a potential new neuropsychiatric condition triggered by novel coronavirus infection and the inflammatory response? *Psychosomatics* 2020. doi:10.1016/j.psym.2020.05.012. [Epub ahead of print: 19 May 2020].
- 9 Galynker I, Ieronimo C, Perez-Acquino A, *et al.* Panic attacks with psychotic features. *J Clin Psychiatry* 1996;57:402–6.
- 10 Keshavan MS, Kaneko Y. Secondary psychoses: an update. *World Psychiatry* 2013;12:4–15.
- 11 Keipińska AP, Iyegbe CO, Vernon AC, *et al.* Schizophrenia and influenza at the centenary of the 1918-1919 Spanish influenza pandemic: mechanisms of psychosis risk. *Front Psychiatry* 2020;11:72.
- 12 Menninger KA. Psychoses associated with influenza: I. General data: statistical analysis. *JAMA* 1919;72:235–41.
- 13 Brown ES, Chandler PA. Mood and cognitive changes during systemic corticosteroid therapy. *Prim Care Companion J Clin Psychiatry* 2001;3:17–21.
- 14 Sheng B, Cheng SKW, Lau KK, *et al.* The effects of disease severity, use of corticosteroids and social factors on neuropsychiatric complaints in severe acute respiratory syndrome (SARS) patients at acute and convalescent phases. *Eur Psychiatry* 2005;20:236–42.
- 15 Lee DTS, Wing YK, Leung HCM, *et al.* Factors associated with psychosis among patients with severe acute respiratory syndrome: a case-control study. *Clin Infect Dis* 2004;39:1247–9.
- 16 Mak IWC, Chu CM, Pan PC, *et al.* Long-Term psychiatric morbidities among SARS survivors. *Gen Hosp Psychiatry* 2009;31:318–26.
- 17 Severance EG, Dickerson FB, Viscidi RP, *et al.* Coronavirus immunoreactivity in individuals with a recent onset of psychotic symptoms. *Schizophr Bull* 2011;37:101–7.
- 18 Cheng SK-W, Tsang JS-K, Ku K-H, *et al.* Psychiatric complications in patients with severe acute respiratory syndrome (SARS) during the acute treatment phase: a series of 10 cases. *Br J Psychiatry* 2004;184:359–60.
- 19 Kim H-C, Yoo S-Y, Lee B-H, *et al.* Psychiatric findings in suspected and confirmed middle East respiratory syndrome patients Quarantined in hospital: a retrospective chart analysis. *Psychiatry Investig* 2018;15:355–60.
- 20 Arbour N, Day R, Newcombe J, *et al.* Neuroinvasion by human respiratory coronaviruses. *J Virol* 2000;74:8913–21.
- 21 Gordon DE, Jang GM, Bouhaddou M, *et al.* A SARS-CoV-2 protein interaction map reveals targets for drug repurposing. *Nature* 2020;583:459–68.
- 22 Weston S, Coleman CM, Haupt R, *et al.* Broad anti-coronaviral activity of FDA approved drugs against SARS-CoV-2 in vitro and SARS-CoV in vivo. *bioRxiv* 2020.
- 23 Troyer EA, Kohn JN, Hong S. Are we facing a crashing wave of neuropsychiatric sequelae of COVID-19? neuropsychiatric symptoms and potential immunologic mechanisms. *Brain Behav Immun* 2020;87:34–9.
- 24 The American Psychiatric Association. Practice guideline for the treatment of patients with schizophrenia. Available: <https://www.psychiatry.org/psychiatrists/practice/clinical-practice-guidelines2019> [Accessed 30 May 2020].
- 25 Wilson MP, Pepper D, Currier GW, *et al.* The psychopharmacology of agitation: consensus statement of the American association for emergency psychiatry project beta psychopharmacology Workgroup. *West J Emerg Med* 2012;13:26–34.
- 26 Huang C, Wang Y, Li X, *et al.* Clinical features of patients infected with 2019 novel coronavirus in Wuhan, China. *Lancet* 2020;395:497–506.

Copyright 2020 BMJ Publishing Group. All rights reserved. For permission to reuse any of this content visit <https://www.bmj.com/company/products-services/rights-and-licensing/permissions/>
BMJ Case Report Fellows may re-use this article for personal use and teaching without any further permission.

Become a Fellow of BMJ Case Reports today and you can:

- ▶ Submit as many cases as you like
- ▶ Enjoy fast sympathetic peer review and rapid publication of accepted articles
- ▶ Access all the published articles
- ▶ Re-use any of the published material for personal use and teaching without further permission

Customer Service

If you have any further queries about your subscription, please contact our customer services team on +44 (0) 207111 1105 or via email at support@bmj.com.

Visit casereports.bmj.com for more articles like this and to become a Fellow