

DEFORMITY

Changes in Thoracic Kyphosis Negatively Impact Sagittal Alignment After Lumbar Pedicle Subtraction Osteotomy

A Comprehensive Radiographic Analysis

Virginie Lafage, PhD,* Christopher Ames, MD,§ Frank Schwab, MD,* Eric Klineberg, MD,† Behrooz Akbarnia, MD,‡ Justin Smith, MD,‡‡ Oheneba Boachie-Adjei, MD,¶ Douglas Burton, MD,|| Robert Hart, MD,** Richard Hostin, MD,†† Christopher Shaffrey, MD,‡‡ Kirkham Wood, MD,§§ Shay Bess, MD,¶¶; and International Spine Study Group

Study Design. Consecutive, multicenter retrospective review.

Objective. To evaluate if change in thoracic kyphosis (TK) has a positive or negative impact on spinopelvic alignment after lumbar pedicle subtraction osteotomy (PSO) with short fusions.

Summary of Background Data. In the setting of sagittal malalignment, the effect of large vertebral resections can now be anticipated in long fusions, but their impact on unfused segments (reciprocal changes [RC]) remains poorly understood.

Methods. A total of 34 adult patients (mean age = 54 years; SD = 12) who underwent lumbar PSO with upper instrumented vertebra below T10 were included. Radiographic analysis included pre- and postassessment of TK, lumbar lordosis (LL), sagittal vertical axis (SVA), T1 spinopelvic inclination (T1SPI), pelvic tilt (PT), and pelvic incidence (PI). Final SVA and PT were analyzed to determine successful realignment. RC in the thoracic spine was designated favorable or unfavorable on the basis of impact on final SVA and PT.

Results. Mean PSO resection was 26°. LL increased from 20° to 49° ($P < 0.001$). SVA improved from 14 to 4 cm ($P < 0.001$), and PT improved from 33° to 25° ($P < 0.001$). Mean increase in TK was 13° ($P = 0.002$) but was unchanged in 11 patients. Five patients had a favorable RC, and 18 patients had an unfavorable RC. Unfavorable

RC was attributed to junctional failure in 6 of 18 patients. Significant differences in the unfavorable RC group included age and greater preoperative PT, PI, SVA, and T1SPI.

Conclusion. Significant postoperative alignment changes can occur through unfused thoracic spinal segments after lumbar PSO. Unfavorable RC may limit optimal correction and lead to clinical failures. Risk factors for unfavorable thoracic RC include older patients, larger preoperative PI and PT, and worse preoperative T1SPI and are not simply due to junctional failure. Care should be taken with selective lumbar fusion and PSO in older patients and in those with severe preoperative spinopelvic parameters.

Key words: junctional failure, PSO, pelvic tilt, sagittal imbalance, selective fusion, spinopelvic alignment. **Spine 2012;37:E180–E187**

From the *NYU Hospital for Joint Diseases, New York, NY; †University of California Davis, Sacramento, CA; ‡San Diego Center for Spinal Disorders, La Jolla, CA; §University of California San Francisco Medical Center, San Francisco, CA; ¶Hospital for Special Surgery, New York, NY; ||University of Kansas Medical Center, Kansas City, KS; **Oregon Health Sciences University, Portland, OR; ††Baylor Scoliosis Center, Plano, TX; ‡‡University of Virginia, Charlottesville, VA; §§Massachusetts General Hospital, Boston, MA; and ¶¶Rocky Mountain Hospital for Children, Denver, CO.

Acknowledgment date: December 21, 2010. Revision date: May 9, 2011. Acceptance date: May 11, 2011.

The manuscript submitted does not contain information about medical device(s)/drug(s).

Corporate/industry funds were received in support of this work. No benefits in any form have been or will be received from a commercial party related directly or indirectly to the subject of this manuscript.

Address correspondence and reprint requests to Virginie Lafage, PhD, 380 2nd Ave, Ste 1001, New York, NY 10010; E-mail: virginie.lafage@gmail.com
DOI: 10.1097/BRS.0b013e318225b926

Adult spinal deformity (ASD) is a complex pathology and encompasses a myriad of clinical presentations. The spectrum of ASD ranges from a segmental abnormality, such as a single-level spondylolisthesis, to a more complex deformity that generates global sagittal and coronal imbalance. ASD patients have repeatedly reported greater pain and loss of function than controls without radiographic evidence of spinal deformity.^{1–5} The diagnosis and treatment of ASD have traditionally focused upon coronal plane deformities; however, the correlation between the magnitude of regional scoliotic curves and patient-reported outcomes remains ill-defined.⁶ Conversely, sagittal parameters such as C7 plumb line,^{6–8} loss of lumbar lordosis (LL),⁶ lateral subluxation,⁶ and, more recently, pelvic retroversion^{8,9} have been demonstrated to correlate with health-related quality-of-life scores such as Scoliosis Research Society Questionnaire (SRS-22), Oswestry Disability Index, and Short Form Health Survey (SF-12).

Patients suffering from sagittal spinal imbalance typically demonstrate a loss of LL and a positive sagittal vertical axis (SVA) (C7 plumb line) but also—if physiologically possible—compensatory mechanisms such as pelvic retroversion, defined by high pelvic tilt (PT) and thoracic hypokyphosis. When

surgery is indicated, pedicle subtraction osteotomy (PSO) can be an effective procedure to restore LL and, therefore, correct the global sagittal deformity.^{10–17} However, one of the challenges of spinal realignment procedures relates to the behavior of the unfused spinal segments and compensatory mechanisms when the patient adopts a standing posture after spinal reconstruction.^{18,19}

Numerous reports^{12,13,16,20–25} have been published on the technique and outcomes after PSO. Recent studies have demonstrated 2 underappreciated mechanisms that determine global postoperative alignment after a PSO: PT and the change in alignment of unfused spinal segments.

- Pelvic retroversion (measured by PT) is a mechanism to allow maximal hip extension and maintain an erect posture despite loss of lordosis. When lordosis is restored, PT often normalizes.^{8,26,27}
- The unfused thoracic spine assumes a hypokyphotic posture for maximal compensation with a positive SVA and loss of LL. Formulas exist that correlate the LL to the thoracic kyphosis (TK) after a successful PSO. However, 2 studies^{8,18} have demonstrated a progressive increase in unfused TK after lumbar PSO.

The objective of this study was to evaluate if the compensatory changes in the unfused thoracic spine after PSO and short fusions have a favorable or unfavorable impact on global spinopelvic alignment after lumbar PSO. Our hypothesis is that changes in TK will improve the final sagittal plane alignment.

MATERIALS AND METHODS

Patient Selection

This study is a multicenter retrospective case review of patients who underwent lumbar PSO surgery. Data were extracted from an institutional review board–approved multicenter database involving 8 sites around the United States and containing a total of 105 lumbar PSOs and 41 thoracic PSOs. Inclusion criteria for this study included adult patients with spinal deformity and complete preoperative and postoperative sagittal radiography, use of lumbar PSO, and fusion limited to T10 and below.

Data Collection

Office charts were reviewed at each site to collect demographic information (age, sex, weight, and height) as well as surgical data. All patients had preoperative and postoperative (minimum 3-month follow-up) radiographic evaluation in a freestanding position. Patients were instructed to assume a comfortable standing posture with feet approximately shoulder width apart. Once the subject adopted this position, the arms were positioned at approximately 45° of forward shoulder flexion,^{25,26} and fingertips were placed on the mid-clavicle. This position has been reported by Horton *et al*²⁸ as an optimal position for evaluating spinal landmarks.

Radiographic films were downloaded from PACS systems (Dicom format; NEMA, Rosslyn, VA) or digitized through a Vidar scanner (Vidar Systems Corp, Herndon, VA) with 75-dpi resolution and 12 gray levels.

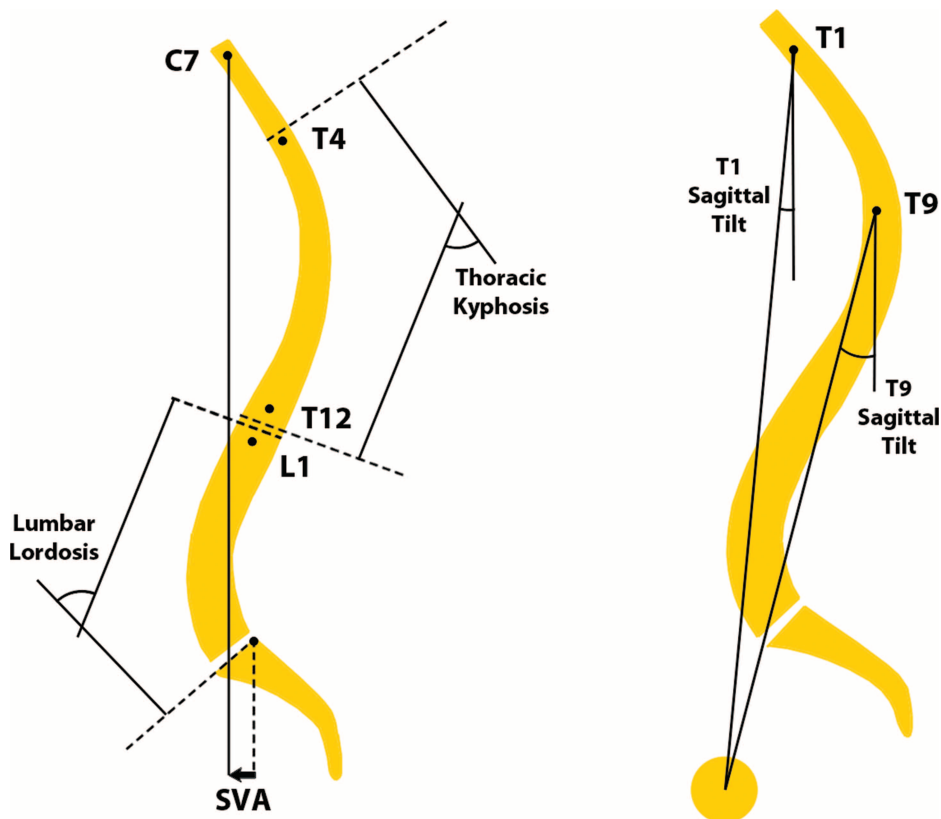


Figure 1. Sagittal spinal radiological parameters.

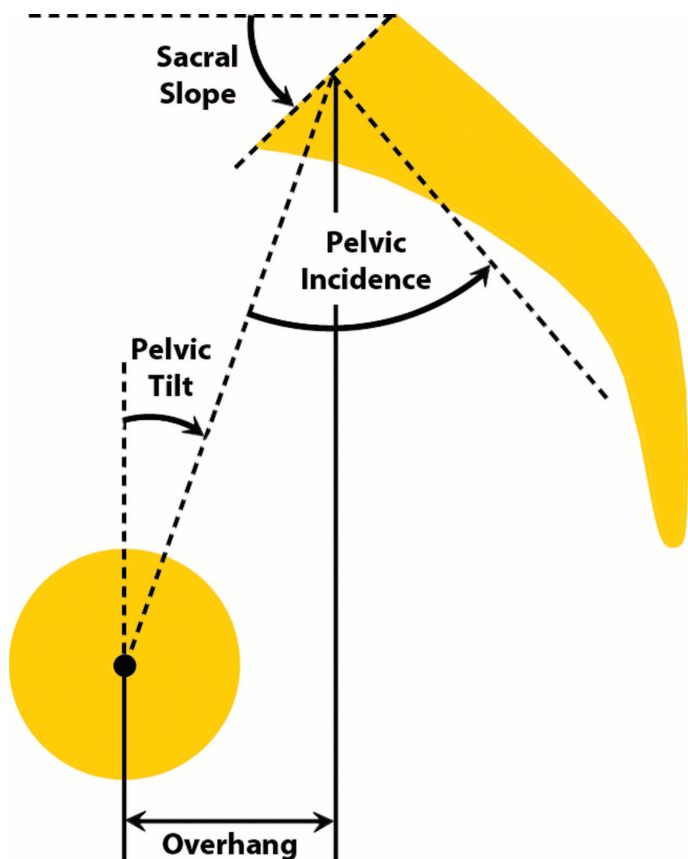


Figure 2. Pelvic parameters.

Radiographic Measurements

Preoperative and postoperative sagittal spinopelvic parameters were evaluated using Spineview software (Surgiview, Paris, France), a validated,^{29,30} computer-based tool that enables quantitative measurements of the spine and pelvis.

Spinal radiographic measures included (Figure 1) L1–S1 lumbar lordosis (LL), the T4–T12 thoracic kyphosis (TK), the T10–L1 thoracolumbar kyphosis, the SVA, and the spinopelvic inclination of T1 (T1SPI) and T9 (T9SPI) (angle between the vertical plumb line and the line drawn from the vertebral body of T1 or T9 and the center of the bicoxofemoral axis).

TABLE 2. Example of Pre- and Postoperative Radiographic Parameters of a Patient With “Unfavorable” Reciprocal Changes, as Illustrated in Figure 4

Parameters	Preoperative	Postoperative	Change
SVA (mm)	214.6	128.1	−86.5
LL (°)	−16.2	19.0	35.1
PI (°)	51.7	53.5	1.8
PT (°)	37.0	33.5	−3.5
PI − LL (°)	67.90	32.8	−35.1
TK (°)	−5.5	−24.4	−19.0

The sagittal pelvic morphology and orientation (Figure 2) were described by the PT, which is the angle between the vertical and the line through the midpoint of the sacral plate to the femoral heads axis (retroversion is then measured as a PT increase; anteversion as a PT decrease), the sacral slope, defined as the angle between the horizontal and the sacral plate, and the pelvic incidence [PI], defined as the angle between the perpendicular to the sacral plate at its midpoint and the line connecting this point to the femoral head axis.

PSO degree of resection (pedicle subtraction angle) was defined as the change of the angle formed by the lower vertebral endplate of the adjacent cephalic vertebra and the upper vertebral endplate of the adjacent caudal vertebra.

Statistical Analysis

Reciprocal changes (RC) in the TK were evaluated, and postoperative SVA and PT were analyzed to determine whether successful realignment was reached (SVA < 4 cm, PT < 20°). RC in the thoracic spine was designated “neutral” if the TK changed by less than 5°; “favorable” if the change in TK countered an excessive negative SVA or decrease of PT; and “unfavorable” if the change in TK did not lead to an optimal correction of SVA or PT.

Changes between preoperative and postoperative spinopelvic alignment were evaluated using a paired *t* test analysis. Differences among groups were analyzed using a 1-way analysis of variance and unpaired *t* test. The level of significance was set to 0.05.

RESULTS

Study Sample

Thirty-four consecutive patients who received a single-level lumbar PSO with an upper instrumented vertebra at or below T10 met inclusion criteria. There were 24 women and 10 men, with a mean age of 54.4 years (SD = 12 years) and a mean body mass index of 25.5 kg/m² (SD = 5.2 kg/m²). Twenty-six patients had previous lumbar spine surgery, and 8 patients had no previous spine surgery.

TABLE 1. Example of Pre- and Postoperative Radiographic Parameters of a Patient With “Favorable” Reciprocal Changes, as Illustrated in Figure 3

Parameters	Preoperative	Postoperative	Change
SVA (mm)	225.5	37.2	−188.2
LL (°)	32.9	77.4	44.5
PI (°)	69.1	70.9	1.8
PT (°)	29.3	16.8	−12.5
PI − LL (°)	35.20	−6.5	−41.7
TK (°)	−26.2	−43.2	−17.0

TABLE 3. Comparison of Preoperative Parameters Among the 2 Groups of Patients

	Unfavorable	Favorable and Neutral	P
Preoperative thoracic kyphosis	-17 ± 14	-28 ± 30	0.077
Preoperative lumbar lordosis*	11 ± 19	24 ± 21	0.038
Preoperative T1 spino-pelvic inclination*	7 ± 4	2 ± 5	0.004
Preoperative SVA*	175 ± 58	103 ± 72	0.002
Preoperative pelvic incidence*	61 ± 10	54 ± 11	0.046
Preoperative pelvic tilt*	36 ± 9	28 ± 12	0.024
Preoperative PI - LL*	49 ± 16	29 ± 18	0.001

Independent t test analysis.
*P < 0.05.

The most common diagnosis was iatrogenic flatback (n = 26), followed by ankylosing spondylitis (n = 2), degenerative flatback (n = 2), infectious spondylitis (n = 1), kyphoscoliosis (n = 1), and posttraumatic kyphosis (n = 1).

The most common sites of PSO were L3 (n = 19), L2 (n = 7), L4 (n = 7), and L1 (n = 1). The mean focal resection angle at the osteotomy site was 26° (SD = 9°; range = 13°-47°), with a mean number of levels fused of 6.4°.

TABLE 4. Comparison of Postoperative Parameters Among the 2 Groups of Patients

	Unfavorable	Favorable and Neutral	P
Postoperative thoracic kyphosis	-36 ± 13	-33 ± 26	0.316
Postoperative lumbar lordosis	46 ± 11	51 ± 20	0.177
Postoperative T1 spino-pelvic inclination*	-2 ± 5	-5 ± 3	0.007
Postoperative SVA*	70 ± 41	14 ± 34	<0.001
Postoperative pelvic incidence*	61 ± 10	54 ± 11	0.046
Postoperative pelvic tilt*	28 ± 9	21 ± 11	0.033
Postoperative PI - LL*	15 ± 9	3 ± 16	0.004

Independent t test analysis.
*P < 0.05.

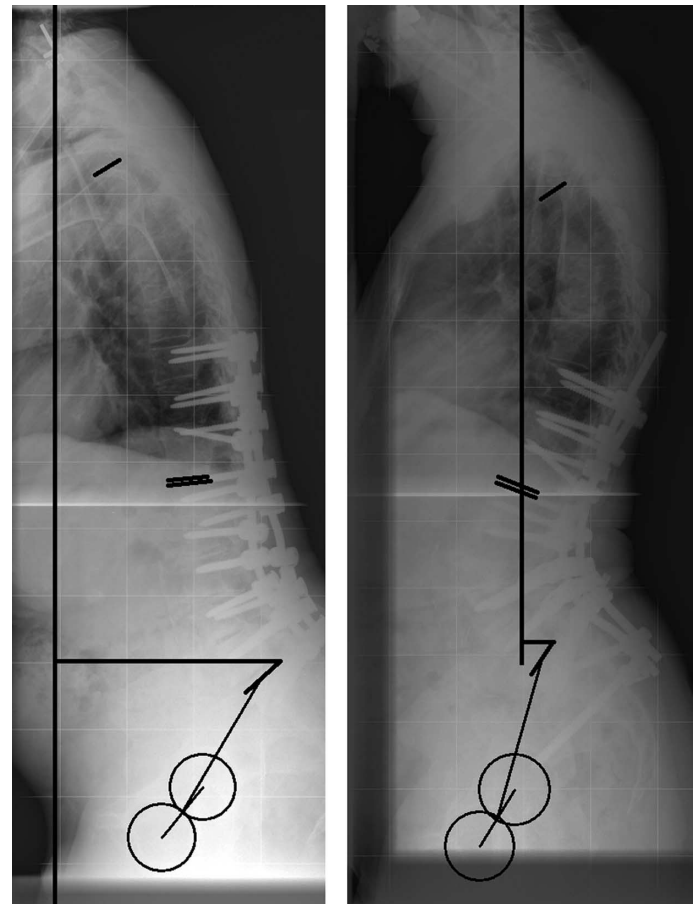


Figure 3. Example of “favorable reciprocal change.” As demonstrated by the pre- and postoperative measurements (Table 1), the application of a 30° PSO at L3 led to an increase of LL (+44.5°), a normalization of the PI minus LL offset, a decrease of SVA (-188 mm) and PT (-12.5°), and an increase of TK (17°). The increase in TK of 17° is the reciprocal change, a secondary effect of modifying other spinopelvic conditions. The latter prevented an excessive correction of the spinopelvic balance.

Pre- to Postoperative Changes and Group Distribution

The PSO surgery led to an increase in LL (17° preoperative to 48° postoperative, P < 0.001), and an increase in TK (22° preoperative to 35° postoperative, P < 0.001). T1SPI decreased postoperatively (5° to -3°, P < 0.001), SVA decreased postoperatively (14 cm to 4 cm, P < 0.001), and PT decreased postoperatively (33° to 25°, P < 0.001).

When analyzing the postoperative change in TK and the impact that the postoperative changes in TK had on postoperative SVA and PT, 3 distinct groups were identified:

- Five patients were classified as “favorable reciprocal change,” meaning that the increase in TK countered an excessive negative SVA or decrease of PT (see sample case Figure 3 and Table 1).
- Eleven patients were classified as “neutral” because they exhibited a change in TK of less than 5°.
- Eighteen patients were classified as “unfavorable reciprocal change,” meaning that the increase in TK “led” to a postoperative SVA more than 4 cm and/or a postoperative PT more than 20° (see sample case Figure 4 and Table 2).

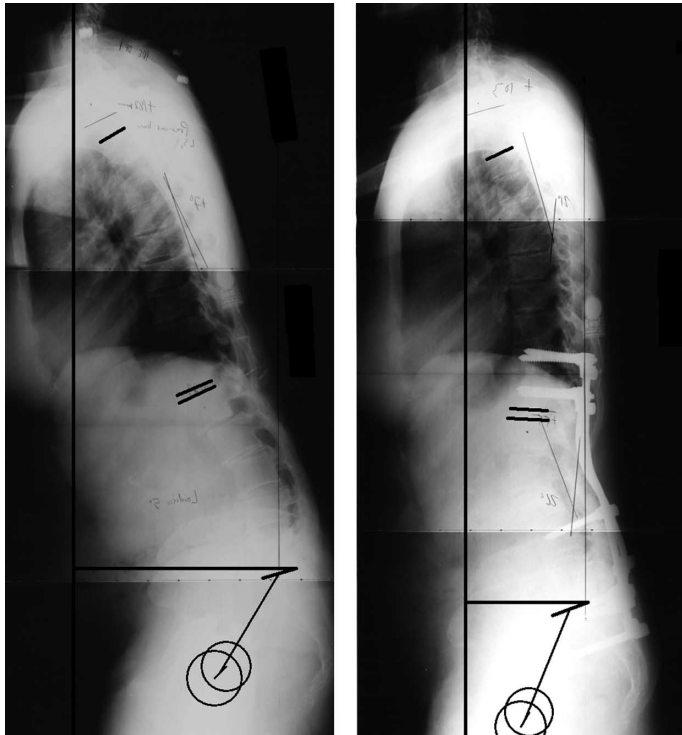


Figure 4. Example of “unfavorable reciprocal change.” As demonstrated by the pre- and postoperative measurements (Table 2), the application of a 30° PSO at L3 led to an increase of LL (+35.1°) with normalization of the PI minus LL offset (postoperative offset = 32.8°). As a result, optimal postoperative alignment was not obtained (postoperative SVA = 128 mm, postoperative PT = 33.5°) due in part to an increase of the TK (+19°). The increase in TK of 19° is the reciprocal change, a secondary effect of modifying other spinopelvic conditions.

Unfavorable RC vs. Neutral and Favorable RC Groups

When comparing the unfavorable RC group with the neutral and favorable RC groups, the following significant differences were noted: the unfavorable RC group was older (59 years *vs.* 49 years, *P* = 0.01) and had greater preoperative sagittal spinal imbalance (Table 3) in terms of SVA (175 mm *vs.* 103 mm, *P* = 0.002), T1SPI (7° *vs.* 2°, *P* = 0.004), loss of LL (11° *vs.* 24°, *P* = 0.038), and pelvic retroversion (36° *vs.* 28°, *P* = 0.024). The unfavorable RC group also had a larger preoperative PI (61° *vs.* 54°, *P* = 0.046). Accordingly, the greater PI combined with a smaller LL indicated a significantly larger PI-LL mismatch in the unfavorable RC group: the difference between those 2 parameters was 49° for the unfavorable RC group and 29° for the combined neutral and favorable RC groups (*P* = 0.001). No significant differences were found in terms of TK, height, or weight.

In terms of postoperative alignment (Table 4), the unfavorable RC group had a larger SVA (70 mm *vs.* 14 mm, *P* < 0.001), a more positive T1SPI (-1.5° *vs.* -5°, *P* = 0.007), and a larger PT (28° *vs.* 21°, *P* = 0.03). The unfavorable RC also had a larger offset between LL and PI, meaning that this group of patients had an inadequate postoperative LL. No other significant differences were noted.

TABLE 5. Comparison of Change in Parameters (Pre to Post) and Surgical Parameters Among the 2 Groups of Patients

	Unfavorable	Favorable and Neutral	<i>P</i>
Change in thoracic kyphosis*	-20 ± 12	-5 ± 10	<0.001
Change in lumbar lordosis	35 ± 16	27 ± 16	0.09
Change in T1 spinopelvic inclination	-8 ± 5	-7 ± 5	0.252
Change in SVA	-104 ± 56	-94 ± 63	0.309
Change in pelvic tilt	-8 ± 8	-7 ± 9	0.350
Upper instrumented vertebrat	11 ± 2	12 ± 2	0.340
Lower instrumented vertebrat	18 ± 1	18 ± 0	0.113
Number of levels fused	6.4 ± 1.69	6.4 ± 1.5	0.49
Site of osteotomy†	15 ± 1	15 ± 1	0.172
Focal resection (PSO)	28 ± 11	24 ± 6	0.114

Independent t test analysis for continuous variable.
 **P* < 0.05.
 †A numerical value has been attributed to each vertebral level, with 1 = T1, 2 = T2 ... 12 = T12, 13 = L1, ... 17 = L5, 18 = pelvis.

The analysis of the preoperative to postoperative changes within the parameters showed that the unfavorable RC group exhibited a larger change in TK (+20° *vs.* +5°, *P* < 0.001) but no difference in the change in LL. Finally, when surgical strategies were analyzed (Table 5), there were no differences in terms of number of levels fused, upper and lower instrumented vertebrae, site of the osteotomy, or focal resection at the osteotomy site.

Proximal Junctional Failure

The analysis of the unfavorable RC group showed that change in TK for this group was attributed to junctional failure in 6 of the 18 patients; junctional failure was defined as a 10° increase of kyphosis across the 2 vertebrae above the instrumentation. All previous findings described for the entire unfavorable RC group were confirmed in a subanalysis focusing only on proximal junctional kyphosis (PJK) patients *vs.* neutral and favorable RCs combined: those patients appear to be even older (65 years *vs.* 49 years, *P* = 0.003) and presented a larger preoperative spinopelvic alignment and larger PI, but underwent the same realignment procedure.

Revision Status

There were 5 of 18 patients in the unfavorable RC group, 3 of 8 patients in the neutral RC group, and 2 of 5 in the favorable RC group who underwent revision due to mechanical

failure within 3 years of the initial surgery. There was no significant difference in the distribution of revision status among the groups ($P = 0.883$).

DISCUSSION

ASD is a broad category that encompasses a diverse group of spinal malalignment patterns. It can range from a simple biplanar and segmental deformity to more complex 3-dimensional global deformities with significant loss of coronal and sagittal alignment. Typically, spinal deformity surgeons attempt to correct the most rigid and deformed portion of the curve to allow for continued flexibility and more normal motion in the nonfused portions. However, these unfused segments are dynamic and allow for ongoing alignment changes to occur. Modification in unfused regions of the spine (RCs) can offer a compensatory mechanism to obtain ideal global alignment. The possibility and impact of RCs must be taken into account, particularly when significant corrections of spinal deformity are attempted with short fusions in the thoracolumbar spine.

The hypothesis of this study was that RCs would “rebalance” the spine, even if a less than satisfactory correction was obtained by a lumbar PSO. This would lead to improved overall sagittal balance and PT. However, the findings from this study reveal that the majority of compensatory changes led to a poorer overall sagittal vertebral alignment and PT and that this alignment could be attributed to changes that occurred through the unfused segments. Over half—18 of 34 (53%)—of the unfused segments exhibited these unfavorable changes, while only 5 of 34 instances (15%) of changes led to improved global alignment. In 11 of 34 instances (32%), thoracic alignment changed less than 5° and was considered a neutral change.

Subanalysis of the groups in this study revealed significant mean differences. The unfavorable RC group was 10 years older (59 years *vs.* 49 years, $P = 0.01$). This is consistent with literature on junctional failures and sagittal decompensation. Kim *et al*³¹ also identify age as being a risk factor for developing sagittal decompensation after long fusion for ASD surgery. In their series, patients who developed thoracic decompensation were 9 years older. It is interesting to note that our study and Kim and colleagues’ report both identified an approximately 10-year average increase in age with similar age group averages for the at-risk population (55 years *vs.* 59 years, respectively). In a previous study investigating alignment changes after specifically lumbar PSO for fixed sagittal imbalance, Hyun and Rhim,³² identified that patients with postoperative progression of TK were older than patients with stable kyphosis. We have also previously reported that patients with a failed realignment surgery were older.³³

In our study, there was no statistically significant difference in preoperative TK when comparing the favorable *vs.* unfavorable change groups, although the unfavorable change group had, on average, 11° less kyphosis than the favorable and no change groups. Furthermore, there was no significant

difference in postoperative kyphosis when comparing the 2 groups; however, there was a significant difference when comparing the change in kyphosis (20° *vs.* 5°). A previous study by Jang *et al*¹⁸ looking at thoracic changes after lumbar surgery for degenerative lumbar flat back noted, on average, a 17.6° increase in TK postoperatively, which correlated to LL restoration. The magnitude of this reported change from Jang and colleagues’ study correlated most closely with the average change in our unfavorable change group. This report, however, did not investigate the direct relationship between reciprocal postoperative TK increase and adequacy of SVA correction.

Because outcomes are directly correlated to SVA correction, T1SPI correction, and PT normalization,^{1,8,26} the frequent occurrence of unfavorable thoracic change is concerning. Extension of fusion to proximal thoracic levels would obviously decrease the incidence of thoracic unfavorable changes as a causative factor in persistent postoperative imbalance. However, in doing so, the patients would be subjected to increased perioperative surgical and medical risks of those larger procedures. The etiology for these unfavorable changes is likely multifactorial and is not explained by over-correction or bone anchorage issues. There was no significant difference in magnitude of SVA correction or postoperative LL between groups, and PJK only accounted for 33% of cases. Importantly, the majority of the unfavorable thoracic alignment changes noted in our study were “not” focal (12 of the 18 unfavorable changes occurred over greater than 2 segments). However, anchorage issues certainly can play a role in focal PJK.

We did observe a statistically significant association of unfavorable changes with greater preoperative imbalance, higher preoperative PT, and higher PI. Furthermore, the mismatch between preoperative LL and PI was 20° higher for the unfavorable group, and this difference was statistically significant. The association between greater preoperative imbalance and risk of persistent postoperative imbalance has been shown previously.^{8,31,34} Additional studies have demonstrated that higher PI requires greater LL for proper spinal balance.^{26,35} Higher PI has also been associated with failed spine surgery and greater postoperative imbalance.³⁶

Despite having greater sagittal imbalance (higher SVA, lower LL) and greater PI, the unfavorable group underwent the same thoracolumbar correction (same levels instrumented, same focal correction, same change in lordosis and SVA change) as the other groups. This raises the suspicion that poor preoperative planning may be a significant causative factor. Persistent offset between the gravity line and the SVA can lead to increased loading of the spine in flexion. Correction strategies that include full restoration of an LL appropriate to the PI and full normalization of the PT, in addition to SVA correction, may help to avoid this gravity line offset and uneven spinal loading. Fusion terminating at the thoracolumbar junction may be particularly susceptible to this flexion loading, leading to unfavorable TK change.

The etiology of failure in older patients is likely multifactorial. The elderly may be particularly susceptible for several reasons. As we age, our ability to compensate for a positive sagittal alignment decreases. This may be in part due to muscular atrophy that occurs in the multifidus. In a series of 25 patients with iatrogenic kyphosis, Husson *et al*³⁷ found that half of the patients had evidence of fatty degeneration of the multifidus. Older patients may lack the muscular reserve needed to counteract the flexion loading of the thoracic spine because of generalized age-related muscular weakness or muscle degeneration. Muscle mass and muscular strength have both been shown to progressively decline with age.³⁸

In addition, the central nervous system may play a role. Older patients may have difficulty in adjusting to acute surgical positional changes of the head in relation to trunk and pelvis. These patients may “prefer” to return to their previously kyphotic position and develop unfavorable RC. Balance test performance has been shown to progressively decline after the third and fourth decade of life in men and women, respectively.³⁹

Previous investigation has focused on the need to extend fusions distally to the sacral pelvic unit in patients with large sagittal imbalance.^{40–45} However, there is little agreement on the extent of cephalad fusion level and upper instrumented vertebra for patients with significant global imbalance and loss of LL.⁴⁶ Studies have shown that patients fused to proximal thoracic levels better maintained their balance correction postoperatively.³⁶ The present study suggests that patients with higher PI and significant global imbalance are at high risk for unfavorable thoracic compensatory changes, which can impact the adequacy of their SVA and PT correction. Consideration for extension of the fusion to the proximal thoracic spine should be carefully considered in these patients and weighed against the increased magnitude of the procedure and their medical comorbidities.

It remains unclear whether optimal angular correction strategies including PI, LL, and PT correction as suggested by this study can decrease the incidence of non-PJK-related sagittal thoracic decompensation after lumbar PSO and thoracolumbar fusion that does not extend to the proximal thoracic spine. Age-related muscular and imbalance issues may remain a confounding variable.

CONCLUSION

Significant postoperative alignment changes can occur through unfused thoracic spinal segments after lumbar PSO. Risk factors for unfavorable thoracic RC include older patients, larger preoperative PI and PT, and worse preoperative T1SPI. The negative RCs involve a global increase in kyphosis that occurs through the unfused spinal segments and are not simply due to proximal junctional failure. Care should be taken with selective lumbar fusion and PSO in older patients and those with unfavorable preoperative spinopelvic parameters. Patients with marked preoperative malalignment and high PI need more angular correction and strong consideration for extension of the fusion to proximal thoracic levels.

➤ Key Points

- ❑ Lumbar PSO in the setting of short fusion leads to changes in the TK alignment (RC).
- ❑ The majority of patients with RC in the TK had a poor postoperative spinopelvic balance (“unfavorable” RC).
- ❑ Most unfavorable RCs were not due to junctional failure.
- ❑ Risk factors for unfavorable RC were larger PI, inadequate postoperative LL, and older patients.

Acknowledgments

Grant support received by Depuy Spine. Data were gathered from 8 spinal deformity referral centers across the United States. Institutional review board approval was obtained by each participating site.

References

1. Glassman SD, Bridwell K, Dimar JR, et al. The impact of positive sagittal balance in adult spinal deformity. *Spine (Phila Pa 1976)* 2005;30:2024–9.
2. Bess S, Boachie-Adjei O, Burton D, et al. Pain and disability determine treatment modality for older patients with adult scoliosis, while deformity guides treatment for younger patients. *Spine (Phila Pa 1976)* 2009;34:2186–90.
3. Schwab F, Dubey A, Pagala M, et al. Adult scoliosis: a health assessment analysis by SF-36. *Spine (Phila Pa 1976)* 2003;28:602–6.
4. Smith JS, Shaffrey CI, Berven S, et al. Improvement of back pain with operative and nonoperative treatment in adults with scoliosis. *Neurosurgery* 2009;65:86–93; discussion 93–4.
5. Smith JS, Shaffrey CI, Berven S, et al. Operative versus nonoperative treatment of leg pain in adults with scoliosis: a retrospective review of a prospective multicenter database with two-year follow-up. *Spine (Phila Pa 1976)* 2009;34:1693–8.
6. Schwab F, Farcy JP, Bridwell K, et al. A clinical impact classification of scoliosis in the adult. *Spine (Phila Pa 1976)* 2006;31:2109–14.
7. Glassman SD, Berven S, Bridwell K, et al. Correlation of radiographic parameters and clinical symptoms in adult scoliosis. *Spine (Phila Pa 1976)* 2005;30:682–8.
8. Lafage V, Schwab F, Patel A, et al. Pelvic tilt and truncal inclination: two key radiographic parameters in the setting of adults with spinal deformity. *Spine (Phila Pa 1976)* 2009;34:E599–606.
9. Lazennec JY, Ramare S, Arafati N, et al. Sagittal alignment in lumbosacral fusion: relations between radiological parameters and pain. *Eur Spine J* 2000;9:47–55.
10. Booth KC, Bridwell KH, Lenke LG, et al. Complications and predictive factors for the successful treatment of flatback deformity (fixed sagittal imbalance). *Spine (Phila Pa 1976)* 1999;24:1712–20.
11. Bridwell KH, Lewis SJ, Edwards C, et al. Complications and outcomes of pedicle subtraction osteotomies for fixed sagittal imbalance. *Spine (Phila Pa 1976)* 2003;28:2093–101.
12. Bridwell KH, Lewis SJ, Lenke LG, et al. Pedicle subtraction osteotomy for the treatment of fixed sagittal imbalance. *J Bone Joint Surg Am* 2003;85-A:454–63.
13. Buchowski JM, Bridwell KH, Lenke LG, et al. Neurologic complications of lumbar pedicle subtraction osteotomy: a 10-year assessment. *Spine (Phila Pa 1976)* 2007;32:2245–52.
14. Kim YJ, Bridwell KH, Lenke LG, et al. Results of lumbar pedicle subtraction osteotomies for fixed sagittal imbalance: a minimum 5-year follow-up study. *Spine (Phila Pa 1976)* 2007;32:2189–97.
15. Mummaneni PV, Dhall SS, Ondra SL, et al. Pedicle subtraction osteotomy. *Neurosurgery* 2008;63:171–6.
16. Rose PS, Bridwell KH, Lenke LG, et al. Role of pelvic incidence, thoracic kyphosis, and patient factors on sagittal plane correction

- following pedicle subtraction osteotomy. *Spine (Phila Pa 1976)* 2009;34:785–91.
17. Yang BP, Ondra SL, Chen LA, et al. Clinical and radiographic outcomes of thoracic and lumbar pedicle subtraction osteotomy for fixed sagittal imbalance. *J Neurosurg Spine* 2006;5:9–17.
 18. Jang JS, Lee SH, Min JH, et al. Influence of lumbar lordosis restoration on thoracic curve and sagittal position in lumbar degenerative kyphosis patients. *Spine (Phila Pa 1976)* 2009;34:280–4.
 19. Newton PO, Yaszay B, Upasani VV, et al. Preservation of thoracic kyphosis is critical to maintain lumbar lordosis in the surgical treatment of adolescent idiopathic scoliosis. *Spine (Phila Pa 1976)* 2010;35:1365–70.
 20. Chiffolot X, Lemaire JP, Bogorin I, et al. Pedicle closing-wedge osteotomy for the treatment of fixed sagittal imbalance [in French]. *Rev Chir Orthop Reparatrice Appar Mot* 2006;92:257–65.
 21. Gill JB, Levin A, Burd T, et al. Corrective osteotomies in spine surgery. *J Bone Joint Surg Am* 2008;90:2509–20.
 22. Heary RF, Bono CM. Pedicle subtraction osteotomy in the treatment of chronic, posttraumatic kyphotic deformity. *J Neurosurg Spine* 2006;5:1–8.
 23. Ikenaga M, Shikata J, Takemoto M, et al. Clinical outcomes and complications after pedicle subtraction osteotomy for correction of thoracolumbar kyphosis. *J Neurosurg Spine* 2007;6:330–6.
 24. Murrey DB, Brigham CD, Kiebzak GM, et al. Transpedicular decompression and pedicle subtraction osteotomy (eggshell procedure): a retrospective review of 59 patients. *Spine (Phila Pa 1976)* 2002;27:2338–45.
 25. van Loon PJ, van Stralen G, van Loon CJ, et al. A pedicle subtraction osteotomy as an adjunctive tool in the surgical treatment of a rigid thoracolumbar hyperkyphosis; a preliminary report. *Spine J* 2006;6:195–200.
 26. Schwab F, Lafage V, Patel A, et al. Sagittal plane considerations and the pelvis in the adult patient. *Spine (Phila Pa 1976)* 2009;34:1828–33.
 27. Aurouer N, Obeid I, Gille O, et al. Computerized preoperative planning for correction of sagittal deformity of the spine [published online ahead of print July 14, 2009]. *Surg Radiol Anat*.
 28. Horton WC, Brown CW, Bridwell KH, et al. Is there an optimal patient stance for obtaining a lateral 36° radiograph? A critical comparison of three techniques. *Spine (Phila Pa 1976)* 2005;30:427–33.
 29. Rillardon L, Levassor N, Guigui P, et al. Validation of a tool to measure pelvic and spinal parameters of sagittal balance [in French]. *Rev Chir Orthop Reparatrice Appar Mot* 2003;89:218–27.
 30. Champain S, Benchikh K, Nogier A, et al. Validation of new clinical quantitative analysis software applicable in spine orthopaedic studies. *Eur Spine J* 2006;15:982–91.
 31. Kim YJ, Bridwell KH, Lenke LG, et al. Sagittal thoracic decompensation following long adult lumbar spinal instrumentation and fusion to L5 or S1: causes, prevalence, and risk factor analysis. *Spine (Phila Pa 1976)* 2006;31:2359–66.
 32. Hyun SJ, Rhim SC. Clinical outcomes and complications after pedicle subtraction osteotomy for fixed sagittal imbalance patients: a long-term follow-up data. *J Korean Neurosurg Soc* 2010;47:95–101.
 33. Lafage V, Schwab FJ, Smith JS, et al. *PSO Failures Can Be Predicted by High Pre-Op SVA and Pelvic Tilt*. Salt Lake City, UT: Scoliosis Research Society; 2009.
 34. Cho KJ, Suk SI, Park SR, et al. Risk factors of sagittal decompensation after long posterior instrumentation and fusion for degenerative lumbar scoliosis. *Spine (Phila Pa 1976)* 2010;35:1595–601.
 35. Schwab F, Lafage V, Boyce R, et al. Gravity line analysis in adult volunteers: age-related correlation with spinal parameters, pelvic parameters, and foot position. *Spine (Phila Pa 1976)* 2006;31:E959–67.
 36. Gottfried ON, Daubs MD, Patel AA, et al. Spinopelvic parameters in postfusion flatback deformity patients. *Spine J* 2009;9:639–47.
 37. Husson JL, Mallet JF, Parent H, et al. The lumbar-pelvic-femoral-complex: applications in spinal imbalance. *Orthop Traumatol Surg Res* 2010;96S:1–9.
 38. Kallman DA, Plato CC, Tobin JD. The role of muscle loss in the age-related decline of grip strength: cross-sectional and longitudinal perspectives. *J Gerontol* 1990;45:M82–8.
 39. Balogun JA, Akindele KA, Nihinlola JO, et al. Age-related changes in balance performance. *Disabil Rehabil* 1994;16:58–62.
 40. Cho KJ, Suk SI, Park SR, et al. Arthrodesis to L5 versus S1 in long instrumentation and fusion for degenerative lumbar scoliosis. *Eur Spine J* 2009;18:531–7.
 41. Swamy G, Berven SH, Bradford DS. The selection of L5 versus S1 in long fusions for adult idiopathic scoliosis. *Neurosurg Clin N Am* 2007;18:281–8.
 42. Bridwell KH. Where to stop the fusion distally in adult scoliosis: L4, L5, or the sacrum? *Instr Course Lect* 1996;45:101–7.
 43. Cho KJ, Lenke LG, Bridwell KH, et al. Selection of the optimal distal fusion level in posterior instrumentation and fusion for thoracic hyperkyphosis: the sagittal stable vertebra concept. *Spine (Phila Pa 1976)* 2009;34:765–70.
 44. Eck KR, Bridwell KH, Ungacta FF, et al. Complications and results of long adult deformity fusions down to L4, L5, and the sacrum. *Spine (Phila Pa 1976)* 2001;26:E182–92.
 45. Bridwell KH, Edwards CC II, Lenke LG. The pros and cons to saving the L5–S1 motion segment in a long scoliosis fusion construct. *Spine (Phila Pa 1976)* 2003;28:S234–42.
 46. Kim YJ, Bridwell KH, Lenke LG, et al. Is the T9, T11, or L1 the more reliable proximal level after adult lumbar or lumbosacral instrumented fusion to L5 or S1? *Spine (Phila Pa 1976)* 2007;32:2653–61.