



Contents lists available at ScienceDirect

International Journal of Surgery Case Reports

journal homepage: www.casereports.com

A rare case of recurrent malignant triton tumor in a male with NF1: Case report and mini-review

B. Aykut^a, K. Wiczorek^b, P. Schirmacher^b, M.W. Büchler^a, K. Hoffmann^{a,*}^a Department of General, Visceral, and Transplant Surgery, University Hospital Heidelberg, Im Neuenheimer Feld 110, 69120 Heidelberg, Germany^b Department of Pathology, University of Heidelberg, Im Neuenheimer Feld 224, 69120 Heidelberg, Germany

ARTICLE INFO

Article history:

Received 16 October 2015

Received in revised form 29 February 2016

Accepted 3 March 2016

Available online 8 March 2016

Keywords:

Peripheral nerve sheath tumor

Surgical oncology

Malignant triton tumor

ABSTRACT

BACKGROUND: Malignant triton tumors (MTT) represent a rare subset of tumors with rhabdomyoblastic differentiation within the heterogeneous group of malignant peripheral nerve sheath tumors (MPNST). **CASE PRESENTATION:** Here, we report on a case of a 25 year-old male with a history of neurofibromatosis type I and MTT of the mediastinal wall who presented in our clinic with a pelvic tumor and multiple hyper-vascular mesenteric masses and underwent resection. Upon resection, histological findings revealed an MTT of the omentum and an atypical neurofibroma of the pelvis with focal transitions to a low-grade MPNST. The patient relapsed just one month later and died 3 months after the surgery.

CONCLUSION: Clinically, MTTs are characterized as highly aggressive tumors that are fast-growing and prone to local recurrence and distant metastasis. To date, there is no treatment consensus available yet and many patients succumb to the disease shortly after diagnosis. This is because the pathogenesis of MTT remains unknown and patients with MTT are often diagnosed at a late stage of disease. Our case presents valuable teaching points in terms of providing a possible progression model based on the coexistence of a low-grade MPNST and MTT in the context of NF1 and an atypical neurofibroma in this patient. Close monitoring of patients with NF1 and atypical neurofibromas or MPNST might therefore help to diagnose MTT at an earlier stage.

© 2016 The Authors. Published by Elsevier Ltd. on behalf of IJS Publishing Group Ltd. This is an open access article under the CC BY-NC-ND license (<http://creativecommons.org/licenses/by-nc-nd/4.0/>).

1. Introduction

Malignant triton tumor (MTT) is an extremely rare type of sarcoma that arises from peripheral nerve sheaths. This tumor is thought to originate from Schwann cells of peripheral nerves or within existing neurofibromas and is characterized by the coexistence of malignant rhabdomyoblasts and malignant Schwann cells [19]. The first description of MTT dates back to 1932, when Mason described rhabdomyosarcomatous elements within malignant peripheral nerve sheath tumors (MPNST) in patients with neurofibromatosis. To date, approximately 170 cases of MTT have been described in the literature of which more than 50% had previously been diagnosed with neurofibromatosis 1 (von Recklinghausen's disease, NF1) (Woodruff et al., 2000). We report on a rare case of

MTT of the omentum in a patient with NF1 and a history of MTT of the mediastinal wall.

2. Case report

A 25 year-old man with NF1 who had previously been diagnosed with MTT was referred to the Heidelberg University Hospital in October 2014. He had been diagnosed with atypical extrapleural neurofibroma in 2010 and had undergone right posterolateral thoracotomy with resection of the seventh to twelfth rib along with partial resection of the right hemidiaphragm. Following this, the patient had observed a growing mass of his right chest wall. Surgical exploration in September 2014 revealed a 10 × 10 cm measuring round mass that was infiltrating the adjacent muscular tissue. However, no organ infiltration could be observed. The mass was completely resected with partial resection of the 11th and 12th ribs. Microscopic examination of this tumor revealed a MTT with complete negative margins (R0) and the patient was referred to Heidelberg University Hospital for further oncologic treatment. Upon presentation of the case to our tumor-board, the patient underwent adjuvant radiotherapy in shrinking field technique with 5 × 1.8 Gy/week up to 63.0 Gy from November until December 2014. The patient presented in our Surgical Department in January 2015 after a pelvic mass had been discovered

Abbreviations: MTT, malignant triton tumor; MPNST, malignant peripheral nerve sheath tumor; NF1, neurofibromatosis type 1.

* Corresponding author.

E-mail addresses: Berk.Aykut@med.uni-heidelberg.de (B. Aykut), Kathrin.Wiczorek@med.uni-heidelberg.de (K. Wiczorek), Peter.Schirmacher@med.uni-heidelberg.de (P. Schirmacher), Markus.Buechler@med.uni-heidelberg.de (M.W. Büchler), Katrin.Hoffmann@med.uni-heidelberg.de (K. Hoffmann).

<http://dx.doi.org/10.1016/j.ijscr.2016.03.003>

2210-2612/© 2016 The Authors. Published by Elsevier Ltd. on behalf of IJS Publishing Group Ltd. This is an open access article under the CC BY-NC-ND license (<http://creativecommons.org/licenses/by-nc-nd/4.0/>).

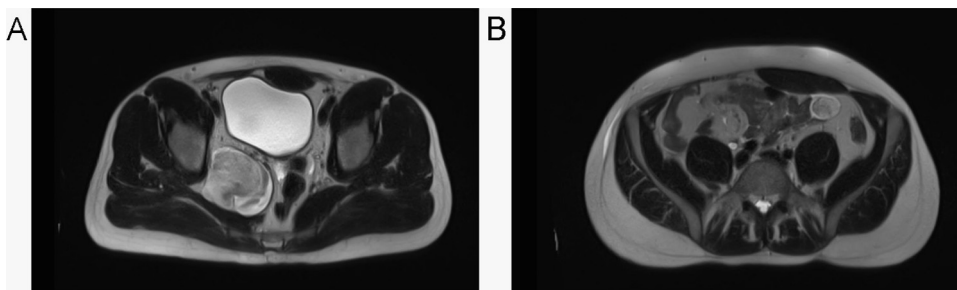


Fig. 1. T2 abdominal and pelvic MRI with contrast on February 13th, 2015 revealed the previously known pelvic tumor (A) along with newly formed hypervascular mesenteric masses (B).

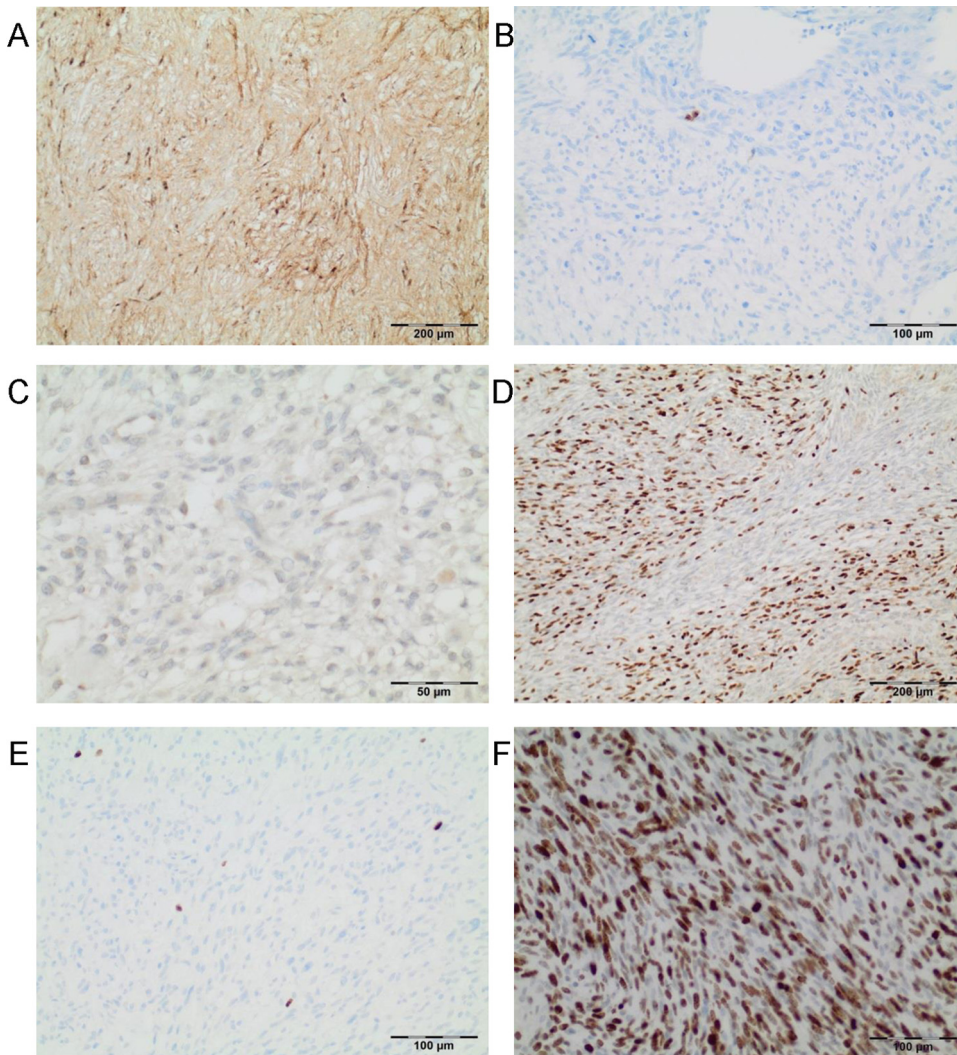


Fig. 2. Microscopically, the pelvic tumor was composed of spindle cells expressing the neurogenic differentiation marker S100 (A). The pelvic tumor did not show any rhabdomyosarcomatous differentiation as indicated by absent Myogenin expression (C) and had a Ki67-proliferative index of 1–3% (E), in line with a low-grade MPNST. Immunohistochemical stainings of the mesenteric nodules showed spindle cells without expression of S100 (B), however, with focally abundant expression of Myogenin (D) and a Ki67-proliferative index of 70–80% (F).

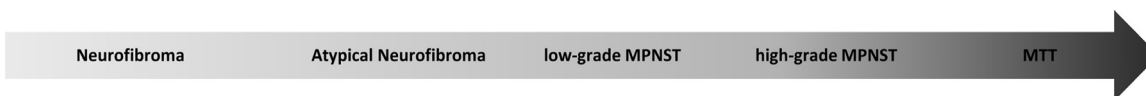


Fig. 3. Progression model for MTT.

during follow-up. Physical examination did not reveal any significant abnormalities. Laboratory findings were all within normal

limits except for NSE, which was slightly elevated. Abdominal and pelvic magnetic resonance imaging revealed a 7.0 × 6.5 cm pelvic

mass along with previously unknown hypervascular mesenteric masses and the patient was worked-up for exploratory laparotomy (Fig. 1). Upon laparotomy, approximately 8–10 omental nodules were discovered without evidence of intestinal or abdominal wall manifestations of the disease. We therefore decided to perform an omentectomy. In line with preoperative findings, another mass could be palpated in the right lesser pelvis, which macroscopically appeared to originate from the obturator nerve. By opening the nerve sheath, we could extirpate the mass while sparing the nerve. Histopathological examination of the pelvic mass revealed an atypical neurofibroma with pluri- and multifocal transitions to a low-grade MPNST. Immunohistochemically, the spindle-shaped tumor cells homogenously expressed Protein S100 and p53 without evidence of expression of Desmin, Aktin, Caldesmon, Myogenin or CD34 and a Ki67-proliferative index of 1–3% (Fig. 2). Histopathological examination of the mesenteric nodules revealed an MTT characterized by an MPNST with abundant rhabdomyosarcomatous differentiation. Immunohistochemical staining showed homogenous expression of CD56 and Vimentin with focal distribution of myogenin, desmin, aktin and neurofilament expressing cells and a Ki67-proliferative index of 70–80%. Immunohistochemical stainings were negative for Protein S100, GFAP, Neurofibromin, Synaptophysin, Caldesmon, CD34 and CD57 (Fig. 2). After surgical treatment, the patient was discharged. However, one month later he relapsed with multiple abdominal and thoracic masses and died 3 months after the surgery.

3. Discussion

constitute a heterogenous group of malignant tumors of ectomesenchymal origin. They arise from major or minor peripheral nerve branches or from peripheral nerve fiber sheaths [1–3]. The confusing terminology that describes these tumors as malignant schwannoma, malignant neurilemmoma, neurofibrosarcoma or neurogenic sarcoma has been replaced by the term MPNST that has been coined for tumors of neurogenic origin and similar biological behavior [4,5]. MPNST may arise sporadically, however, 5–42% of all MPNST are associated with NF1 and approximately 10% of NF1 patients develop MPNST [6–9]. NF1 is an autosomal dominant inherited multisystem disorder that is clinically characterized by light brown skin spots (café au lait spots), colored bumps on the iris (Lisch nodules) and neurofibromas and affects 1 in 3500 people [10]. While MPNST can be histologically diverse, their clinical behavior is often aggressive with a tendency to recur and to metastasize. Large tumor size, association with NF1, truncal location as well as a high grading and a mitotic index of greater than 6/10 high-power fields have been identified as predictive factors for a poorer prognosis [11,12]. The overall survival rate for MPNST has been reported to be 34–44% with radical surgery continuing to be the mainstay of current management owing to the limited sensitivity toward both chemotherapy and radiation. Epitheloid as well as rhabdomyoblastic, cartilaginous, osseous differentiations and, rarely, smooth muscle, glandular or liposarcomatous components can be observed in up to 15% of MPNST [13–15]. The most common heterologous component in MPNST is rhabdomyoblastic differentiation [16]. This differentiation pattern was first reported by Masson in 1932 and named “nerve rhabdomyoma”, and later renamed by Woodruff as “malignant triton tumor” in 1973 [17]. 44–69% of MTTs occur in association with NF1. The average age of patients with MTT is 31.7 without a gender difference. Clinically, MTTs are characterized by their aggressive behavior and a dismal prognosis with a five-year survival rate of 12–26% [18]. Like MPNST, MTTs are insensitive to chemotherapy and radiation. While several authors have reported that R0 resection followed by adjuvant chemotherapy may yield disease control, there is need for further

studies to ascertain the exact role of chemo- and radiotherapy. To date, the pathogenesis of MTT remains unknown. We report here the first case of a low-grade MPNST and concomitant MTT in the context of NF1 and an atypical neurofibroma. This unusual presentation of disease suggests that MTT, rather than representing a distinct entity of cancer, are dedifferentiated MPNST that arise from atypical neurofibromas (Fig. 3). While further studies are needed to validate our hypothesis, this case might provide grounds for active surveillance of NF1 patients with a medical history of atypical neurofibromas and/or MPNST. Furthermore, the aggressive course of disease in the presented case with the occurrence of metastatic lesions 4 months after complete resection gives rise to the question if chemotherapy, albeit unproven in efficacy, can eradicate subclinical micrometastases.

Competing interests

The authors have declared that no competing interest exists.

Funding

This Case Report was funded by the Department of General, Visceral and Transplantation Surgery, Heidelberg University Hospital.

Ethical Approval

Ethics Committee of the University Hospital of Heidelberg.

Consent

Written informed consent was obtained from the patient for publication of this case report and any accompanying images.

Author's contributions

MB participated in the surgery of this case. KW and PS were involved in the pathological work-up of the specimens. BA and KH drafted the manuscript and all authors read and approved the final manuscript.

Guarantor

Katrin Hoffmann and Berk Aykut.

Acknowledgements

We thank General Surgery department and our general surgery colleagues at Heidelberg University Hospital who provided support for this patient.

References

- [1] L. Angelov, A. Guha, Peripheral nerve tumors, in: M. Berstein, M.S. Berger (Eds.), *Neuro Oncology Essentials*, 1, New York Theme Publishers, 2000, pp. 434–444.
- [2] D.V. Cashen, R.C. Parisien, K. Raskin, F.J. Hornicek, M.C. Gebhardt, H.J. Mankin, Survival data for patients with malignant schwannoma, *Clin. Orthop. Relat. Res.* 426 (2004) 69–73.
- [3] T. Hirose, B.W. Scheithauer, T. Sano, Perineurial malignant peripheral nerve sheath tumor (MPNST): a clinicopathologic, immunohistochemical, and ultrastructural study of seven cases, *Am. J. Surg. Pathol.* 22 (11) (1998) 1368–1378.
- [4] J.E. Wanebo, J.M. Malik, S.R. VandenBerg, H.J. Wanebo, N. Driesen, J.A. Persing, Malignant peripheral nerve sheath tumors. A clinicopathologic study of 28 cases, *Cancer* 71 (4) (1993) 1247–1253.
- [5] T.K. Dasgupta, P.K. Choudhuri, *Tumors of Soft Tissue*, 2, Appleton & Lange, Connecticut, 1998, pp. 127–395.
- [6] A.P. Stout, *Tumors of Peripheral Nervous System: Atlas of Tumor Pathology, Sect. 2, Fasc. 6*, Armed Forces Institute of Pathology, Washington D.C., 1949.

- [7] R.D. Brasfield, T.K. Das Gupta, Von Recklinghausen's disease: a clinicopathological study, *Ann. Surg.* 175 (1972) 86–104.
- [8] D.G. Evans, M.E. Baser, J. McGaughran, S. Sharif, E. Howard, A. Moran, Malignant peripheral nerve sheath tumours in neurofibromatosis 1, *J. Med. Genet.* 39 (5) (2002) 311–314.
- [9] R.E. Friedrich, L. Kluwe, C. Funsterer, V.F. Mautner, Malignant peripheral nerve sheath tumors (MPNST) in neurofibromatosis type 1 (NF1): diagnostic findings on magnetic resonance images and mutation analysis of the NF1 gene, *Anticancer Res.* 25 (3A) (2005) 1699–1702.
- [10] K.P. Boyd, B.R. Korf, A. Theos, Neurofibromatosis type 1, *J. Am. Acad. Dermatol.* 61 (1) (2009) 1–14, <http://dx.doi.org/10.1016/j.jaad.2008.12.051>, quiz 15–16.
- [11] C.C. Stucky, K.N. Johnson, R.J. Gray, B.A. Pockaj, I.T. Ocal, P.S. Rose, N. Wasif, Malignant peripheral nerve sheath tumors (MPNST): the Mayo Clinic experience, *Ann. Surg. Oncol.* 19 (3) (2012) 878–885, <http://dx.doi.org/10.1245/s10434-011-1978-7>.
- [12] B.S. Ducatman, B.W. Scheithauer, D.G. Piepgras, H.M. Reiman, D.M. Ilstrup, Malignant peripheral nerve sheath tumors. A clinicopathologic study of 120 cases, *Cancer* 57 (10) (1986) 2006–2021.
- [13] F.J. Rodriguez, A.L. Folpe, C. Giannini, A. Perry, Pathology of peripheral nerve sheath tumors: diagnostic overview and update on selected diagnostic problems, *Acta Neuropathol.* 123 (3) (2012) 295–319, <http://dx.doi.org/10.1007/s00401-012-0954-z>.
- [14] T.N. Suresh, M.L. Harendra Kumar, C.S. Prasad, R. Kalyani, K. Borappa, Malignant peripheral nerve sheath tumor with divergent differentiation, *Indian J. Pathol. Microbiol.* 52 (1) (2009) 74–76.
- [15] K. Janczar, K. Tybor, M. Jozefowicz, W. Papierz, Low grade malignant peripheral nerve sheath tumor with mesenchymal differentiation: a case report, *Pol. J. Pathol.* 62 (4) (2011) 278–281.
- [16] C.J. Stasik, O. Tawfik, Malignant peripheral nerve sheath tumor with rhabdomyosarcomatous differentiation (malignant triton tumor), *Arch. Pathol. Lab. Med.* 130 (12) (2006) 1878–1881, [http://dx.doi.org/10.1043/1543-2165\(2006\)130\[1878:MPNSTW\]2.0.CO;2](http://dx.doi.org/10.1043/1543-2165(2006)130[1878:MPNSTW]2.0.CO;2).
- [17] J.M. Woodruff, N.L. Chernik, M.C. Smith, W.B. Millett, F.W. Foote Jr., Peripheral nerve tumors with rhabdomyosarcomatous differentiation (malignant triton tumors), *Cancer* 32 (2) (1973) 426–439.
- [18] J.S. Brooks, M. Freeman, H.T. Enterline, Malignant triton tumors. natural history and immunohistochemistry of nine new cases with literature review, *Cancer* 55 (11) (1985) 2543–2549.
- [19] Y. Daimaru, H. Hashimoto, M. Enjoji, Malignant triton tumors: a clinicopathologic and immunohistochemical study of nine cases, *Hum. Pathol.* 15 (8) (1984) 768–778.

Open Access

This article is published Open Access at sciedirect.com. It is distributed under the [IJSCR Supplemental terms and conditions](#), which permits unrestricted non commercial use, distribution, and reproduction in any medium, provided the original authors and source are credited.