

# Synchronous Abdominal Wall and Small-bowel Transplantation: A 1-year Follow-up

Andrew Atia, MD\*  
 Andrew Hollins, MD\*  
 Ralph F. Erdmann\*  
 Ronnie Shammass, MD\*  
 Debra L. Sudan, MD†  
 Suhail K. Mithani, MD\*  
 Kadiyala V. Ravindra, MBBS†  
 Detlev Erdmann, MD, PhD,  
 MHS\*

**Summary:** Abdominal wall–vascularized composite allotransplantation (AW-VCA) has evolved as a technically feasible but challenging option in the rare event of abdominal wall reconstruction in patients whose abdomen cannot be closed by applying conventional methods. The authors conducted the first synchronous child-to-adult recipient AW-VCA using an arteriovenous loop technique. This article presents a 1-year follow-up of the patient's postoperative course. Frequent skin biopsies were performed in accordance with Duke Institutional Review Board protocol, with 3 episodes of rejection treated with high-dose steroids and Thymoglobulin (Genzyme Corp, Cambridge, Mass.). The patient developed an opportunistic fungal brain abscess secondary to immunosuppression, which led to temporary upper extremity weakness. Future considerations for AW-VCA include a modified surgical technique involving utilization of donor vein graft for arteriovenous loop formation. In addition, reduction in postoperative biopsy schedule and changes in immunosuppression regimen may lead to improved outcomes and prevent unnecessary high-dose immunosuppression. (*Plast Reconstr Surg Glob Open* 2020;8:e2995; doi: [10.1097/GOX.0000000000002995](https://doi.org/10.1097/GOX.0000000000002995); Published online 24 July 2020.)

## INTRODUCTION

Abdominal wall–vascularized composite allotransplantation (AW-VCA) has evolved as a technically feasible option in the rare event of abdominal wall (AW) reconstruction in patients whose abdomen cannot be closed by applying conventional methods.<sup>1–3</sup> As of today, all reported AW-VCA have been performed in conjunction with either intestinal transplantation (IT) or (multi-) visceral transplantation (MVT). In such cases, factors including prior trauma, repeated laparotomies, enterocutaneous fistulae, multiple ostomy revisions, and exhaustion of local reconstructive options lead to AW loss of domain, extensive scarring, and overall poor local tissue quality.<sup>4,5</sup> However, successful AW revascularization in the setting of IT or MVT may pose a major challenge considering graft

ischemia time, operating in a limited surgical field, and with variable recipient and donor anatomy. Several techniques have been reported to accomplish AW revascularization.<sup>6</sup> None of them are considered ideal in terms of location of recipient vascular access, possible prolonged AW-VCA ischemia time, and planned reoperation. The authors conducted the first synchronous child-to-adult recipient AW-VCA using a newly described AV-loop technique in October 2018, thereby eliminating most concerns with previously described AV-VCA revascularization techniques.<sup>7</sup> In the following, the patient's postoperative course, including graft monitoring, immunosuppression, and adverse events, is described in detail. Considerations for future AW-VCA are presented.

## CASE REPORT

The patient, a 37-year-old Army veteran with a history of perforated appendicitis during early childhood, underwent several laparotomies for lysis of adhesions and intestinal obstruction over 2 decades. In 2014, he developed a new small-bowel obstruction and presented to an outside hospital. An emergently initiated lysis of adhesions resulted in multiple inadvertent enterotomies and led to the catastrophic scenario of discontinuation of his gastrointestinal tract by proximal stapling, and an open abdomen. He was transferred to Duke University Medical Center at that time for further management. The patient became dependent on total parenteral nutrition and developed multiple high-output small-bowel enterocutaneous fistulas.

From the \*Division of Plastic, Maxillofacial, and Oral Surgery, Department of Surgery, Duke University Medical Center, Durham, N.C.; and †Division of Abdominal Transplant Surgery, Department of Surgery, Duke University Medical Center, Durham, N.C.

Received for publication May 28, 2020; accepted June 3, 2020.

Presented at the American Society of Plastic Surgeons (ASPS), The Meeting, October 16–19, 2019 in San Diego, Calif., and at the Annual Mountain West Society of Plastic Surgeons (MWSPS) Meeting, February 27–March 1, 2020, Aspen, Colo.

Copyright © 2020 The Authors. Published by Wolters Kluwer Health, Inc. on behalf of The American Society of Plastic Surgeons. This is an open-access article distributed under the terms of the [Creative Commons Attribution-Non Commercial-No Derivatives License 4.0 \(CCBY-NC-ND\)](https://creativecommons.org/licenses/by-nc-nd/4.0/), where it is permissible to download and share the work provided it is properly cited. The work cannot be changed in any way or used commercially without permission from the journal.

DOI: [10.1097/GOX.0000000000002995](https://doi.org/10.1097/GOX.0000000000002995)

**Disclosure:** The authors have no financial interest to declare in relation to the content of this article.

In 2015–2016, he underwent several failed attempts of fistula takedown and ventral hernia repair by component separation and by the use of a biologic mesh. The patient was diagnosed with short bowel syndrome and a recurrent high-output small-bowel enterocutaneous fistula. During a prior laparotomy, 100 cm or more of native small bowel remained; however, it was considered nonfunctional, given the dense adhesions and partial high-grade obstructions observed throughout the remnant native intestine. He required recurrent hospital admissions for treatment of life-threatening bloodstream infections. In May 2018, the patient was hospitalized for dehydration due to high-output enterocutaneous fistula and was considered for a small-bowel transplantation. Because of extensive scarring and the estimation that 25%–30% of the native AW would be compromised with an additional laparotomy, there was major concern that his native AW would not be sufficient to support an anticipated small-bowel transplant (Fig. 1). The patient was enrolled under an Institutional Review Board (IRB)–approved protocol for abdominal wall transplantation (AWT) in conjunction with a small-bowel transplantation. The procedure was performed on October 12, 2018, after a suitable 13-year-old donor became available. The donor family agreed to donate the AW at the time of the visceral organ recovery. The patient well tolerated the 14-hour

operation. The patient received Thymoglobulin (Genzyme Corp, Cambridge, Mass.) induction (1.5 mg/kg × 4 doses) and maintenance immunosuppression consisting of tacrolimus, mycophenolate mofetil (MMF), and prednisone, which is the standard immunosuppression regimen given to patients who undergo IT at Duke. The patient was extubated on postoperative day 1 and tolerated a regular diet by postoperative day 14. In the third postoperative month, the AWT developed an episode of acute cellular rejection, which responded to 5 days of steroid pulse treatment.

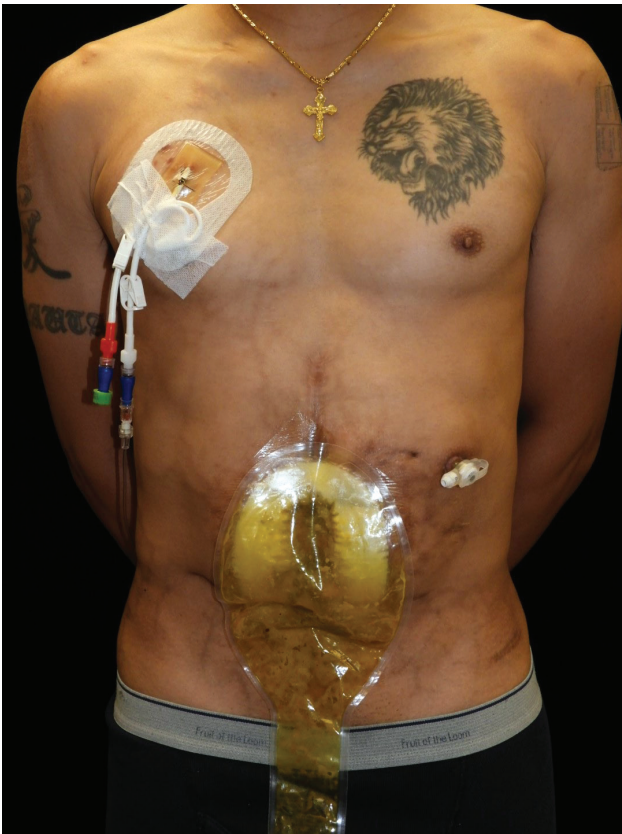#### Operative Details: Creation of Arteriovenous Loop Using Saphenous Vein

During cold ischemia time, an incision was made from the inferior aspect of the abdominal incision to the level of the mid-thigh. The saphenous vein was then transected distally and rotated proximally to allow an end-to-side anastomosis with the common femoral artery (Fig. 2). The arteriovenous loop was then transected and an anastomosis performed in this particular case to the donor iliac artery and vein cuff under 3.5× loupe magnification (Fig. 3). The procedure was performed sequentially bilaterally, and the AW-VCA was then temporarily secured to the thigh until completion of the visceral organ transplant. At that time, the in situ AW inset was performed. The bilateral inferior epigastric vasculature may be used alternatively as described by Cipriani et al,<sup>8</sup> particularly in an adult AW donor where vessels' diameter is suitable.

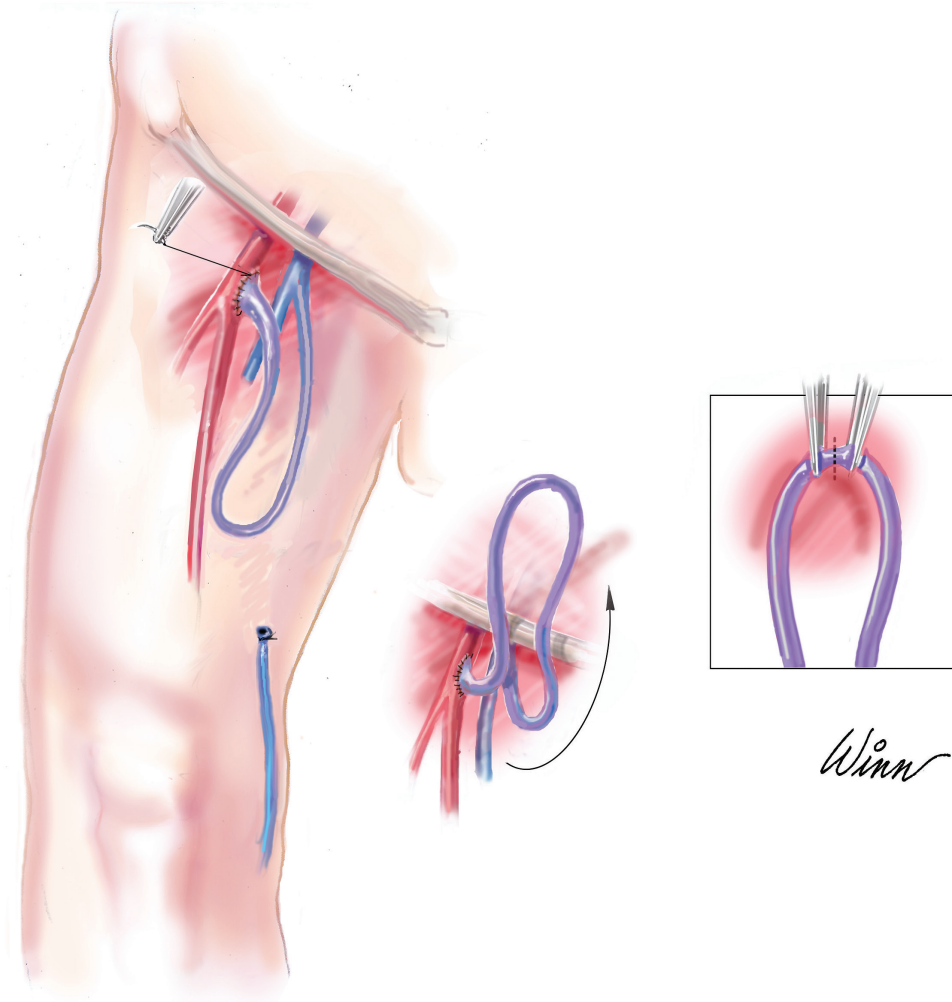
The technique used has several distinct advantages, including minimizing ischemia time of the AW-VCA and decreasing total operative time as synchronous revascularization is performed in situ. In addition, this option improves the ease of anastomosis by providing additional recipient pedicle length and by elimination of further operative interventions associated with forearm banking.<sup>9</sup> Limitations of this technique include additional donor-site morbidity due to bilateral thigh incisions and possible seroma formation at the level of the groin or thigh. The procedure must be modified if the saphenous vein is unavailable.

#### Continued Postoperative Course

In the immediate postoperative setting, the AW-VCA was monitored for rejection and vascular compromise using frequent clinical examination, implantable Doppler probes, and tissue oximetry. After recovery, the patient was scheduled for examinations, including skin biopsies per standard Duke Transplant Surgery protocol, and in the event that he reported any rash or other skin changes of the AW. Standard immunosuppression was continued with tacrolimus (goal trough level, 15–18 ng/ml × 3 months), MMF (1000 mg Q12 hours), and steroid taper per protocol (prednisone 20 mg daily). A standard prophylactic antibiotic and antifungal regimen given to all IT patients at Duke was initiated, which included piperacillin/tazobactam and fluconazole for 2 weeks, followed by clotrimazole for 3 months and trimethoprim/sulfamethoxazole for 1 year. At the same time, IT biopsies were performed to screen for rejection. In addition, the patient underwent scheduled skin biopsies per IRB-approved protocol for AW transplantation that led to an unnecessary



**Fig. 1.** Abdominal wall of the patient following multiple laparotomies, with extensive scarring and multiple recurrent enterocutaneous fistulas. It was determined that the use of conventional methods for soft-tissue closure after intestinal transplant would not be sufficient to provide adequate coverage.



**Fig. 2.** Creation of an arteriovenous loop using the saphenous vein with end-to-side anastomosis with common femoral artery. Figure originally published in the *American Journal of Transplantation*. Reprinted with permission.

amount of clinic visits and insult to the AW skin (scars). Interestingly, there was only 1 questionable episode of mild intestinal rejection (Fig. 4) but multiple episodes of AW-VCA rejection on biopsy (Fig. 5) according to the Banff Classification.<sup>10</sup> The clinical and histologic appearance of an acute Banff III rejection of the AW-VCA skin are shown in Figures 6 and 7. Despite the fact that IT rejection could not be detected in specimens, the AW-VCA rejection was treated with high doses of steroids in addition with Thymoglobulin and Clobetasol Propionate gel (1 event) (Fig. 5). The repeated aggressive immunosuppression treatment for AW rejection likely caused the patient to develop a fungal (*Aspergillus*) brain abscess in June 2019 (Fig. 8A), which temporarily caused headaches and right-sided weakness. The patient is currently being treated with voriconazole 400 mg twice daily. At this time, the current immunosuppression protocol includes tacrolimus (Envarsus XR), 4 mg; MMF, 500 mg twice daily; and prednisone, 12.5 mg daily. His clinical examination has returned to baseline, including a normal neurological

status and no signs of weakness. After initiation of treatment with voriconazole, a follow-up brain MRI examination demonstrated a consolidated abscess formation and, subsequently, resolution of the abscess (Fig. 8B).

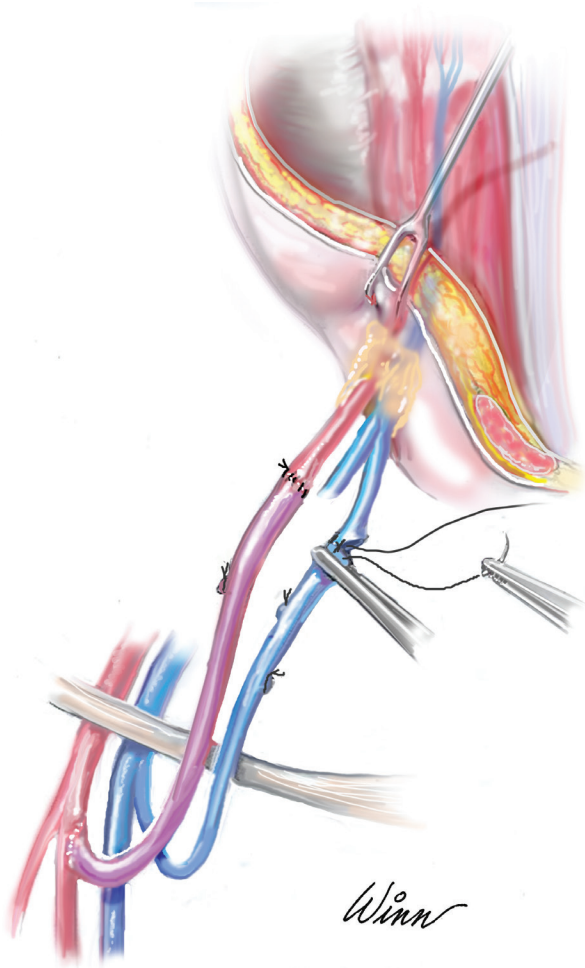
The patient is currently living with his family and pursuing a normal life. His AW transplant has continued to heal well (Fig. 9). He is eating a regular diet with no restrictions. Interestingly, he reports that his preoperative lactose intolerance no longer exists. Despite all setbacks, he reports that he gained a very improved quality of life and is able to pursue activities that he could not perform previously.

### CONSIDERATIONS FOR FUTURE ABDOMINAL WALL TRANSPLANTATION

#### Surgical Technique

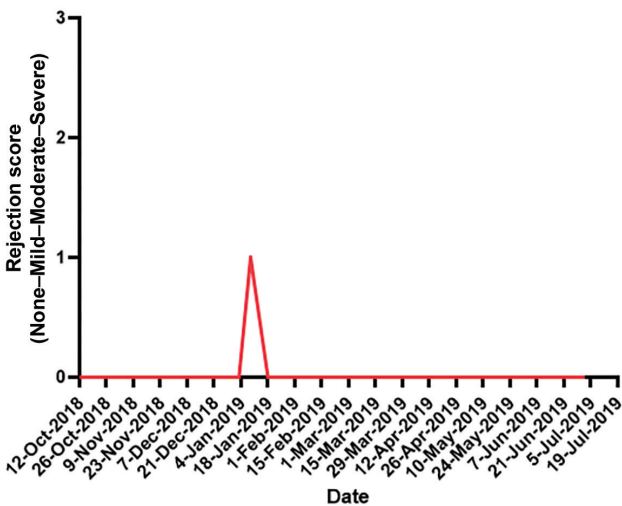
There have been several operative techniques described for AW transplantation involving varying vascular anastomosis and strategies to minimize cold ischemia time. Levi





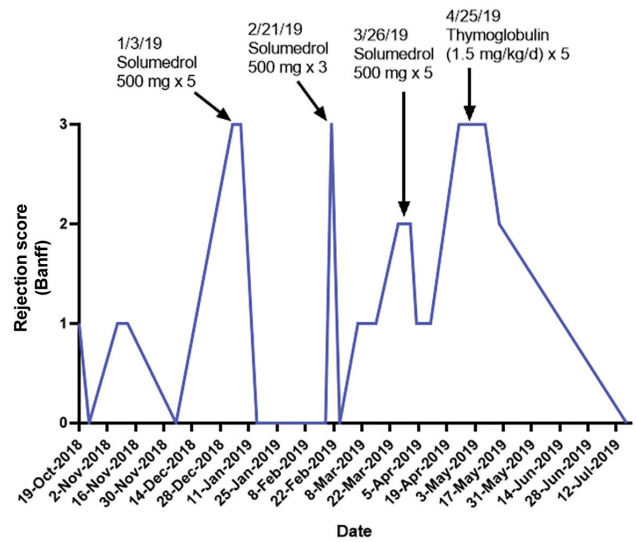
**Fig. 3.** Matured arteriovenous loop is transected and anastomosed end-to-end to the donor inferior epigastric vessels. Figure originally published in the *American Journal of Transplantation*. Reprinted with permission.

**Rejection in intestine biopsies**

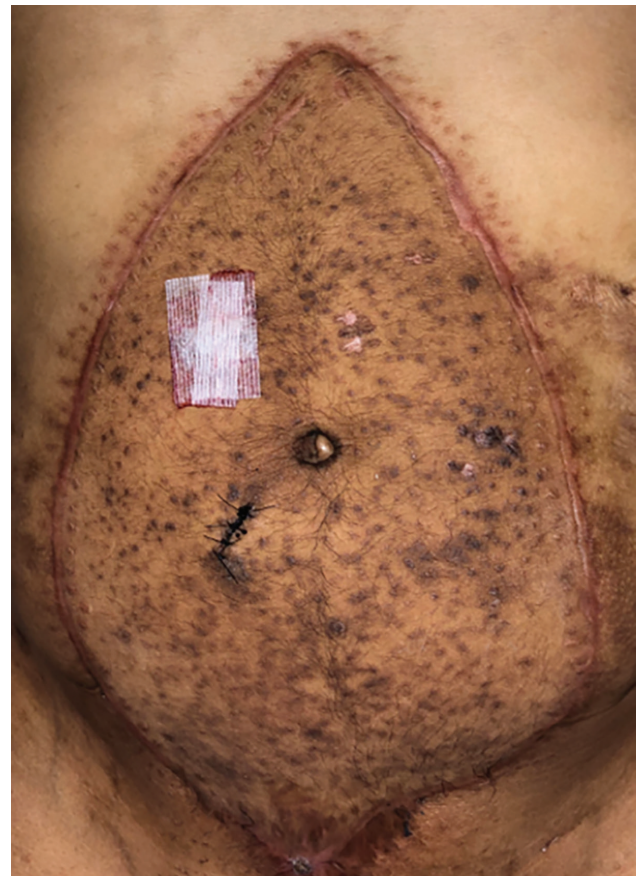

**Fig. 4.** The patient underwent intestinal biopsies bimonthly with only a single mild rejection score that resolved without additional immunotherapy treatment.

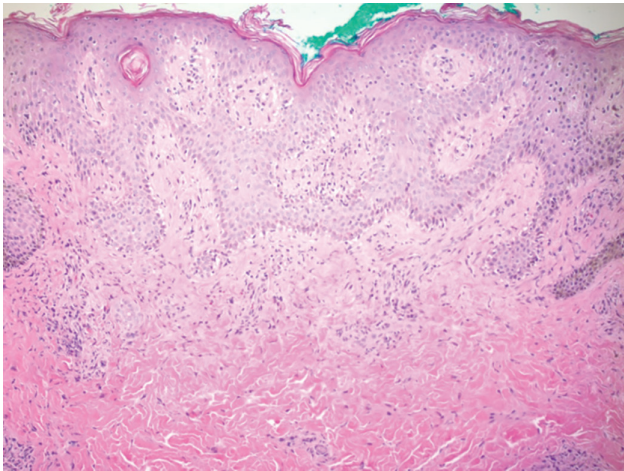
**Rejection in skin biopsies**



**Fig. 5.** Schedule of skin biopsy regimen bimonthly or at any sign of clinical rejection. The patient had 4 episodes of Banff III rejection treated with Solu-Medrol (Pfizer, New York, N.Y.) and Thymoglobulin.



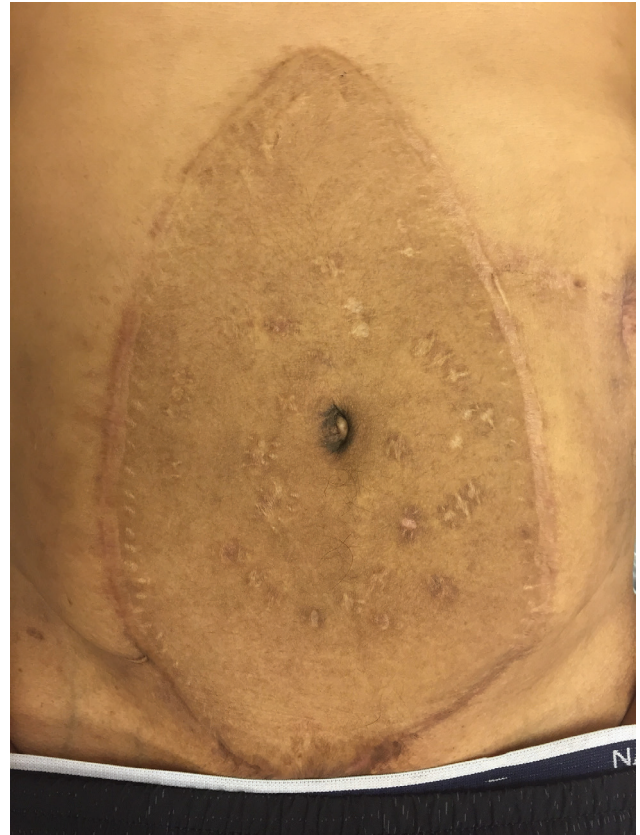**Fig. 6.** Representative findings of abdominal wall allograft during Banff III rejection episode. The abdominal wall demonstrates multiple scars from frequent skin biopsies.



**Fig. 7.** Biopsy of abdominal wall demonstrating severe inflammation and epidermal involvement with epithelial apoptosis, dyskeratosis, and keratinolysis consistent with Banff III rejection.

et al<sup>1</sup> in 2003 were the first to report a procedure with end-to-side anastomosis between donor inferior epigastric artery and common iliac vessels. In 2007, Cipriani et al<sup>8</sup> performed an end-to-end anastomosis between the donor and recipient inferior epigastric vessels, demonstrating that a microsurgical technique with smaller caliber vessels could be successfully used. This technique was then built upon by Giele et al<sup>9</sup> in 2014, which included an additional step of banking the AW graft to the forearm vessels before a secondary anastomosis to the inferior epigastric vascular system to decrease cold ischemia time.

We suggest a variation of the technique described previously in this article, in which a donor vein graft is procured in conjunction with the AW allograft.<sup>6</sup> This donor vein graft will be used to create one or bilateral arteriovenous loops of the common femoral vessels with subsequent transection and end-to-end anastomosis between each donor inferior epigastric artery bilaterally. This approach will decrease morbidity of the recipient without

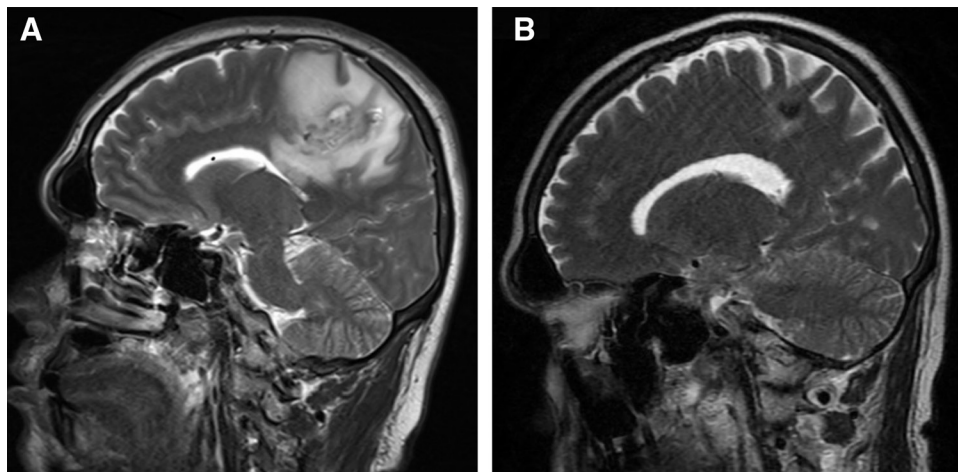


**Fig. 9.** Well healed allograft 10 months postoperatively from abdominal wall transplantation.

the need to use a saphenous vein graft. It will also decrease total operative and cold ischemia time as it allows for synchronous revascularization of AW-VCA with IT/MVT.

#### Biopsy Schedule

The biopsy schedule for research purposes during the postoperative period was conducted in accordance



**Fig. 8.** (A) Magnetic resonance imaging of the brain demonstrates an abscess resulting in headaches and right-sided weakness. (B) The patient is currently being treated with voriconazole therapy with remarkable clinical and radiographic improvement.



with the IRB protocol. In addition, biopsies occurred as clinically indicated for monitoring of rejection and became more necessary than initially anticipated in our patient. The AW graft was therefore subjected to many more biopsies than initially anticipated (Fig. 5). In retrospect, many short-interval biopsies were unnecessary and potentially caused recurrent trauma to the AW graft skin without major histopathologic changes and inferior therapeutic value. Nevertheless, studies have demonstrated that the skin has the greatest antigenicity in VCA and is an ideal diagnostic target for ease of access and early identification of graft rejection.<sup>11</sup> Future combined research and clinical protocols should be “streamlined” and will have less frequent biopsies of the skin (and intestines).

### Prevention of AW-VCA Chronic Rejection

The standard Duke immunosuppression protocol for IT does *not* include Alemtuzunab (Campath). The Oxford working group reported outcomes regarding immunosuppression in the largest cohort of AW-VCA. This protocol includes Alemtuzunab as induction therapy with tacrolimus as maintenance therapy. The outcome of the study demonstrated a 36% rate of rejection. Their rejection monitoring protocol included endoscopy multiple times a week for six months, followed by bimonthly monitoring. There were no scheduled skin biopsies; however, biopsies were taken if a change was noted on clinical examination. This regimen may be an alternative immunosuppression protocol that could be considered in future AW-VCA transplantation at the Duke University Medical Center.<sup>12</sup>

### Excision of AW-VCA Skin

As the AW-VCA heals and IT edema resolves during the postoperative course, AW skin redundancy is noted. Therefore, excision of redundant skin along the periphery of the AW-VCA may be considered. Given that skin is the most antigenic component of VCA, excision of excess skin may theoretically decrease the antigenic load associated with AW-VCA, while improving the AW appearance. The central skin component should remain, which continues to allow for noninvasive monitoring (clinical examination).

### Neurotization of AW-VCA

The usefulness and feasibility of neurotization in AWT have been debated. Although there have been no reported cases of neurotization in AW-VCA, Broyles et al<sup>13</sup> performed a cadaveric study to determine the feasibility of neurotization in AWT. The authors were able to identify thoracolumbar nerves during their study and determined that the nerves were of adequate length and caliber to perform coaptation. However, several clinical barriers remain to neurotization in AW-VCA, including extensive scarring of the recipient AW leading to difficulty identifying nerves, as well as concerns regarding prolonging operative time. Although these obstacles exist, we may attempt neurotization at the time of future transplantations if operative factors permit.

## CONCLUSIONS

The field of vascularized composite allotransplantation continues to grow with improvements in immunotherapy and operative technique. We must continue to critically review surgical techniques, postoperative management, and outcomes to improve long-term patient results.

*Detlev Erdmann, MD, PhD, MHSc*

Division of Plastic, Maxillofacial, and Oral Surgery

Department of Surgery

Duke University Medical Center

Box 3191, Durham, NC 27710

E-mail: detlev.erdmann@duke.edu

## ACKNOWLEDGMENTS

The authors thank Bill Winn for the illustrations used in this article. This study was conducted in accordance with the Duke University Institutional Review Board (IRB) approved protocol (No. 00084054).

## PATIENT CONSENT

The patient provided written consent for the use of his image.

## REFERENCES

1. Levi DM, Tzakis AG, Kato T, et al. Transplantation of the abdominal wall. *Lancet*. 2003;361:2173–2176.
2. Light D, Kundu N, Djohan R, et al. Total abdominal wall transplantation: an anatomical study and classification system. *Plast Reconstr Surg*. 2017;139:1466–1473.
3. Giele H, Vaidya A, Reddy S, et al. Current state of abdominal wall transplantation. *Curr Opin Organ Transplant*. 2016;21:159–164.
4. Carlsen BT, Farmer DG, Busuttill RW, et al. Incidence and management of abdominal wall defects after intestinal and multivisceral transplantation. *Plast Reconstr Surg*. 2007;119:1247–1255; discussion 1256.
5. Alexandrides IJ, Liu P, Marshall DM, et al. Abdominal wall closure after intestinal transplantation. *Plast Reconstr Surg*. 2000;106:805–812.
6. Atia A, Hollins A, Shammas RL, et al. Surgical techniques for revascularization in abdominal wall transplantation. *J Reconstr Microsurg*. 2020 [Epub ahead of print].
7. Erdmann D, Atia A, Phillips BT, et al. Small bowel and abdominal wall transplantation: a novel technique for synchronous revascularization. *Am J Transplant*. 2019;19:2122–2126.
8. Cipriani R, Contedini F, Santoli M, et al. Abdominal wall transplantation with microsurgical technique. *Am J Transplant*. 2007;7:1304–1307.
9. Giele H, Bendon C, Reddy S, et al. Remote revascularization of abdominal wall transplants using the forearm. *Am J Transplant*. 2014;14:1410–1416.
10. Cendales LC, Kanitakis J, Schneeberger S, et al. The Banff 2007 working classification of skin-containing composite tissue allograft pathology. *Am J Transplant*. 2008;8:1396–1400.
11. Jones ND, Turvey SE, Van Maurik A, et al. Differential susceptibility of heart, skin, and islet allografts to T cell-mediated rejection. *J Immunol*. 2001;166:2824–2830.
12. Gerlach UA, Vrakas G, Sawitzki B, et al. Abdominal wall transplantation: skin as a sentinel marker for rejection. *Am J Transplant*. 2016;16:1892–1900.
13. Broyles JM, Berli J, Tuffaha SH, et al. Functional abdominal wall reconstruction using an innervated abdominal wall vascularized composite tissue allograft: a cadaveric study and review of the literature. *J Reconstr Microsurg*. 2015;31:39–44.