


# Extensive Synovial Chondromatosis Involving All Flexor Tendons in the Tarsal Tunnel: A Case Report\*

## *Condromatose sinovial extensa envolvendo todos os tendões do túnel do tarso: relato de caso*

Zachariah Pinter<sup>1</sup> Ashish Shah<sup>1</sup> Cesar de Cesar Netto<sup>1</sup> Walter Smith<sup>1</sup> Andres O'Daly<sup>1</sup>  
Alexandre Leme Godoy-Santos<sup>2</sup> 

<sup>1</sup> Division of Orthopaedic Surgery, Department of Surgery, University of Alabama, Birmingham, Alabama, United States

<sup>2</sup> Faculty of Medicine, Department of Orthopedics, Universidade de São Paulo, São Paulo, SP, Brazil

Address for correspondence Alexandre Leme Godoy-Santos, Faculdade de Medicina, Departamento de Ortopedia, Universidade de São Paulo, São Paulo, SP 03178-200, Brazil (e-mail: alexandrelemegodoy@gmail.com).

Rev Bras Ortop 2019;54:78–82.

### Abstract

#### Keywords


- ▶ synovial chondromatosis/ diagnostic imaging
- ▶ synovial chondromatosis/ surgery
- ▶ synovial chondromatosis/ diagnosis
- ▶ synovial chondromatosis/ pathology
- ▶ synovitis

Synovial chondromatosis is a rare condition characterized by benign chondrogenic metaplasia of extra-articular synovial tissue. It usually affects a single tendon sheath of the hand or foot. This report describes a rare case with extensive synovial chondromatosis affecting all flexor tendons in the tarsal tunnel, its radiological features, surgical treatment, and clinical outcome. The authors present a unique case of extensive synovial chondromatosis in a 48-year-old male involving the tendon sheaths of the flexor hallucis longus, flexor digitorum longus, and posterior tibialis tendons, at the level of the tarsal tunnel, with extension into the plantar aspect of the foot. The patient initially presented with symptoms of tarsal tunnel compression and was found to have a 4-cm mass in the posteromedial aspect of the ankle. The presumptive diagnosis of synovial chondromatosis was made based on radiographic and magnetic resonance imaging evidence. The patient underwent surgical resection of the tumor, as well as tarsal tunnel release and gastrocnemius recession. The diagnosis was confirmed postoperatively by surgical histopathology. The postoperative course of the patient was uncomplicated and his tarsal tunnel symptoms resolved. This represents a case of extensive synovial chondromatosis involving all flexor tendons in the tarsal tunnel that was correctly diagnosed by clinical and imaging findings, which required early surgical resection to avoid long-term neurovascular complications.

### Resumo

A condromatose sinovial é uma condição rara caracterizada por metaplasia condrogênica benigna do tecido sinovial extra-articular, que geralmente afeta uma única

\* Study conducted at Division of Orthopaedic Surgery, Department of Surgery, University of Alabama at Birmingham (UAB), Birmingham, United States. Published by Elsevier Editora Ltda. © 2018 Sociedade Brasileira de Ortopedia e Traumatologia.

 Alexandre Leme Godoy-Santos's ORCID: is <https://orcid.org/0000-0002-6672-1869>.

received  
July 1, 2017  
accepted  
July 13, 2017

DOI <https://doi.org/10.1016/j.rboe.2017.07.012>.  
ISSN 0102-3616.

Copyright © 2019 by Sociedade Brasileira de Ortopedia e Traumatologia. Published by Thieme Revinter Publicações Ltda, Rio de Janeiro, Brazil

License terms



**Palavras-chave**

- ▶ crondomatose sinovial/diagnóstico por imagem
- ▶ crondomatose sinovial/cirurgia
- ▶ crondomatose sinovial/diagnóstico
- ▶ crondomatose sinovial/patologia
- ▶ sinovite

bainha tendínea da mão ou do pé. O objetivo é relatar o caso raro de um paciente com diagnóstico de condromatose sinovial extensa afetando todos os tendões flexores na topografia do túnel do tarso, suas características radiológicas, tratamento cirúrgico e desfecho clínico. Os autores apresentam um caso único de condromatose sinovial extensa em um homem de 48 anos envolvendo as bainhas dos tendões flexor longo do hálux, flexor longo dos dedos e tibial posterior, na topografia do túnel do tarso, com extensão para a região plantar do retropé. O sintoma inicial foi de compressão neurovascular (síndrome do túnel do tarso). A suspeita diagnóstica foi condromatose sinovial com base em evidências radiográficas e de ressonância magnética. O paciente foi submetido a ressecção cirúrgica do tumor, bem como a liberação do túnel tarsal e alongamento do tendão dos gastrocnêmios. O diagnóstico foi confirmado por exame histopatológico do espécime colhido no período intraoperatório. A evolução pós-operatória do paciente ocorreu sem complicações e os sintomas da síndrome do túnel do tarso cessaram. Os autores relatam um caso de condromatose sinovial extensa envolvendo todos os tendões flexores do túnel do tarso, corretamente diagnosticado por achados clínicos e radiológicos e que necessitou de ressecção cirúrgica precoce para evitar complicações neurovasculares em longo prazo.

**Introduction**

Synovial chondromatosis is a rare condition characterized by benign chondrogenic metaplasia of extra-articular synovial tissue.<sup>1</sup> Transformation of the synovium leads to the formation of cartilage bodies that may reside within the synovium itself or become free-floating within the tendon sheath. The disease is most frequently reported in individuals in their third to fifth decades of life, with a slight predilection for males.<sup>2</sup>

Synovial chondromatosis is typically a localized disease, affecting a single tendon sheath of the hand or foot. Invasion of multiple adjacent structures has been previously reported, but it is exceedingly rare.<sup>3</sup> The presence of a palpable mass is often the presenting initial complaint since this condition generally presents without pain or restricted range of motion. The cartilage bodies normally ossify, resulting in an obvious radiographic appearance. In cases where they do not ossify, magnetic resonance imaging (MRI) or computed tomography (CT) scans can help in the diagnosis.<sup>2</sup>

We present a case of extensive synovial chondromatosis of the flexor hallucis longus (FHL), flexor digitorum longus (FDL), posterior tibialis (PT), and plantar tarsal region in a 48-year-old male.

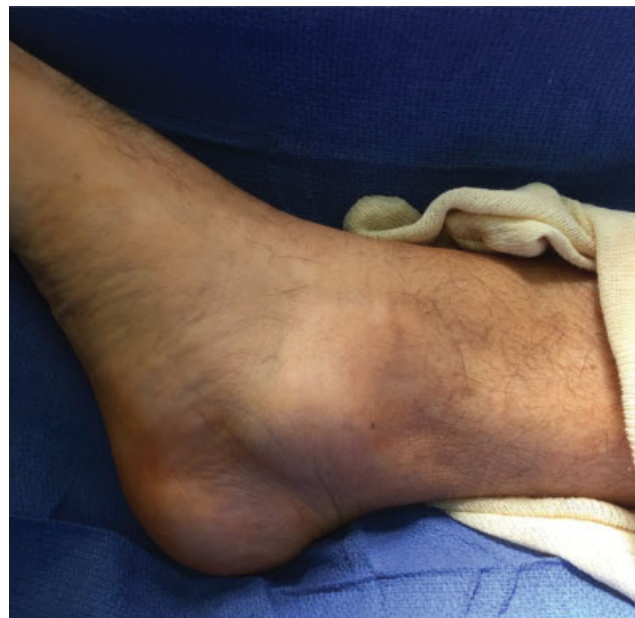**Objectives**

To report a rare case of a patient with extensive synovial chondromatosis affecting all flexor tendons in the tarsal tunnel, its radiological features, surgical treatment and clinical outcome.

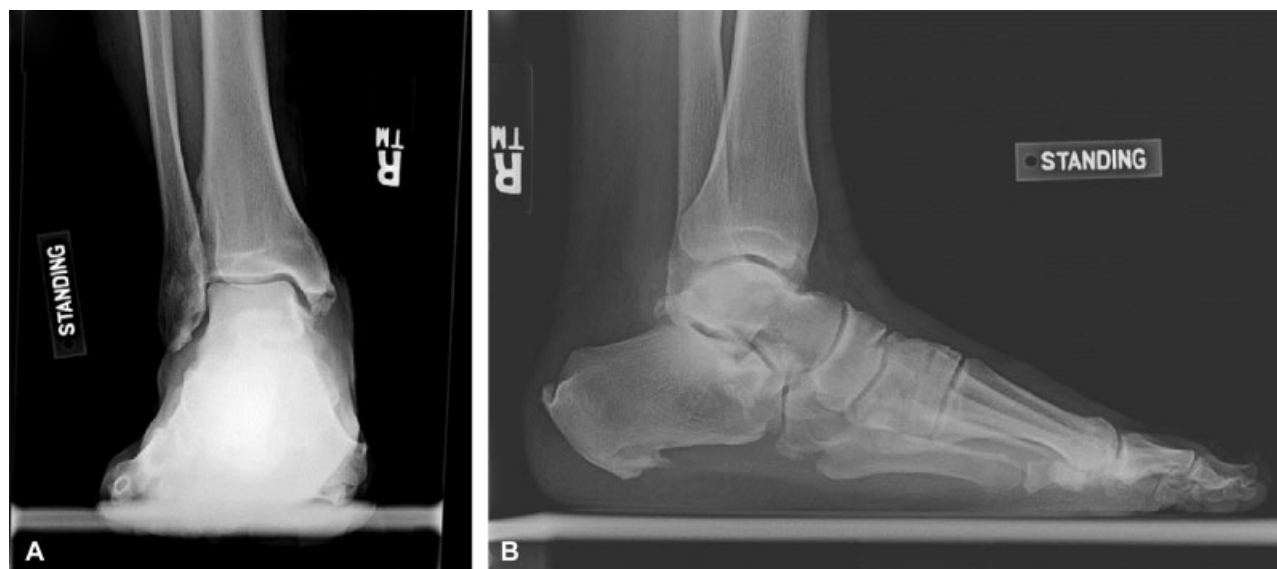**Case Report**

A 48-year-old male presented with six to eight weeks of plantar heel pain involving the right foot. On initial inspection, the skin overlying the right foot and ankle was intact with

minimal swelling, and a 4 cm posteromedial mass with irregular borders was noted in the ankle (▶ Fig. 1). The patient indicated that this mass had been slowly enlarging for the past six years. Further examination revealed decreased sensation over the medial heel and plantar aspect of the foot, tenderness plantarly in the insertion of the plantar fascia, and a positive Tinel Sign over the tarsal tunnel. Ankle and subtalar range of motion were within normal limits. Radiographs of the right foot and ankle showed plantar osteophytes and a Haglund's lesion, but no calcification was evident within the mass (▶ Fig. 2). T2 MRI demonstrated a 4 cm irregular mass compressing the neurovascular bundle. There was extensive involvement of the FDL, FHL, and PT tendon sheaths in the posteromedial ankle with extension through the plantar tarsal



**Fig. 1** Large irregular mass visible over posterior medial maleolus.



**Fig. 2** (A) Standing anteroposterior; (B) lateral radiographs of right ankle demonstrating no evidence of calcification within the mass.

region (► **Fig. 3**). At the time of diagnosis, the patient opted for conservative treatment with a boot, NSAIDs, and physical therapy. However, the patient returned for follow-up 10 weeks later complaining of the same symptoms.

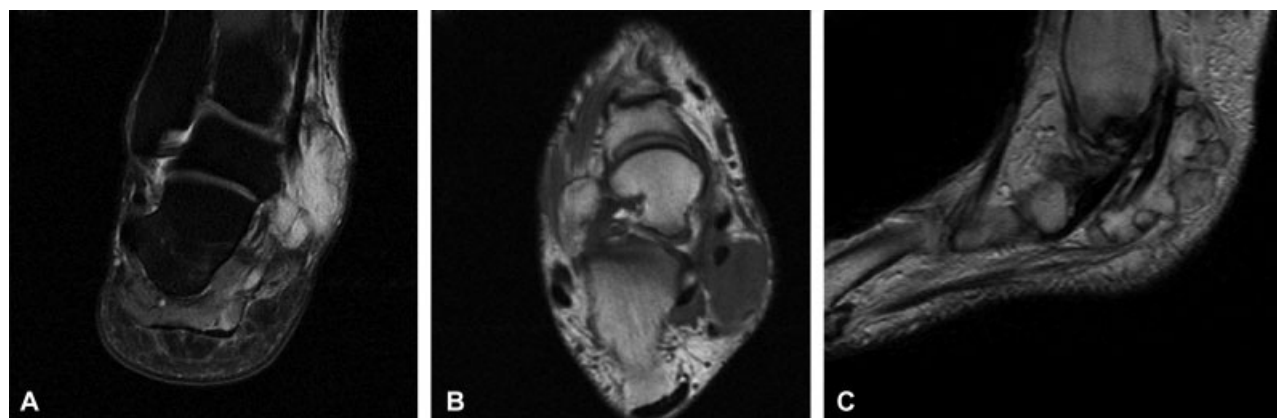
After exhausting conservative management options, the patient underwent surgical excision of the tumor. Intraoperatively, the mass was found to involve the tendon sheath covering the FHL, FDL and PT tendons (► **Fig. 4**). Tarsal tunnel release and gastrocnemius recession were also performed. Histopathological evaluation of the mass demonstrated clusters of clonal chondrocytes arranged in lobules, with variable atypia and occasional binucleation, confirming the diagnosis of synovial chondromatosis (► **Fig. 5**). The patient's postoperative course was uncomplicated. By his 8-week postoperative clinic visit, the patient's pain and tarsal tunnel symptoms had completely resolved.

We have informed the patient that the data concerning this case would be submitted for publication, and they have consented it (IRB approval 6/29/2016 under number X160503004).

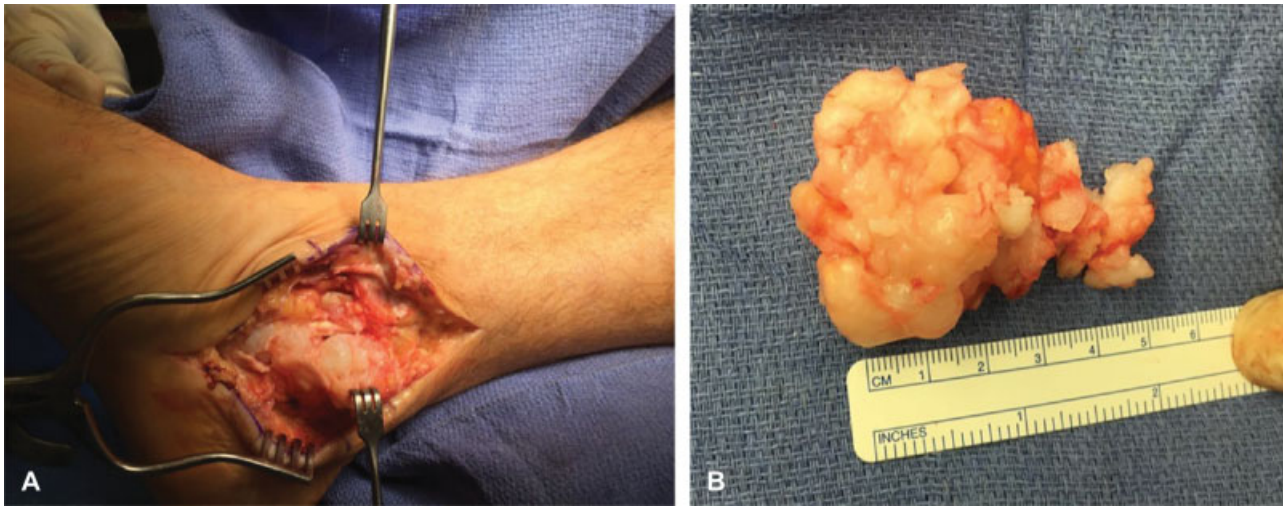
## Discussion

Synovial chondromatosis is a rare condition,<sup>1</sup> typically found as an isolated lesion affecting a single tendon sheath in the hand or foot. It is exceedingly rare for the disease to have multifocal involvement and be located in the ankle region. Radiographs show a soft tissue mass and calcifications 90% of time, while CT demonstrates calcification in 100% of tenosynovial chondromatosis.<sup>2</sup> MRI is especially useful in diagnosis as well, as it is able to reveal intrinsic characteristics of chondroid tissue and provide further insight into the precise locations of lesions.

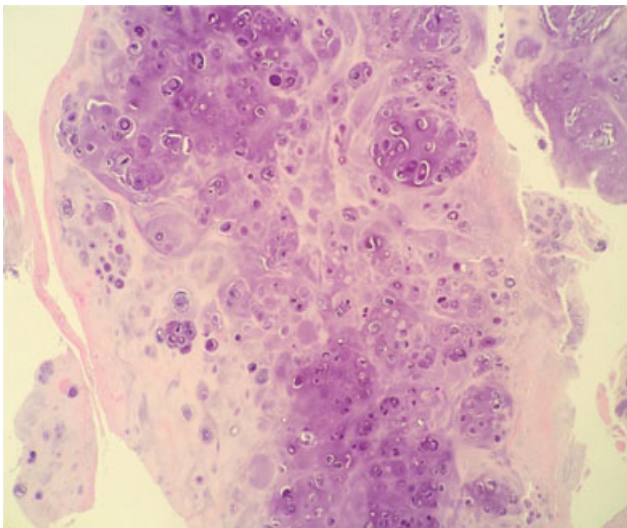
The differential diagnosis for synovial chondromatosis is dependent upon the aforementioned imaging modalities used to assess the condition. A radiograph revealing ossified loose bodies and bizarre parosteal osteochondromatous proliferation should raise concern for giant cell tumor of the ankle, chondrosarcoma, or synovial sarcoma. Conversely, if radiographs do not show ossified loose bodies but reveal soft-tissue distension of a tendon sheath, then differential



**Fig. 3** (A) Coronal T2 MRI image of the right ankle showing high intensity signal representing posteromedial mass; (B) axial T1 MRI image of the right ankle showing low intensity signal of mass with involvement of the flexor hallucis longus, flexor digitorum longus, and posterior tibialis tendon; (C) sagittal T1 MRI image of the right ankle showing posteromedial involvement with extension into the plantar tarsal region.



**Fig. 4** (A) Intra-operative image demonstrating extensive tendon involvement of mass; (B) gross pathologic specimen.



**Fig. 5** Transverse histological sections of the synovial chondromatosis specimen showing clusters of chondrocytes and varying degrees of atypia.

considerations should include tenosynovitis, tenosynovial chondromatosis, and tenosynovial giant cell tumor. MRI allows for enhanced soft-tissue detail and aids in precise localization of lesions in relation to the tendon sheath. A fluid-distended tendon sheath filled with innumerable small loose bodies on MRI should lead to the consideration of synovial chondromatosis, juvenile idiopathic arthritis (JIA), or rheumatoid arthritis (RA), which commonly presents with rice bodies. Intravenous gadolinium can be useful in discerning inflammatory changes, as seen in JIA or infection. In our case, MRI showed an irregular mass involving the tendon sheath of the FHL, FDL, and PT which extended through the plantar tarsal region. Taking into account radiographic and MRI results, the diagnosis in this case was determined to be tenosynovial chondromatosis.

To our knowledge, there have only been four previously reported cases of synovial chondromatosis involving the FHL

tendon sheath,<sup>4-7</sup> and only 1 of these cases involved the triad of the FHL, FDL, and tarsal tunnel.<sup>4</sup> In the case in which the FHL, FDL, and tarsal tunnel were all affected, a 23-year-old man experienced occasional pain at the site for 13 years.<sup>4</sup> His initial diagnosis was made based upon multiple ossified bodies seen on radiographs.

In our case, the extensive involvement of the FHL, FDL, PT, and tarsal tunnel combined with the large size of the tumor demonstrate the extensive growth that can occur before the patient becomes symptomatic. Even when the tumor does reach a critically large size, associated symptoms are typically minor. Tenderness is not uncommon but restriction of ankle motion is generally not observed. As a result, it is critical that physicians become familiar with the relatively indolent presentation of this condition and the wide variety of imaging findings that may be present. Surgical resection is the mainstay therapy; however, tenosynovial chondromatosis has a high recurrence rate. Therefore, close follow-up is critical after surgical treatment.

We report a case of extensive synovial chondromatosis involving all flexor tendons in the tarsal tunnel that was correctly diagnosed by clinical and imaging findings and required early surgical resection to avoid long-term neurovascular complications.

#### Conflicts of Interest

The authors declare no conflicts of interest.

#### References

- 1 Lasmar NP, Vieira RB, Rosa JO, Lasmar RCP, Scarpa AC. SYNOVIAL CHONDROMATOSIS. *Rev Bras Ortop* 2010;45(5):490-2
- 2 Walker EA, Murphey MD, Fetsch JF. Imaging characteristics of tenosynovial and bursal chondromatosis. *Skeletal Radiol* 2011;40(3):317-25
- 3 Fetsch JF, Vinh TN, Remotti F, Walker EA, Murphey MD, Sweet DE. Tenosynovial (extraarticular) chondromatosis: an analysis of 37 cases of an underrecognized clinicopathologic entity with a strong predilection for the hands and feet and a high local recurrence rate. *Am J Surg Pathol* 2003;27(9):1260-8

- 4 Sugimoto K, Iwai M, Kawate K, Yajima H, Takakura Y. Tenosynovial osteochondromatosis of the tarsal tunnel. *Skeletal Radiol* 2003; 32(2):99-102
- 5 Lui TH. Tenosynovial osteochondromatosis of the flexor hallucis longus tendon treated by tendoscopy. *J Foot Ankle Surg* 2015; 54(4):758-64
- 6 Thomsen TW, Hogrefe CP, Hall MM, Amendola A. Tenosynovial osteochondromatosis of the flexor hallucis longus in a division I tennis player. *Clin J Sport Med* 2015;25(6):e74-6
- 7 Winters NI, Thomson AB, Flores RR, Jordanov MI. Tenosynovial chondromatosis of the flexor hallucis longus in a 17-year-old girl. *Pediatr Radiol* 2015;45(12):1874-7