ARTICLE IN PRESS

Seminars in Spine Surgery xxx (xxxx) xxx

Contents lists available at ScienceDirect

Seminars in Spine Surgery

journal homepage: www.elsevier.com/locate/semss

Evolving concepts in pelvic fixation in adult spinal deformity surgery

Jay D. Turner[a,*], Alexander J. Schupper[b], Praveen V. Mummaneni[c], Juan S. Uribe[a], Robert K. Eastlack[d,e], Gregory M. Mundis Jr.[d,e], Peter G. Passias[f], Joseph D. DiDomenico[a], S. Harrison Farber[a], Mohammed A.R. Soliman[g,h], Christopher I. Shaffrey[i], Eric O. Klineberg[j], Alan H. Daniels[k], Thomas J. Buell[l], Douglas C. Burton[m], Jeffrey L. Gum[n], Lawrence G. Lenke[o], Shay Bess[p], Jeffrey P. Mullin[g,†]

[a] Department of Neurosurgery, Barrow Neurological Institute, St. Joseph's Hospital and Medical Center, Phoenix, AZ
[b] Department of Neurosurgery, Mount Sinai, New York, NY
[c] Department of Neurosurgery, University of California San Francisco, San Francisco, CA
[d] Department of Orthopedics, Scripps Clinic, San Diego, CA
[e] San Diego Spine Foundation, San Diego, CA
[f] Department of Orthopedic Surgery, NYU Grossman School of Medicine, New York, NY
[g] Department of Neurosurgery, University of Buffalo, Buffalo, NY
[h] Department of Neurosurgery, Cairo University, Cairo, Egypt
[i] Department of Neurosurgery, Duke University, Durham, NC
[j] Department of Orthopedics, University of Texas, Houston, TX
[k] Department of Orthopedics, Brown University, Providence, RI
[l] Department of Neurosurgery, University of Pittsburgh, Pittsburgh, PA
[m] Department of Orthopedics, University of Kansas, Lawrence, KS
[n] Department of Orthopedics, University of Louisville, Louisville, KY
[o] Department of Orthopedic Surgery, Columbia University, New York, NY
[p] Denver International Spine Center, Rocky Mountain Hospital for Children, Presbyterian/St. Luke's Medical Center, Denver, CO

ARTICLE INFO

Keywords:
Complex adult deformity surgery
Distal fixation
International Spine Study Group
Junction
Lumbosacral fixation
Sacroiliac fusion
Sacroiliac joint
Trajectory

ABSTRACT

Long-segment adult spinal deformity (ASD) constructs carry a high risk of mechanical complications. Pelvic fixation was introduced to improve distal construct mechanics and has since become the standard for long constructs spanning the lumbosacral junction. Pelvic fixation strategies have evolved substantially over the years. Numerous techniques now use a variety of entry points, screw trajectories, and construct configurations. We review the various strategies for pelvic fixation in ASD in a systematic review of the literature and update the techniques employed in the International Spine Study Group Complex Adult Deformity Surgery database.

1. Introduction

Adult spinal deformity (ASD) is a common condition with increasing prevalence in our aging population.[1,2] ASD has a large clinical impact, and patients whose conditions fail to improve with nonoperative management often benefit from surgical correction.[3,4] Surgery for ASD has a high associated rate of morbidity, with two-year complication rates as high as 58.7 %.[5-8] Mechanical complications, including pseudarthrosis and instrumentation failure, are common and negatively impact clinical outcomes.[7,9]

Distal fixation is particularly vulnerable to failure when spanning the lumbosacral junction. Deformity constructs terminating in the sacrum are associated with very high complication rates, including high rates of pseudarthrosis (42 %) and revision surgery (58 %), with a total

Abbreviations: ASD, adult spinal deformity; CADS, complex adult deformity surgery; ISSG, International Spine Study Group; S2AI, S2-alar-iliac; SI, sacroiliac.

* Corresponding author at: c/o Neuroscience Publications, Barrow Neurological Institute, St. Joseph's Hospital and Medical Center, 350 W Thomas Rd; Phoenix, AZ 85013.

E-mail address: Neuropub@barrowneuro.org (J.D. Turner).

† International Spine Study Group.

https://doi.org/10.1016/j.semss.2023.101060

Available online 27 September 2023

Please cite this article as: Jay D. Turner et al., *Seminars in Spine Surgery* , https://doi.org/10.1016/j.semss.2023.101060

complication rate approaching 75 %.[10] The long lever arm in deformity constructs often overpowers suboptimal sacral fixation, which typically travels through a primarily cancellous channel of lower-density bone. Iliac screw fixation provides a significant biomechanical advantage by allowing for the placement of longer screws that extend anterior to the lumbosacral pivot point and terminate in the higher-density bone near the greater sciatic notch.[11] Iliac fixation has been demonstrated to restrict the range of motion across the lumbosacral junction and reduce sacral screw strain.[12-14] Iliac screw augmentation is associated with lower rates of lumbosacral pseudarthrosis and may also protect against sagittal plane decompensation—two important determinants of clinical outcomes following ASD surgery.[15,16]

Though pelvic fixation is superior to sacral instrumentation, it is still vulnerable to failure.[9,17,18] Pelvic fixation strategies have evolved substantially over time to improve the construct's durability and clinical outcomes. Numerous techniques are available using different entry points, screw trajectories, materials, and surface technologies.[18] Multipoint pelvic fixation has also grown in popularity, reducing the rate of distal failure. The current study summarizes modern pelvic fixation strategies in ASD through a systematic review of the current literature and a query of techniques employed in the International Spine Study Group (ISSG) Complex Adult Deformity Surgery (CADS) database.

2. Methods

2.1. Systematic review

A systematic review was performed to identify articles on pelvic fixation techniques for ASD. The search terms used were ["pelvic fixation"] AND ["adult spinal deformity"]. The search was conducted in electronic databases using the appropriate medical subject headings (MeSH) and Boolean terms. The electronic databases queried included PubMed, Ovid MEDLINE, and Scopus. These databases were searched for relevant studies published between January 1, 1900, through May 7, 2023.

Study eligibility screening was performed using Covidence (Melbourne, Australia). Titles and abstracts were screened for relevance to pelvic fixation strategies in ASD. Studies were initially included if they were clinical or cadaveric articles in English or translated to English and had full-text articles available for the screener. Studies were excluded from enrollment if not published during the above date period, animal or basic science studies, or the article's primary focus was outside the scope of pelvic fixation for ASD. Articles that were included following initial screening proceeded to full-text screening, where the reviewer assessed the full manuscript. Studies were excluded if the manuscript was unpublished, included conference abstracts without the full text, and contained textbook chapters, pediatric cases (age < 18 years), technical notes, or case reports. The same independent reviewer (A.S.) screened titles and abstracts as well as the full-text articles identified in each database. Duplicate articles were removed. Studies that met inclusion criteria following full-text review were included in the final analysis.

2.2. ISSG CADS database

We systematically reviewed pelvic fixation techniques reported in the ISSG CADS database. CADS is a clinical trial that evaluates the surgical outcomes of patients undergoing surgery for ASD to identify best practice guidelines to improve patient outcomes and minimize surgical complications. For the current study, data on various pelvic fixation types were collected, and the relative frequency of usage in ASD cases was analyzed. Trends over time for the various pelvic fixation techniques were examined, including the use of single versus multipoint pelvic fixation.

3. Results

3.1. Systematic review

Searching the PubMed, Ovid MEDLINE, and Scopus databases yielded 711 studies (336 from PubMed, 62 from Ovid MEDLINE, and 313 from Scopus). Of these, 278 duplicate articles were removed, resulting in 433 studies for initial screening. Of these, 341 articles did not meet the inclusion criteria, leaving 92 studies that underwent full-text review. Twenty of these studies did not meet the setting, patient population, or study design criteria, resulting in 72 studies being included. Eight (11.0 %) studies were systematic reviews, and seven (9.6 %) were cadaveric. In the 58 clinical studies, 5009 patients were included.

All clinical studies focused on various types of pelvic fixation. Twelve (20.7 %) studies focused on complications, specifically pseudarthrosis and instrumentation failure. The top journals publishing these articles were *Spine* (18.1 %), the *European Spine Journal* (18.1 %), and the *Global Spine Journal* (5.6 %). The pelvic fixation techniques described included 1) S2-alar-iliac (S2AI) screw fixation, 2) S1-alar-iliac screw fixation, 3) S3-alar-iliac screw fixation, 4) iliac screw fixation, 5) dual iliac screw fixation, and 6) triangular sacroiliac joint fusion implantation. Rod constructs included multiple accessory rod constructs and kickstand rod constructs. Technological adjuncts included navigation-guided and robotic-guided placement of pelvic fixation constructs.

3.2. ISSG CADS database

The ISSG CADS database was queried, and 442 cases of patients with ASD were identified. Fourteen unique pelvic instrumentation configurations were recorded (Table 1). Pelvic fixation methods were recorded between 2019 and 2022. Of 442 constructs, 219 (49.5%) used bilateral single S2AI screws (first description in Table 1), followed by 96 (21.7 %) that used bilateral single traditional iliac screws. Single versus multipoint fixation was recorded for all pelvic fixation cases. Various multipoint pelvic fixation configurations are identified and summarized in Fig. 1. The temporal trend in single point versus multipoint pelvic fixation in the ISSG CADS database is shown in Fig. 2. In 2019, 65 (89.0 %) cases used single-point fixation versus 8 cases (11.0 %) using multipoint, compared to 2022, where 79 (58.5 %) cases used single point, compared to 56 (41.5 %) cases using multipoint fixation techniques.

4. Discussion

Robust sacropelvic fixation is necessary to achieve good clinical

Table 1
Various pelvic screw configuration strategies for patients enrolled in ISSG CADS study. Configuration strategies span single-point unilateral pelvic fixation to different types of dual bilateral fixation.

Pelvic Screw Configuration	Pelvic Fixation Points
S2AI (1 screw), unilateral	1
Traditional iliac (1 screw), unilateral	1
S2AI (1 screw), bilateral	2
Traditional iliac (1 screw), bilateral	2
Traditional iliac approach (2 screws), unilateral	2
Traditional iliac (1 screw), unilateral + S2AI (1 screw), unilateral	2
S2AI (2 screws), unilateral + S2AI (1 screw), unilateral	3
S2AI (2 screws), bilateral	4
Traditional iliac approach (2 screws), bilateral	4
S2AI (1 screw) + porous triangular implant, bilateral	4
S2AI (2 screws), unilateral + traditional iliac (2 screws), unilateral	4
S2AI (1 screw) + traditional iliac (1 screw), bilateral	4
S2AI (1 screw) + freestanding threaded porous Ti, bilateral	4
S2AI (1 screw) + porous Ti screw with rod connection (1 screw), bilateral	4

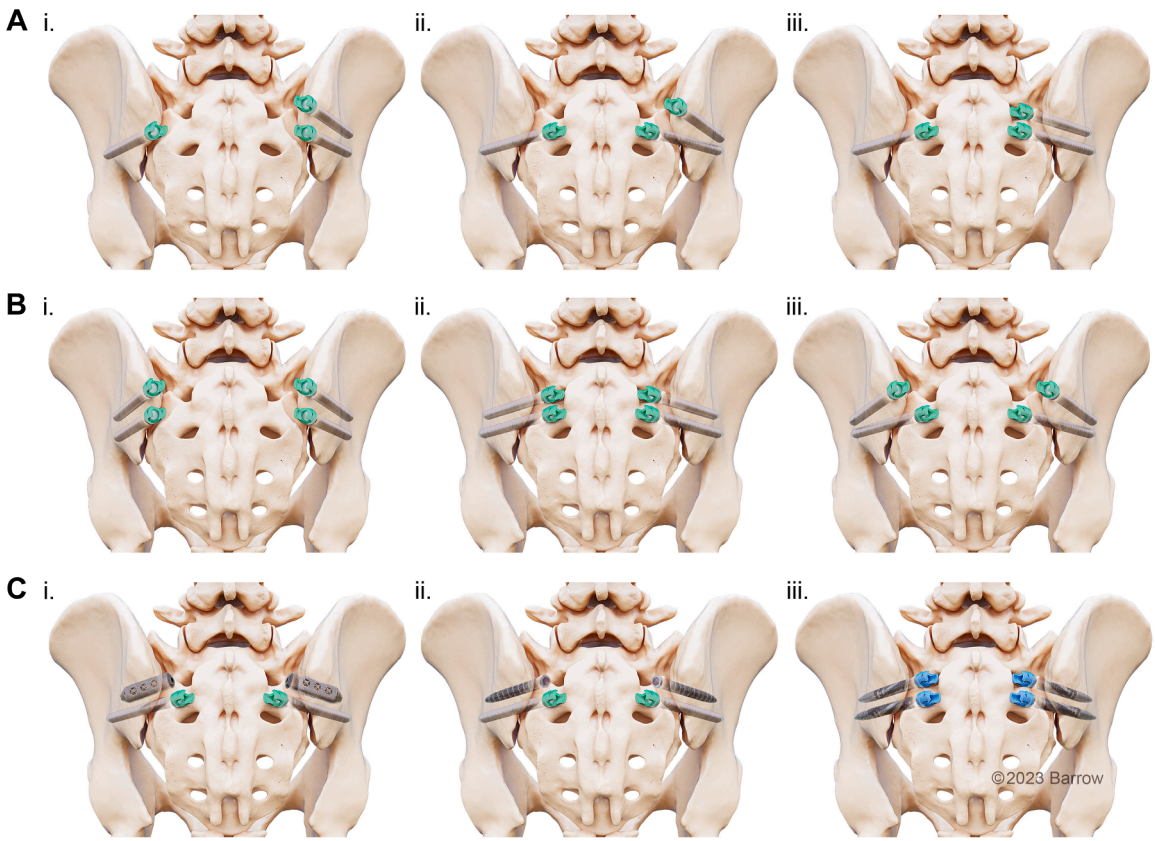

Fig. 1. Multipoint pelvic fixation strategies employed in the ISSG CADS database. **(A)** 3-Point pelvic fixation. i) Bilateral traditional iliac screws with unilateral accessory iliac screw (e.g., for kickstand rod). ii) Bilateral S2AI screws with unilateral accessory iliac screw (e.g., for kickstand rod). iii) Bilateral S2AI screws with unilateral accessory S2AI screw. **(B)** 4-Point pelvic fixation. i) Dual bilateral traditional iliac screws. ii) Dual bilateral S2AI screws. iii) Hybrid bilateral S2AI screws and bilateral accessory iliac screws. **(C)** Multipoint pelvic fixation with SI joint fusion. i) Bilateral S2AI screws with bilateral triangular porous titanium SI fusion devices. ii) Bilateral S2AI screws with bilateral freestanding (not connected to construct) threaded porous titanium SI fusion devices. iii) Dual bilateral porous titanium SI fusion screws with rod attachment using the S2AI trajectory. *Used with permission from Barrow Neurological Institute, Phoenix, Arizona.*

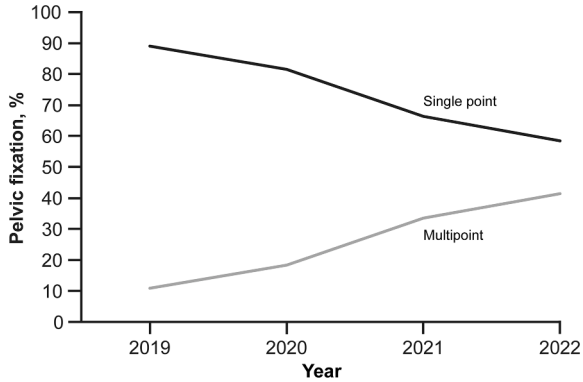

Fig. 2. Temporal trends in single versus multipoint pelvic fixation. Source: Complex Adult Deformity Surgery (CADS) study, International Spine Study Group (ISSG). *Used with permission from Barrow Neurological Institute, Phoenix, Arizona.*

outcomes in ASD patients requiring fixation and fusion across the lumbosacral junction. Iliac screw fixation began with a single point, bilateral fixation, using the traditional entry point. As the field has evolved, alternative trajectories and pelvic fixation configurations have been developed and applied to treating ASD (Table 1). We assessed various strategies and techniques for spinopelvic fixation, illustrating their customizability to suit diverse clinical needs.

4.1. Traditional iliac and S2AI screws

Traditional iliac fixation was the first widely adopted screw technique and remains a popular approach. The technique involves an entry point at the posterior superior iliac spine and screw trajectory through the cortical tables of the ilium traversing 1–2 cm above the greater sciatic notch. Iliac screws have clear biomechanical advantages over sacral screw fixation, offering protection against distal failure and lumbosacral nonunion.[9,18] However, iliac bolts necessitate access to the posterior superior iliac spine, requiring wide soft-tissue dissection and lateral offset connectors. Despite these advantages over sacral fixation, traditional iliac screws have also been associated with various complications, including screw lucency, pain due to screw prominence, screw fractures, and failures of the screw-rod connection system.[19,20] S2AI screws were introduced as an alternative to address some of these issues. S2AI screw placement utilizes a more medial entry point overlying the S2 pedicle in line with the S1 pedicle screw entry point. Given the more medial entry point, the screw trajectory is more lateral than the traditional iliac screw. The screw crosses the sacroiliac (SI) joint and travels between the two cortices of the ilium and above the greater sciatic notch. The S2AI technique was originally described in the pediatric scoliosis literature but has since been widely applied to the ASD population.[9,17,21] S2AI screws have several purported advantages over traditional iliac screws. Since the entry points for these screws are in line with lumbosacral pedicle screws, lateral offset connectors are not required. Furthermore, with a more anterior entry point deep to the posterior superior iliac spine, screw prominence causing gluteal pain and wound complications may be less problematic.[22-24] S2AI screws

may also be less vulnerable to loosening and revision since they travel across two additional cortical surfaces as they cross the SI joint.[24] However, technical challenges and higher rates of mechanical complications have also been reported with S2AI screws compared to traditional iliac screws.[25]

A modified iliac screw entry point has also been described using an "anatomic" entry point which is more medial than the traditional iliac screw entry point but still enters on the ilium as opposed to the sacral entry point with S2AI screws.[26,27] The modified iliac screw offers some of the same advantages as the S2AI screw, including less lateral muscular dissection and better alignment with sacral pedicle screws, often obviating the need for lateral offset connectors.

Safe and accurate screw placement is paramount for achieving the desired clinical outcomes, independent of the chosen entry point and trajectory. Screws can be placed using the freehand technique, fluoroscopic guidance, intraoperative navigation, or robotics, and there is literature to support that screws placed with all of these techniques can be executed safely with proper technique.[28-31]

4.2. Multipoint fixation

Despite the mechanical advantage of pelvic fixation over sacral fixation, distal failures are still common. They occur acutely in up to 5 % of patients with ASD and at higher rates at longer-term follow-ups from screw loosening, fracture, or both.[9,17,32] To further mitigate the risk of distal failure, many surgeons have begun to place two or more fixation points on each side of the pelvis. Additional points of pelvic fixation allow further dispersion of the forces on the distal fixation, restrict motion of the SI joint, and provide additional attachment points for accessory rods. Multipoint pelvic fixation is increasingly being employed, as evidenced by trends in the ISSG CADS study. In 2022, 41.5 % (56/135) of enrolled patients had multipoint fixation compared to 11.0 % (8/73) in 2019—a rapid rise in usage (Fig. 2). Various multipoint fixation configurations have been implemented; some permutations from the ISSG CADS study are summarized in Fig. 1.

Thoughtful planning of pelvic screw entry points and trajectories is particularly critical with multipoint pelvic fixation to avoid crowding of implants and maintain maximal bony purchase. Desired rod configuration and patient-specific anatomy impact screw placement and require entry point and trajectory adjustment.[33]

Multipoint pelvic fixation has been shown across multiple clinical studies to have low rates of pseudarthrosis and distal failure.[19,33-35] Originally described in patients requiring total sacrectomy for sacral tumor resection, dual iliac anchors are now used in patients undergoing ASD corrections.[34] Dual S2AI or iliac screws effectively correct flat back deformity, kyphoscoliosis, or severe coronal deformity.[19,33,35]

4.3. Sacroiliac fusion in ASD surgery

SI joint fusion is an emerging technique being incorporated into ASD spinopelvic constructs. The SI joint is a potential source of pain in patients with ASD at baseline and after surgical treatment; SI fusion is proposed to address this issue.[36,37] Some surgeons hypothesize that SI joint immobilization and fusion provide biomechanical advantages for building a more robust distal construct and reducing mechanical failures in spinal deformity treatment. A variety of SI fusion implants are commercially available. Many of these devices were initially developed to treat primary back pain caused by SI joint arthropathy. Sales of these implants are predicted to reach $360 million by 2024.[38]

The application of SI fusion to ASD has been explored in the laboratory and clinically in recent years.[37] In a cadaveric biomechanical study, de Andrada Pereira et al. found that augmenting S2AI screw fixation with laterally placed, triangular transarticular sacroiliac joint fixation (Fig. 1, C1) resulted in about a 20 % reduction in S2AI bending moment, which may offer protection from S2AI screw failure.[36] More recently, SI fusion implants have been designed for direct application to long-segment posterior constructs (Fig. 1, C2 and C3). One such device uses a self-harvesting porous titanium S2AI screw with an integrated tulip directly connecting the spinopelvic rods. In a clinical and radiographic study of patients treated with long-segment constructs to the pelvis, Alan et al. found the technique was feasible and safe.[39] Larger, higher-quality studies with long-term follow-up are needed to understand the clinical benefits that SI fusion provides for patients with ASD. A prospective multicenter randomized controlled trial (SILVIA study, ClinicalTrials.gov identifier: NCT04062630) is underway.

4.4. Multirod constructs

Although there is a companion article in this issue of *Seminars in Spine Surgery* that focuses exclusively on multi-rod constructs, we also briefly mention it in the context of pelvic fixation. Iliac screws are highly effective in sacral screw strain reduction but also cause a reciprocal increase in L5-S1 rod strain.[12,13] For this reason, sacral screw failure rates have decreased, but lumbosacral rod fracture rates have increased since the introduction of iliac screws.[9] To avoid distal rod fractures, many surgeons use accessory rods across the lumbosacral junction. Accessory rods can be applied using side-to-side domino connectors in the setting of more traditional single-point fixation on each side of the pelvis. With the advent of multipoint pelvic fixation, accessory iliac or S2AI screws can also serve as attachment points for creating multirod constructs to protect the primary rods from failure.[19] In a study of 358 patients who underwent pelvic fixation, multirod constructs across the lumbosacral junction had a very low rate of acute pelvic fixation failure (0.3 %), significantly lower than previously reported rates of iliac fixation failure.[24,40,41] This low rate is likely due to the reduction of primary rod strain provided by the accessory rods.[12,42] Multipoint pelvic fixation with supplemental rods is also employed for deformity correction maneuvers, as in the case of the "kickstand rod" technique.[43,44] The "kickstand rod" is anchored with an iliac screw placed cephalad and lateral to the traditional iliac screw entry point. The rod is attached proximally, and distraction forces are applied against the iliac wing to help correct the coronal imbalance. Several reports demonstrate that this technique is effective in achieving alignment goals.[35,43,44]

4.5. Future directions

Pelvic fixation is expected to continue to evolve. Implant technology will improve, and technical nuances will be refined. Enabling technology use, including intraoperative navigation and robotics, will likely continue to grow. These technological advancements are attractive because of mounting evidence of improved accuracy, which allows surgeons to optimize implant size, screw trajectory, and construct mechanics.[19,45,46] Iliac screw placement using navigation also decreases intraoperative radiation exposure and OR time.[47]

5. Conclusion

Pelvic fixation is a necessary adjunct to long-segment constructs spanning the lumbosacral junction in ASD to reduce rates of distal failure. Various pelvic fixation techniques are described and continue to be refined. The most common pelvic screw options are traditional iliac screws, modified iliac screws with anatomic entry points, and S2AI screws. Multipoint pelvic fixation is being increasingly used to augment the distal construct. Finally, SI fusion is being explored as another strategy to improve the biomechanics of spinopelvic constructs. The choice of pelvic fixation should be individualized based on patient anatomy, pathology, and other patient-specific factors such as bone quality.

Declaration of Competing Interest

None.

Acknowledgments

We thank the staff of Neuroscience Publications at Barrow Neurological Institute for assistance with manuscript preparation.

Disclosures

JDT: Consulting fees from ATEC, NuVasive, SeaSpine, SI-Bone. Royalties from ATEC and SeaSpine.

MARS: Consulting fees from Depuy, Synthes, Globus, NuVasive, and Stryker. Honoraria from BK Medical, Brainlab, and SI Bone. Grants from the Neurosurgery Research and Education Foundation, International Spine Study Group, AO Spine, National Institutes of Health, Patient-Centered Outcomes Research Institute, SLIP II, and Pacira. Stock in Spinicity/ISD and Discgenics. Royalties from Springer and Thieme.

RKE: Royalties from Globus Medical, NuVasive, SeaSpine, Aesculap, and SI Bone. Speakers Bureau for Radius. Consulting fees from NuVasive, SI Bone, SeaSpine, Medtronic, Spinal Elements, Biedermann-Motech, Depuy, Silony, and Neo. Stock in Alphatec, Spine, NuVasive, SeaSpine, Spine Innovations, and SI Bone. Research support from NuVasive, SeaSpine, Medtronic/Titan, SI Bone, and Scripps Clinic Medical Group. Additional financial/fellowship or material support from NuVasive, SeaSpine, and AONA. Board member/committee appointment for Scoliosis Research Society, San Diego Orthopaedic Society (past president), and San Diego Spine Foundation.

Financial support

None.

Submission category

Invited Review.

References

1 Schupper AJ, Shuman WH, Baron RB, et al. Utilization of the American Society of Anesthesiologists (ASA) classification system in evaluating outcomes and costs following deformity spine procedures. *Spine Deform*. 2021;9(1):185–190.
2 Schwab F, Dubey A, Gamez L, et al. Adult scoliosis: prevalence, SF-36, and nutritional parameters in an elderly volunteer population. *Spine (Phila Pa 1976)*. 2005;30(9):1082–1085.
3 Bess S, Line B, Fu KM, et al. The health impact of symptomatic adult spinal deformity: comparison of deformity types to United States population norms and chronic diseases. *Spine (Phila Pa 1976)*. 2016;41(3):224–233.
4 Kelly MP, Lurie JD, Yanik EL, et al. Operative versus nonoperative treatment for adult symptomatic lumbar scoliosis. *J Bone Joint Surg Am*. 2019;101(4):338–352.
5 Drazin D, Shirzadi A, Rosner J, et al. Complications and outcomes after spinal deformity surgery in the elderly: review of the existing literature and future directions. *Neurosurg Focus*. 2011;31(4):E3.
6 Kelly MP, Lenke LG, Bridwell KH, et al. Fate of the adult revision spinal deformity patient: a single institution experience. *Spine (Phila Pa 1976)*. 2013;38(19): E1196–E1200.
7 Klineberg EO, Passias PG, Poorman GW, et al. Classifying complications: assessing adult spinal deformity 2-year surgical outcomes. *Global Spine J*. 2020;10(7):896–907.
8 Sugawara R, Takeshita K, Inomata Y, et al. The Japanese Scoliosis Society Morbidity and Mortality Survey in 2014: the complication trends of spinal deformity surgery from 2012 to 2014. *Spine Surg Relat Res*. 2019;3(3):214–221.
9 Eastlack RK, Soroceanu A, Mundis Jr GM, et al. Rates of loosening, failure, and revision of iliac fixation in adult deformity surgery. *Spine (Phila Pa 1976)*. 2022;47 (14):986–994.
10 Edwards 2nd CC, Bridwell KH, Patel A, et al. Long adult deformity fusions to L5 and the sacrum. A matched cohort analysis. *Spine (Phila Pa 1976)*. 2004;29(18): 1996–2005.
11 Katsuura Y, Chang E, Sabri SA, et al. Anatomic parameters for instrumentation of the sacrum and pelvis: a systematic review of the literature. *J Am Acad Orthop Surg Glob Res Rev*. 2018;2(8):e034.
12 Godzik J, Hlubek RJ, Newcomb A, et al. Supplemental rods are needed to maximally reduce rod strain across the lumbosacral junction with TLIF but not ALIF in long constructs. *Spine J*. 2019;19(6):1121–1131.
13 Hlubek RJ, Godzik J, Newcomb A, et al. Iliac screws may not be necessary in long-segment constructs with L5-S1 anterior lumbar interbody fusion: cadaveric study of stability and instrumentation strain. *Spine J*. 2019;19(5):942–950.
14 McCord DH, Cunningham BW, Shono Y, et al. Biomechanical analysis of lumbosacral fixation. *Spine (Phila Pa 1976)*. 1992;17(8 Suppl):S235–S243.
15 Islam NC, Wood KB, Transfeldt EE, et al. Extension of fusions to the pelvis in idiopathic scoliosis. *Spine (Phila Pa 1976)*. 2001;26(2):166–173.
16 Kuklo TR, Bridwell KH, Lewis SJ, et al. Minimum 2-year analysis of sacropelvic fixation and L5-S1 fusion using S1 and iliac screws. *Spine (Phila Pa 1976)*. 2001;26 (18):1976–1983.
17 Elias E, Bess S, Line B, et al. Outcomes of operative treatment for adult spinal deformity: a prospective multicenter assessment with mean 4-year follow-up. *J Neurosurg Spine*. 2022:1–10.
18 McNeill IT, Rothrock RJ, Cho SK, et al. Pelvic fixation techniques and impact on sagittal balance: a literature review. *Semin Spine Surg*. 2017;29(4):184–191.
19 Polly Jr DW, Holton KJ, Soriano PO, et al. Multiple points of pelvic fixation: stacked S2-alar-iliac screws (S2AI) or concurrent s2ai and open sacroiliac joint fusion with triangular titanium rod. *JBJS Essent Surg Tech*. 2022;12(4). e21.00044.
20 von Glinski A, Elia CJ, Wiginton Jgt, et al. Iliac screw fixation revisited: improved clinical and radiologic outcomes using a modified iliac screw fixation technique. *Clin Spine Surg*. 2022;35(1):E127–e131.
21 Sponseller PD, Zimmerman RM, Ko PS, et al. Low profile pelvic fixation with the sacral alar iliac technique in the pediatric population improves results at two-year minimum follow-up. *Spine (Phila Pa 1976)*. 2010;35(20):1887–1892.
22 De la Garza Ramos R, Nakhla J, Sciubba DM, et al. Iliac screw versus S2 alar-iliac screw fixation in adults: a meta-analysis. *J Neurosurg Spine*. 2018;30(2):253–258.
23 Ilyas H, Place H, Puryear A. A comparison of early clinical and radiographic complications of iliac screw fixation versus S2 alar iliac (S2AI) fixation in the adult and pediatric populations. *J Spinal Disord Tech*. 2015;28(4):E199–E205.
24 Mazur MD, Ravindra VM, Schmidt MH, et al. Unplanned reoperation after lumbopelvic fixation with S-2 alar-iliac screws or iliac bolts. *Journal of Neurosurgery: Spine SPI*. 2015;23(1):67–76.
25 Guler UO, Cetin E, Yaman O, et al. Sacropelvic fixation in adult spinal deformity (ASD); a very high rate of mechanical failure. *Eur Spine J*. 2015;24(5):1085–1091.
26 Harrop JS, Jeyamohan SB, Sharan A, et al. Iliac bolt fixation: an anatomic approach. *J Spinal Disord Tech*. 2009;22(8):541–544.
27 von Glinski A, Yilmaz E, Ishak B, et al. The modified iliac screw: an anatomic comparison and technical guide. *World Neurosurg*. 2020;136:e608–e613.
28 Hlubek RJ, Almefty KK, Xu DS, et al. Safety and accuracy of freehand versus navigated iliac screws: results from 222 screw placements. *Spine (Phila Pa 1976)*. 2017;42(20). E1190-E1196.
29 Laratta JL, Shillingford JN, Meredith JS, et al. Robotic versus freehand S2 alar iliac fixation: in-depth technical considerations. *J Spine Surg*. 2018;4(3):638–644.
30 Shillingford JN, Laratta JL, Tan LA, et al. The free-hand technique for S2-alar-iliac screw placement: a safe and effective method for sacropelvic fixation in adult spinal deformity. *J Bone Joint Surg Am*. 2018;100(4):334–342.
31 Theologis AA, Burch S, Pekmezci M. Placement of iliosacral screws using 3D image-guided (O-Arm) technology and Stealth Navigation: comparison with traditional fluoroscopy. *Bone Joint J*. 2016;(5):696–702, 98-B.
32 Martin CT, Polly DW, Holton KJ, et al. Acute failure of S2-alar-iliac screw pelvic fixation in adult spinal deformity: novel failure mechanism, case series, and review of the literature. *J Neurosurg Spine*. 2022;36(1):53–61.
33 Tang Z, Hu Z, Zhu Z, et al. The utilization of dual second sacral alar-iliac screws for spinopelvic fixation in patients with severe kyphoscoliosis. *Orthop Surg*. 2022;14(7): 1457–1468.
34 Ebata S, Ohba T, Oba H, et al. Bilateral dual iliac screws in spinal deformity correction surgery. *J Orthop Surg Res*. 2018;13(1):260.
35 Park PJ, Lin JD, Makhni MC, et al. Dual S2 alar-iliac screw technique with a multirod construct across the lumbosacral junction: obtaining adequate stability at the lumbosacral junction in spinal deformity surgery. *Neurospine*. 2020;17(2):466–470.
36 de Andrada Pereira B, Wangsawatwong P, Lehrman JN, et al. Biomechanics of a laterally placed sacroiliac joint fusion device supplemental to S2 alar-iliac fixation in a long-segment adult spinal deformity construct: a cadaveric study of stability and strain distribution. *J Neurosurg Spine*. 2022;36(1):42–52.
37 Martin CT, Holton KJ, Jones KE, et al. Bilateral open sacroiliac joint fusion during adult spinal deformity surgery using triangular titanium implants: technique description and presentation of 21 cases. *J Neurosurg Spine*. 2022;36(1):86–92.
38 SPINEMarketGroup. 10 Sacroiliac Joint Fusion Systems to know…!, 2020, https://thespinemarketgroup.com/10-sacroiliac-joint-fusion-systems-to-know/. Accessed November 1.
39 Alan N, Lee KE, Zhou JJ, et al. Bilateral sacroiliac joint fusion in long constructs using self-harvesting porous S2-alar iliac screws with an integrated tulip: technical considerations and early clinical and radiographic experience. *Neurosurg Focus*. 2023; 55(1). E5.
40 Hyun SJ, Jung JM, Kim KJ, et al. Durability and failure types of S2-alar-iliac screws: an analysis of 312 consecutive screws. *Oper Neurosurg (Hagerstown)*. 2020;20(1): 91–97.
41 Lee NJ, Park PJ, Puvanesarajah V, et al. How common is acute pelvic fixation failure after adult spine surgery? A single-center study of 358 patients. *J Neurosurg Spine*. 2023;38(1):91–97.
42 Godzik J, de Andrada Pereira B, Sawa AGU, et al. Impact of dual-headed pedicle screws on the biomechanics of lumbosacral junction multirod constructs. *J Neurosurg Spine*. 2021;34(5):691–699.
43 Buell TJ, Christiansen PA, Nguyen JH, et al. Coronal correction using kickstand rods for adult thoracolumbar/lumbar scoliosis: case series with analysis of early outcomes and complications. *Oper Neurosurg (Hagerstown)*. 2020;19(4):403–413.
44 Makhni MC, Cerpa M, Lin JD, et al. The "kickstand rod" technique for correction of coronal imbalance in patients with adult spinal deformity: theory and technical considerations. *J Spine Surg*. 2018;4(4):798–802.

45 Li B, Chan AK, Mummaneni PV, et al. Preliminary experience using S1-alar iliac fixation with navigation: technical note. *J Neurosurg Spine*. 2021;35(6):774–779.
46 Tamaki R, Wada K, Okazaki K. Surgical technique and accuracy of S2 alar-iliac screw insertion using intraoperative O-arm navigation: an analysis of 120 screws. *World Neurosurg*. 2020;144:e326–e330.
47 Hoffmann MF, Yilmaz E, Norvel DC, et al. Navigated iliac screw placement may reduce radiation and OR time in lumbopelvic fixation of unstable complex sacral fractures. *Eur J Orthop Surg Traumatol*. 2021;31(7):1427–1433.