



BRIEF REPORT

# The Eyes Have It—for Idiopathic Pulmonary Fibrosis: a Preliminary Observation

Roy A. Pleasants · Armando D. Bedoya · Joel M. Boggan ·  
Karen Welty-Wolf · Robert M. Tighe

Received: June 27, 2022 / Accepted: July 21, 2022 / Published online: August 4, 2022  
© The Author(s) 2022

## ABSTRACT

**Introduction:** The disease origins of idiopathic pulmonary fibrosis (IPF), which occurs at higher rates in certain races/ethnicities, are not understood. The highest rates occur in white persons of European descent, particularly those with light skin, who are also susceptible to lysosomal organelle dysfunction of the skin

---

R. A. Pleasants (✉)  
Division of Pulmonary Diseases and Critical Care  
Medicine, University of North Carolina at Chapel  
Hill, 7202 Marsico Hall, 125 Mason Farm Rd, Chapel  
Hill, NC, USA  
e-mail: pleas005@email.unc.edu

R. A. Pleasants  
Durham VA Medical Center, Durham, NC, USA

A. D. Bedoya  
Duke University School of Medicine and  
Department of Biostatistics and Bioinformatics,  
Durham, NC, USA

J. M. Boggan  
Department of Medicine, Durham Veterans Affairs  
Healthcare System, Durham, NC, USA

J. M. Boggan  
Division of General Internal Medicine, Department  
of Medicine, Duke University School of Medicine,  
Durham, NC, USA

K. Welty-Wolf · R. M. Tighe  
Duke University School of Medicine, Durham  
Veterans Affairs Healthcare System, Durham, NC,  
USA

leading to fibroproliferative disease . We had observed clinically that the vast majority of patients with IPF had light-colored eyes, suggesting a phenotypic characteristic.

**Methods:** We pursued this observation through a research database from the USA Veterans Administration, a population that has a high occurrence of IPF due to predominance of elderly male smokers. Using this medical records database, which included facial photos, we compared the frequency of light (blue, green, hazel) and dark (light brown, brown) eyes among white patients diagnosed with IPF compared with a control group of lung granuloma only (no other radiologic evidence of interstitial lung disease).

**Results:** Light eye color was significantly more prevalent in patients with IPF than in the control group with lung granuloma [114/147 (77.6%) versus 129/263 (49.0%),  $p < 0.001$ ], indicating that light-colored eyes are a phenotype associated with IPF .

**Conclusion:** We provide evidence that light eye color is predominant among white persons with IPF.

**Keywords:** Idiopathic pulmonary fibrosis; Genetics; Eye color; Lysosomal organelle dysfunction

### Key Summary Points

Certain fibroproliferative diseases have been reported to be more common among white persons, including idiopathic pulmonary fibrosis (IPF).

On the basis of prior clinical observation of an association between light eye color and IPF, we explored this association further in a database containing medical records of a population with a high prevalence of IPF and for whom facial photos were taken as part of their electronic medical record.

Comparing the frequency of light (blue, green, hazel) and dark (brown) eye color between white persons diagnosed with IPF and lung granuloma only, the prevalence of light eye color was statistically higher in patients with IPF (77.6%) than in those with lung granuloma (49.0%).

This observation concurs with genetically related lysosomal organelle dysfunction apparent in white persons for eye and skin diseases, as well as premature gray hair.

Light eye color is predominant among white persons diagnosed with IPF.

## INTRODUCTION

Idiopathic pulmonary fibrosis (IPF) is a chronic lung disease in elderly individuals driven by a combination of host genetics and environmental factors that causes progressive lung fibrosis resulting in respiratory failure and mortality. Certain clinical and demographic factors clearly associate with increased IPF incidence and prevalence. A large USA Medicare claims study found IPF to be more commonly observed in white persons, accounting for 90% of cases [1]. This was confirmed by other studies demonstrating that Black, Asian, and Hispanic

cohorts had lower rates of IPF than white persons [2]. The reasons for these observed racial/ethnic differences in IPF prevalence are unclear but might implicate differences in genetics among these groups. Specific host genetics have previously been observed as factors contributing to IPF incidence [3].

Distinct genetic susceptibility factors have been reported in IPF. In a study of kindred cohorts with familial pulmonary fibrosis, telomerase (TERT) mutation carriers, compared with noncarriers, were found to have shorter telomeres, impaired lung function, and increased frequency of radiographic interstitial abnormalities [4]. Notably, the TERT mutation carriers were also found to have higher rates of premature gray hair [4]. This raises the question of whether other clinical features are associated with IPF. Clinically, over a period of several years at our academic medical center, we observed that light eye color was a common phenotypical feature among white persons diagnosed with IPF. Interestingly, light eye color, in addition to albinism, occurs in individuals with Hermansky–Pudlak syndrome (HPS) [5, 6], which can lead to the development of progressive pulmonary fibrosis (HPSPF) at an early age. This suggests a potential premise for an association between light eye color and IPF. Another fibroproliferative disease, Dupuytren's disease, causes hand contracture and originated in Northern Europe, an area also associated with high rates of blue eyes [7].

To our knowledge, beyond HPS, we are not aware of published reports associating fibrotic lung diseases with eye color. Given this, and our prior observation that most white patients with IPF in the clinical setting had light-colored eyes, we evaluated the possible association of eye color and IPF as part of a large epidemiologic study of interstitial lung disease (ILD).

## METHODS

To address the question of light eye color association with increased IPF incidence, we utilized data in a retrospective cohort study of ILD from six Veterans Affairs (VA) Health Systems in North Carolina and Virginia [8]. This

retrospective study was approved by the Durham VA Medical Center institutional review board in accordance with the Helsinki Declaration of 1964 and its amendments. This study identified 3293 patients of all races through billing records from 2009 and 2015 based on ICD International Classification of Diseases-9 codes, 2604 of whom were identified as white persons and 703 of whom had no evidence of ILD. Following identification, collection of electronic health record (EHR) data was supplemented with an in-depth manual chart review of outpatient encounters that included procedures, radiography reports, and physical examinations. A unique feature of the VA EHR is the availability of facial photos of sufficient quality to judge eye color. One reviewer recorded eye color as light (blue, green, hazel) or dark (brown or light brown) from the EHR when available and discernible. Among these 2604 patients with facial photos of discernible eye color, those with IPF (ICD 9 516.3) or lung granuloma only (control) were selected for this analysis. Lung granuloma was coded under post-inflammatory fibrosis (ICD 9 515.0) and included in this analysis if the radiologic report demonstrated only granuloma and no other evidence of ILD.

## RESULTS

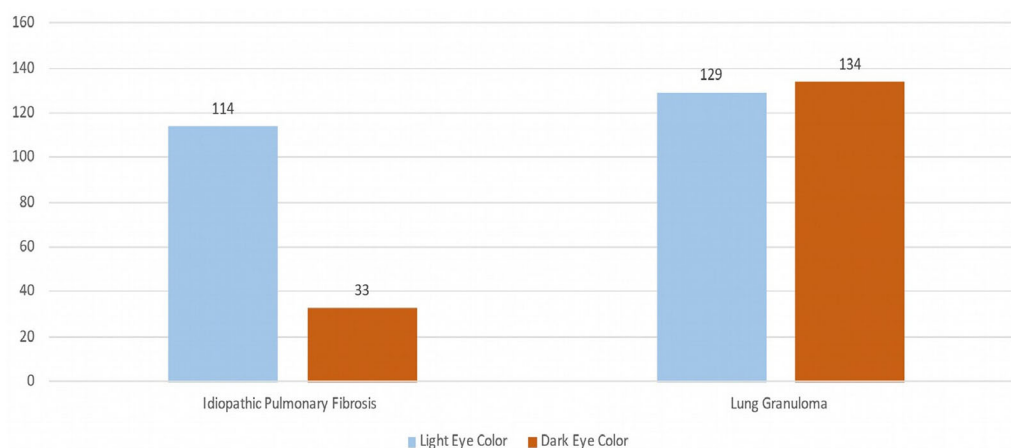
Among the 248 white patients in the EHR with IPF (based on the ICD-9 code 516.31), 147 (59% of total) had facial photos of adequate quality to judge eye color as light or dark. For the control group, we identified 397 white patients with lung granuloma only. The median age among patients with lung granuloma was 66 years, and 69 years for those with IPF. Eye color was available in 263 (66%) of the control patients. A small segment of patients who had both retinal photos and facial photos was used to judge the reviewer's accuracy at determining eye color. Among 48 white patients with any ILD with both retinal and facial photos, the reviewer matched colors in 31/33 (93.9%) cases for light eyes and 14/15 (93.3%) cases for dark eyes. Among 147 white patients with IPF, the prevalence of light-colored eyes was 77.6% (114/147)

(Fig. 1). In the 263 white patients with lung granuloma only, 49.0% (129/263) had light-colored eyes, a difference that was statistically significantly different ( $p < 0.001$ ).

## DISCUSSION

Human genes associated with protection from the external environment include those for eye color, skin color, and lung epithelium. Most of the genes associated with eye color are involved in the production, transport, or storage of a pigment called melanin [9]. Gene mutations in lysosomal organelle function in the eyes and skin can alter melanin production by melanosomes [5], thereby increasing the risk of skin damage and macular degeneration [10]. Premature gray hair is also related to melanocyte function in hair follicles, where downregulation of pigmentation genes is present [11]. Similarly, lysosomal organelle function is involved in melanosomes and melanin production in hair follicles [12].

The evidence that individuals with HPS, a rare genetic disease, exhibit hypopigmentation of the skin and eyes, associated with an ILD clinically and pathologically similar to IPF, suggests a potential genetic link between eye color and IPF [5]. Interestingly, the genetic defects leading to the light eye colors in mutated HPS mice (*HPS1* and *HPS4*) are also highly associated with HPS-associated pulmonary fibrosis [13]. Also supporting this, injury to type II alveolar epithelial cells is a common feature of both IPF [3] and HPSPF [5] disease pathogenesis. In individuals with an *HPS1* mutation, it is reported that the incidence of pulmonary fibrosis is 100%, the highest penetrance of any ILD mutation [6]. Furthermore, a study of mice with 15 different HPS mutations found that the mice with the lightest coat, ears, and eyes (red versus ruby or black) exhibited lamellar body accumulation of surfactant, a feature observed in dysfunctional alveolar type 2 cells [13]. Supporting this link in humans, patients with HPS who have brown hair and eyes associated with the *HPS 3, 5, and 6* mutations do not exhibit the same prevalence of HPSPF [6]. This suggests a potential link between eye and skin color and



**Fig. 1** Frequency of light and dark eye color among white patients in a Veteran's Administration population with idiopathic pulmonary fibrosis and lung granuloma. Light eye color (blue, green, hazel) compared with dark eye color

(light brown, brown). Difference between light and dark eye color between two cohorts was statistically significant  $p < 0.001$  (chi-square with Yates correction, two-tailed test)

development of pulmonary fibrosis that could underlie our association between light eye color and IPF prevalence.

There are some limitations to the study that should be acknowledged. Although this study is consistent with our initial clinical observation, it should be considered early evidence warranting further study with additional cohorts. Not all patients had facial photos or were of adequate quality to enable us to clearly define eye color in individuals. In addition, only 79% of patients diagnosed with IPF in the EHR had accessible high-resolution computed tomography imaging to confirm usual interstitial pneumonia. Finally, we do not report whether the group of individuals with light eye color and IPF diagnosis had a more aggressive clinical disease course.

## CONCLUSION

We present preliminary evidence indicating that light eye color is associated with increased prevalence of IPF among white persons. Whether there is a direct connection between lighter eyes and development of IPF or it is simply a phenotypic representation of underlying genetic traits is uncertain and requires further investigation.

## ACKNOWLEDGEMENTS

**Funding.** This research was supported by an investigator-initiated grant from Boehringer Ingelheim Pharmaceuticals, Inc. (BIPI). BIPI had no role in the design, analysis or interpretation of the results in this study. As this component of the study was not part of the original grant agreement and objectives, they had no role in reviewing this specific manuscript.

**Contributorship Statement.** RAP contributed to conception and design of the study, data acquisition and analysis, drafting and revisions of the article. AB, JB, and KW assisted in data acquisition and analysis and edited the draft. RMT assisted with the study design, analysis and editing of the manuscript. RAP is the guarantor of the content of the manuscript. RAP agrees to be accountable for all aspects of the work in ensuring that questions related to the accuracy or integrity of any part of the work are appropriately investigated and resolved including the data and analysis.

**Conflicts of Interest (disclosures).** RAP—Research for Astra Zeneca, Boehringer Ingelheim, Teva; RMT—Received investigator initiated grant and has been a member of an

advisory board from Boehringer Ingelheim, also has an investigator initiated grant from Genentech. AB; JG; KW—No conflicts of interest.

**Compliance with Ethics Guidelines.** This retrospective study was approved by the Durham VA Medical Center Institutional Review Board in accordance with the Helsinki Declaration of 1964 and its amendments.

**Open Access.** This article is licensed under a Creative Commons Attribution-NonCommercial 4.0 International License, which permits any non-commercial use, sharing, adaptation, distribution and reproduction in any medium or format, as long as you give appropriate credit to the original author(s) and the source, provide a link to the Creative Commons licence, and indicate if changes were made. The images or other third party material in this article are included in the article's Creative Commons licence, unless indicated otherwise in a credit line to the material. If material is not included in the article's Creative Commons licence and your intended use is not permitted by statutory regulation or exceeds the permitted use, you will need to obtain permission directly from the copyright holder. To view a copy of this licence, visit <http://creativecommons.org/licenses/by-nc/4.0/>.

## REFERENCES

- Raghu G, Chen SY, Yeh WS et al. Idiopathic pulmonary fibrosis in US Medicare beneficiaries aged 65 years and older: incidence, prevalence, and survival, 2011–11. *Lancet Respir* 2014;2:566–72.
- Sgalla G, Biffi A, Richeldi L. Idiopathic pulmonary fibrosis: diagnosis, epidemiology, and natural history. *Respirology*. 2016;21:427–37.
- Puglisi S, Torrisi SE, Giuliano R, et al. What we know about the pathogenesis of idiopathic pulmonary fibrosis. *Semin Respir Crit Care Med*. 2016;37:358–67.
- Diaz de Leon A, Cronkhite JT, Yilmaz C, Brewington C, Wang R, Xing C, Hsia CCW, Garcia CK. Subclinical lung disease, macrocytosis, and premature graying in kindreds with telomerase (TERT) mutations. *Chest*. 2011;140(3):753–63.
- Bowman SL, Bi-Karchin J, Le L, Marks MS. The road to LROs: insights into lysosome-related organelles from Hermansky–Pudlak syndrome and other rare diseases. *Traffic*. 2019;20(6):404–35.
- Seward SL, Gahl WA. Hermansky–Pudlak syndrome: healthcare throughout life. *Pediatrics*. 2013;132:153–60.
- Epidemiology of Dupuytren's Disease. In: Berger A, Delbrück A, Brenner P, Hinzmann R (eds) *Dupuytren's disease*. Berlin, Heidelberg: Springer. <https://doi.org/10.1007/978-3-642-78517-7>
- Bedoya A, Pleasants R, Boggan JC, et al. Interstitial lung disease in a veterans administration network: a retrospective cohort study. *PLoS ONE*. 2021;16(3): e0247316.
- Mackey DA, Wilkinson CH, Kearns LS. Classification of iris colour: review and refinement of classification schema. *Clin Exp Ophthalmol*. 2011;39:462–71.
- Sturm RA, Duffy DL. Human pigmentation genes under environmental selection. *Genome Biol*. 2012;13:248.
- Bian Y, Wei G, Song X, Yun L, et al. Global down-regulation of pigmentation-associated genes in premature hair graying. *Exp Ther Med*. 2019;18: 1155–63.
- Wiriyaermskul P, Moriyama S, Nagamori S. Membrane transport proteins in melanosomes: regulation of ions for pigmentation. *Biochim Biophys Acta Biomembr* 2020;1862(12):183318.
- Gautam R, Novak EK, Tan J, et al. Interaction of Hermansky–Pudlak syndrome genes in the regulation of lysosome-related organelles. *Traffic*. 2006;7: 779–92.