

# Key Pathogenic Factors in Coronavirus Disease 2019–Associated Coagulopathy and Acute Lung Injury Highlighted in a Patient With Copresentation of Acute Myelocytic Leukemia: A Case Report

Lyra B. Olson, AB,\* Ibtehaj A. Naqvi, MD, PhD,† Daniel J. Turner, MD,‡ Sarah A. Morrison, PhD,† Bryan D. Kraft, MD,‡ Lingye Chen, MD,‡ Bruce A. Sullenger, PhD,† Smita K. Nair, PhD,† Loretta G. Que, MD,‡ and Jerrold H. Levy, MD§

The role of concurrent illness in coronavirus disease 2019 (COVID-19) is unknown. Patients with leukemia may display altered thromboinflammatory responses. We report a 53-year-old man presenting with acute leukemia and COVID-19 who developed thrombotic complications and acute respiratory distress syndrome. Multiple analyses, including rotational thromboelastometry and flow cytometry on blood and bronchoalveolar lavage, are reported to characterize coagulation and immune profiles. The patient developed chemotherapy-induced neutropenia that may have protected his lungs from granulocyte-driven hyperinflammatory acute lung injury. However, neutropenia also alters viral clearing, potentially enabling ongoing viral propagation. This case depicts a precarious equilibrium between leukemia and COVID-19. (A&A Practice. 2021;15:e01432.)

## GLOSSARY

**AML** = acute myeloid leukemia; **ARDS** = acute respiratory distress syndrome; **BAL** = bronchoalveolar lavage; **BALF** = bronchoalveolar lavage fluid; **COVID-19** = coronavirus disease 2019; **CT** = computed tomography; **DAH** = diffuse alveolar hemorrhage; **EQUATOR** = Enhancing the Quality and Transparency of Health Research; **EXTEM** = extrinsically activated test with tissue factor; **FIBTEM** = fibrin-based extrinsically activated test with tissue factor and the platelet inhibitor cytochalasin D; **FLT3** = fms-like tyrosine kinase 3; **ICU** = intensive care unit; **IG** = immature neutrophils; **IG1** = immature granulocyte (least mature); **IG1-3** = CD16lo immature neutrophils; **IG2** = immature granulocyte (moderate maturity); **IG3** = immature granulocyte (most mature); **INTEM** = intrinsically activated test using ellagic acid; **IRB** = Institutional Review Board; **MNs** = mature neutrophils; **NC** = nasal cannula; **ROTEM** = rotational thromboelastometry; **SARS-CoV-2** = severe acute respiratory syndrome coronavirus 2; **SSC-A** = side scatter area; **TIA** = transient ischemic attack; **WBC** = white blood count

Managing coronavirus disease 2019 (COVID-19) patients with additional comorbid conditions poses major challenges to clinicians. Patients with hematologic malignancies and COVID-19 have worse outcomes<sup>1</sup> that include increased illness severity<sup>2</sup> as well as an increased risk of mortality from secondary bacterial infections.<sup>3</sup> We present a patient with a new diagnosis of acute

myeloid leukemia (AML) together with severe acute respiratory syndrome coronavirus 2 (SARS-CoV-2) viral infection complicated by thrombotic and respiratory events in which leukemia and subsequent chemotherapeutic treatment may have been protective against more severe complications of COVID-19. In parallel, we present this patient's rotational thromboelastometry (ROTEM) data and paired flow cytometric immune analysis of both peripheral blood and bronchoalveolar lavage (BAL) to highlight the central pathogenic drivers of COVID-19 coagulopathy and acute lung injury. We discuss how the unique cellular milieu of this patient with AML receiving chemotherapy may have attenuated more severe pulmonary complications of COVID-19.

This article adheres to the applicable Enhancing the Quality and Transparency of Health Research (EQUATOR) guidelines. Consent via written health insurance portability and accountability act authorization was obtained from the patient for use of details of his case and clinical course. This patient and the other severely ill COVID-19 patient without AML included for comparison were enrolled and samples collected under Duke Institutional Review Board (IRB)-approved COVID-19 biorepository (Pro00101196).

From the \*Duke Medical Scientist Training Program, Department of Pharmacology and Cancer Biology and †Department of Surgery, Duke University School of Medicine, Durham, North Carolina; ‡Division of Pulmonary, Allergy, and Critical Care Medicine, Department of Medicine, Duke University Medical Center, Durham, North Carolina; and §Departments of Anesthesiology, Critical Care, and Surgery, Duke University School of Medicine, Durham, North Carolina.

Accepted for publication February 8, 2021.

Funding: B.A.S. and S.K.N. were supported by discretionary funds from the Duke Department of Surgery.

Conflicts of Interest: See Disclosures at the end of the article.

Address correspondence to Jerrold H. Levy, MD, Departments of Anesthesiology, Critical Care, and Surgery, Duke University School of Medicine, 2301 Erwin Rd, Durham, NC 27710. Address e-mail to jerrold.levy@duke.edu.

Copyright © 2021 International Anesthesia Research Society.  
DOI: 10.1213/XAA.0000000000001432

Analysis was performed under Duke IRB-approved performance protocol (Pro00105315).

### CASE DESCRIPTION

A 53-year-old man developed fever and malaise 7 days before admission after visiting his daughter, who tested positive for SARS-CoV-2. He presented to the hospital with abdominal pain, a temperature of 37.8 °C, splenomegaly, anemia, and thrombocytopenia. His white blood count (WBC) was 78,000/mL<sup>3</sup> with 37% myeloblasts, and his SARS-CoV-2 test was positive. Peripheral flow-cytometry revealed AML, and he was admitted and initially received hydroxyurea. His subsequent peripheral myeloblast evaluation revealed the FLT3 mutation, a finding that confers a poor prognosis in patients with AML. As a result, gilteritinib (a tyrosine kinase inhibitor) generally used for relapsed or refractory FLT3-mutated disease was administered off-label to temporize AML until resolution of his SARS-CoV-2 infection. On admission, the patient was without respiratory symptoms, and his chest radiograph was clear, but he was empirically started on vancomycin and cefepime because of his leukemia.

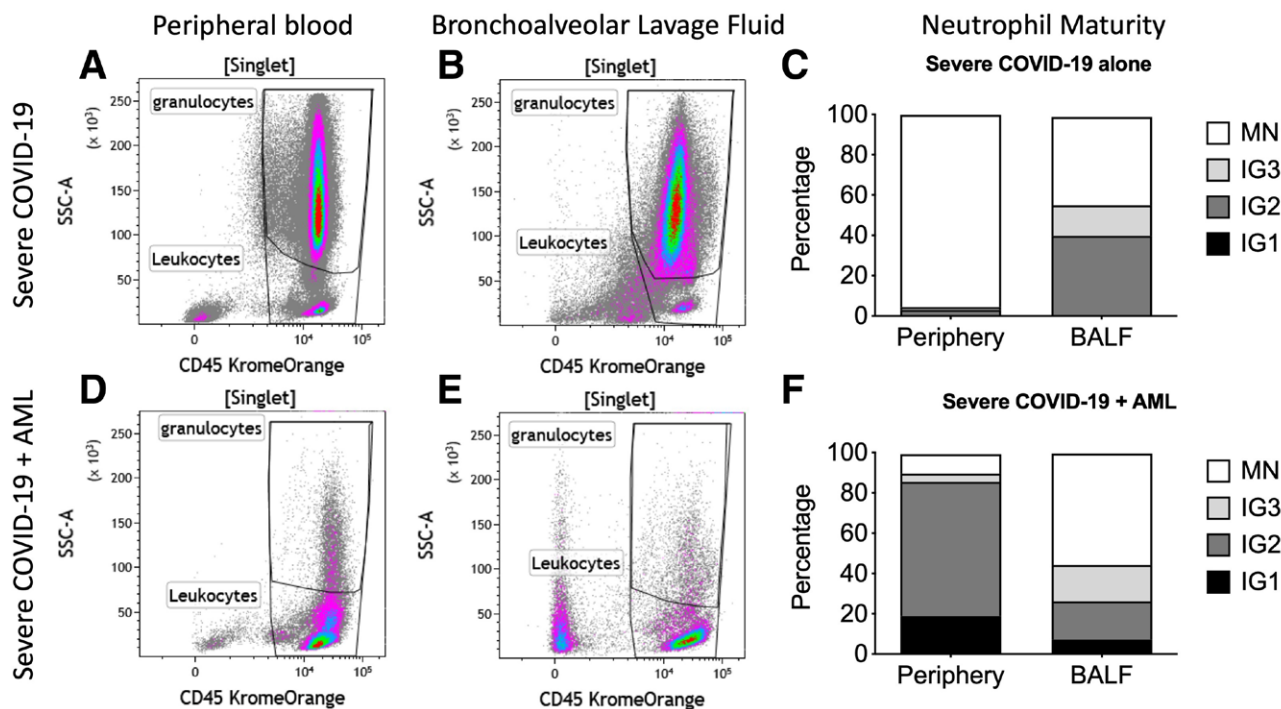
On hospital day 4, he developed sudden dizziness, dysarthria with left-sided facial droop, and upper extremity weakness. As shown in the Table, he had elevated D-dimer and fibrinogen levels and a WBC of 22,000/mL<sup>3</sup>. His head computed tomography (CT) scan and subsequent magnetic resonance imaging revealed no evidence of an acute infarct. Symptoms resolved within 24 hours, but over the next 7 days, he developed fever, dyspnea, and hypoxemia. Isavuconazole was started for potential fungal infection and remdesivir for COVID-19 pneumonia. The patient received 4 units each of platelets and red blood cells between hospital days 5 and 10, with a hemoglobin transfusion goal of >7g/dL and platelet transfusion goal of >10 × 10<sup>9</sup>/L. The patient subsequently developed hemoptysis with worsening hypoxemia despite high-flow oxygen, and his chest radiograph showed progression of bilateral pulmonary infiltrates requiring emergency intubation and mechanical ventilation. Bronchoscopy with serial BAL revealed diffuse alveolar hemorrhage, but bacterial and fungal cultures were negative. After 3 days, the patient was weaned from mechanical ventilation and extubated but required further management of ongoing neutropenic fever. He was discharged on hospital day 36. The Table highlights the major events of his clinical course and provides a daily summary of clinical laboratory data and treatments during his time in the intensive care unit (ICU).

Peripheral blood and BAL fluid were collected for analysis following intubation as part of an IRB-approved COVID-19 biorepository. Peripheral blood flow cytometry revealed chemotherapy-induced neutropenia (Figure 1D) compared to neutrophilia in severely ill COVID-19 patients (Figure 1A)<sup>4</sup> and increased CD16lo immature granulocytes (Figure 1F) consistent with elevated myeloblast production in AML. BAL fluid had sparse neutrophils (Figure 1E), but a similar profile of neutrophil maturity compared to BAL fluid from a patient with COVID-19 alone (Figure 1C, F), reflective of appropriate recruitment of immature neutrophils to the site of infection. ROTEM revealed abnormally

**Table. Clinical Laboratory Data, Medications, and Events During Hospital Course**

Hospital day	0	1	2	3	4	5	6	7	8	9	10	11	12	13	14
Key events	Admitted	Persistent fevers	Persistent fevers	TIA transferred to ICU	TIA transferred to ICU	Persistent fever, worsening respiratory distress	Persistent fever, worsening respiratory distress	Persistent fever, worsening respiratory distress	Persistent fever, worsening respiratory distress	Persistent fever, worsening respiratory distress	Persistent fever, worsening respiratory distress	Intubated, BAL reveals DAH	Intubated, BAL reveals DAH	Intubated, BAL reveals DAH	Extubated
White blood count (×10 <sup>3</sup> /mL)	78.5	77.3	52.8	24.1	22.0	8.7	7.3	1.4	1.0	0.8	1.0	0.9	1.2	1.3	1.3
Segmented neutrophil (%)	4	2	3	8	7	7	2	8	4	23	22	19	35	30	31
Myeloblast (%)	37	29	34	28	33	40	9	15	5	2	2	3	1	62	51
Lymphocyte (%)	14	7	19	20	14	29	36	52	68	66	70	70	54	6	7
Monocyte (%)	44	58	40	43	46	20	49	25	16	8	5	1	5	6	7
Hemoglobin (g/dL)	9.5	9.8	7.6	6.4	7.5	6.5	7.1	5.3	7.8	6.8	7.3	7.4	7.4	7.8	9.0
Platelet (×10 <sup>9</sup> /L)	36	32	25	11	14	9	14	7	10	14	19	19	22	28	18
Fibrinogen (mg/dL)	349	349	216	252	387	401	354	318	360	332	367	396	453	473	463
D-dimer (ng/mL)	10,565	10,565	34,610	17,090	17,090	9676	5754	6514	2777	3607	3611	4870	4859	5395	6362
Respiratory support	None	None	None	None	None	NC	High-flow NC	High-flow NC	High-flow NC	High-flow NC	High-flow NC	Mechanical ventilation	Mechanical ventilation	Mechanical ventilation	NC
AML treatment	Hydroxyurea	Hydroxyurea	Hydroxyurea	Hydroxyurea	Hydroxyurea	Hydroxyurea	Gilteritinib	Gilteritinib	Gilteritinib	Gilteritinib	Gilteritinib	Gilteritinib	Gilteritinib	Gilteritinib	Gilteritinib
Antibiotics	None	None	None	Vancomycin, cefepime	Vancomycin, cefepime	Vancomycin, cefepime	Vancomycin, cefepime, isavuconazole	Vancomycin, cefepime, isavuconazole	Vancomycin, cefepime, isavuconazole	Vancomycin, cefepime, isavuconazole	Vancomycin, cefepime, isavuconazole	Vancomycin, cefepime, isavuconazole	Vancomycin, cefepime, isavuconazole	Vancomycin, cefepime, isavuconazole	Vancomycin, cefepime, isavuconazole
COVID-19 treatment	None	None	None	None	None	None	Remdesivir	Remdesivir	Remdesivir	Remdesivir	Remdesivir	Remdesivir	Remdesivir	Remdesivir	Remdesivir

Abbreviations: AML, acute myeloid leukemia; BAL, bronchoalveolar lavage; COVID-19, coronavirus disease 2019; DAH, diffuse alveolar hemorrhage; ICU, intensive care unit; NC, nasal cannula; TIA, transient ischemic attack.



**Figure 1.** Comparison of peripheral BALF immune cell analysis from a COVID-19 patient requiring mechanical ventilation and the patient with AML and COVID-19. The patient with COVID-19 alone demonstrates peripheral neutrophilia typical of severe COVID-19, marked by increased percentage of granulocytes (A), specifically MNs (C). The COVID-19 patient has an elevated percentage of CD16lo IGs (5.9% of neutrophils) (C, left column) compared to healthy individuals (<1%), indicating an emergency myelopoietic response to the disease process. B, The BAL of the patient with COVID-19 alone also demonstrates neutrophilia typical of ARDS with elevated granulocytes. There is an increased percentage of IG1-3 in the BAL compared to blood (C), demonstrating the propensity for newly produced neutrophils to localize to the site of infection or inflammation. D, As a result of chemotherapy, the patient with both COVID-19 and AML has sparse granulocytes. This patient also had higher proportion of immature CD16lo neutrophils in the blood (F, left column) than the patient with COVID alone (C, left column), indicating ongoing AML-driven production of immature neutrophils with probable contribution from COVID-19 as well. In the lungs, this patient had sparse granulocytes (E) fitting with his overall neutropenia. Despite the reduced presence of neutrophils in the lungs, this patient has a similar proportion of immature CD16lo neutrophils (F, right column) as the patient with COVID alone (C, right column), indicating that intact recruitment of neutrophils to the lungs in response to the disease process. Neutrophils were identified from granulocytes as CD294neg/CD15pos cells. Of those neutrophils, MNs were identified as CD16high/CD11bpos, and CD16lo IG were assessed by degree of CD11b positivity, with lowest expression of CD11b on the IG1 and most CD11b expression on IG3. AML indicates acute myeloid leukemia; ARDS, acute respiratory distress syndrome; BALF, bronchoalveolar lavage fluid; COVID-19, coronavirus disease 2019; IG, immature neutrophils; IG1, immature granulocyte (least mature); IG1-3, CD16lo immature neutrophils; IG2, immature granulocyte (moderate maturity); IG3, immature granulocyte (most mature); MNs, mature neutrophils; SSC-A, side scatter area.

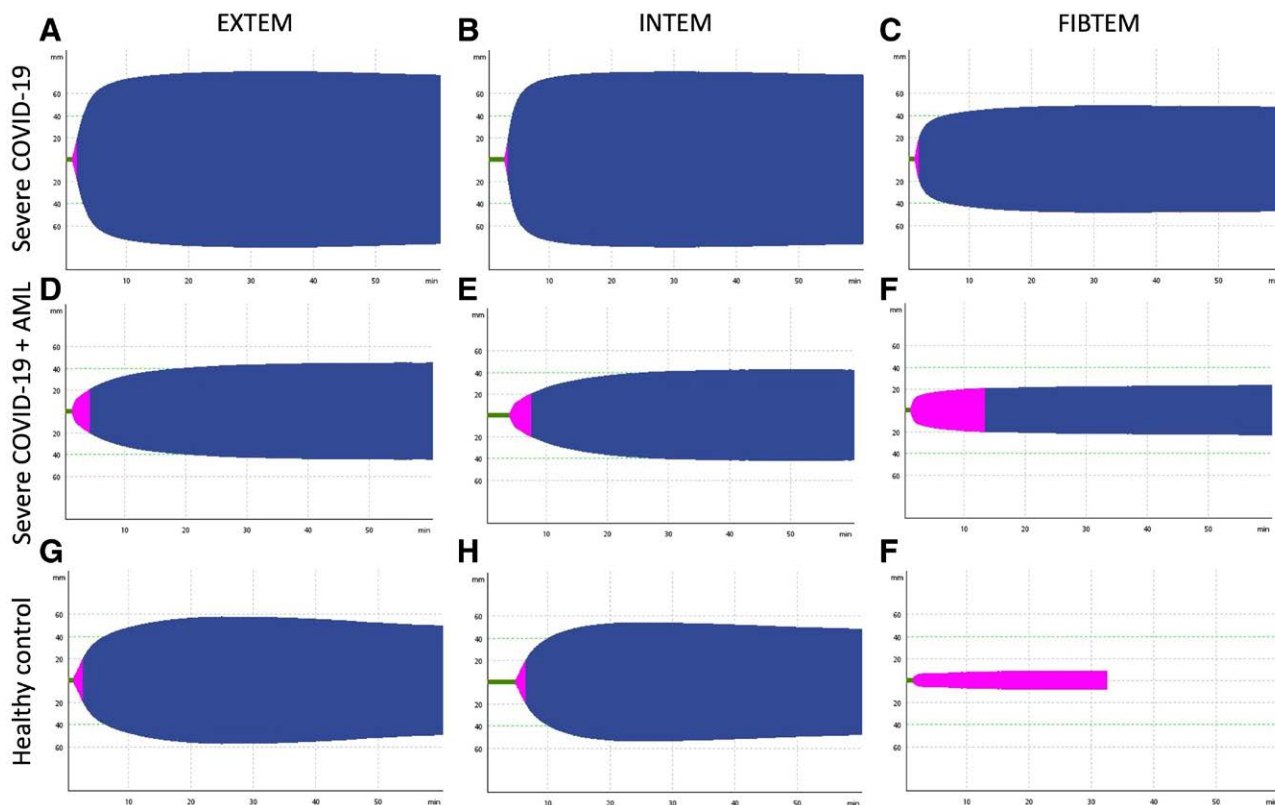
elevated clot firmness in the fibrin-based extrinsically activated test with tissue factor and the platelet inhibitor cytochalasin D (FIBTEM; Figure 2F) compared to healthy control (Figure 2I) and extended clot formation time in the extrinsically activated test with tissue factor (EXTEM) and the intrinsically activated test using ellagic acid (INTEM; Figure 2D, E), indicative of COVID-19-induced factor-driven hypercoagulability.<sup>5</sup>

## DISCUSSION

Hypercoagulopathy in COVID-19 is well described.<sup>5</sup> Despite profound thrombocytopenia, our patient had an initial leukocytosis and hyperfibrinogenemia that contributed to a prothrombotic state manifesting as a transient ischemic attack (TIA), potentially initiated by vascular endothelial inflammation associated with SARS-CoV-2 infection. ROTEM revealed elevated maximum clot firmness in FIBTEM typical of patients with severe COVID-19 (Figure 1F).<sup>6</sup> Elevated fibrinogen increases blood viscosity, which raises the risk of venous thromboembolism and other thrombotic events.<sup>7</sup> Although the patient's leukocytosis of  $22 \times 10^3/\text{mL}$  at the time of his TIA placed him at risk

for leukostasis, this elevated WBC count is still lower than the WBC count of  $30 \times 10^3/\text{mL}$  typically associated with symptomatic leukostasis. Leukemias generally increase the risk for thrombosis, but this patient's AML is not the promyelocytic M3 variety typically associated with thrombosis.<sup>8</sup> These 2 factors further indicate that COVID-induced coagulopathy contributed to this patient's TIA, while the swift resolution of his neurologic symptoms without any antithrombotic or antiplatelet therapy can be attributed to his low platelet count.

This patient had SARS-CoV-2 acute respiratory distress syndrome (ARDS) and malignancy-associated thrombocytopenia, which together contributed to alveolar hemorrhage. In contrast to other COVID-19 patients with acute lung injury, analysis of the immune cells from this patient's BAL fluid demonstrated sparse neutrophils (Figure 1E). Lung injury and ARDS in COVID-19 are largely driven by an exuberant inflammatory neutrophil response to viral infection including excessive neutrophil extracellular trap release and cytokine storm.<sup>9,10</sup> The BAL fluid from other patients requiring ventilator support for COVID-associated ARDS shows a profound predominance of neutrophils



**Figure 2.** ROTEM with EXTEM, INTEM, and FIBTEM of a patient with COVID-19 requiring mechanical ventilation, the patient with AML and COVID-19, and a healthy volunteer. A typical ROTEM tracing from a patient with severe COVID-19 alone demonstrating the hypercoagulable phenotype of severe COVID-19 with shortened clot formation time and grossly elevated clot firmness on EXTEM (A), INTEM (B), and FIBTEM (C) is provided for a swift comparison with tracings from our patient with both AML and COVID-19. The patient with both AML and COVID-19 has abnormally elevated clot firmness in FIBTEM (F), demonstrating COVID-19-induced factor-driven hypercoagulability despite profound thrombocytopenia, which explains the extended clot formation time and “normal” clot firmness in EXTEM (D) and INTEM (E). The ROTEM from a healthy subject is included for swift visual comparison of a normal EXTEM (G), INTEM (H), and FIBTEM (I) to the tracings of the patients with COVID-19. AML indicates acute myeloid leukemia; COVID-19, coronavirus disease 2019; EXTEM, extrinsically activated test with tissue factor; FIBTEM, fibrin-based extrinsically activated test with tissue factor and the platelet inhibitor cytochalasin D; INTEM, intrinsically activated test using ellagic acid; ROTEM, rotational thromboelastometry.

(Figure 1B).<sup>11</sup> Similar to the BAL fluid, this patient’s peripheral blood showed a pattern of neutropenia (Figure 1D) instead of the neutrophilia that typically characterize severe COVID-19 (Figure 1A).

This patient had remarkably low neutrophils in both blood and lungs as a result of the chemotherapy for his new AML diagnosis, increasing his risk for secondary infections, including ventilator-associated pneumonia. For this reason, several groups recommend delaying the onset or reducing chemotherapeutic dosing regimens for patients with hematologic malignancies during the COVID-19 pandemic.<sup>12,13</sup> Conversely, this patient’s neutropenia may have conferred protection from the overwhelming inflammatory granulocytic response that characterizes COVID-19 ARDS. The patient was weaned from mechanical ventilation within 3 days, markedly lower than the current average of 7 days for COVID-19 patients in our ICU, and his chest radiograph demonstrated improved aeration of both lung fields and decreased bilateral consolidative opacities. His cellular immune profile helps contextualize another case report of an infant with AML who had a remarkably mild course of COVID-19 and the observation that COVID-19 patients

with leukemia have atypical chest CT scans with less consolidation.<sup>15</sup> Despite the potentially moderating impact of AML to his clinical course, this patient also had persistent positive viral titers and remained positive via polymerase chain reaction testing at the time of writing on hospital day 35. Other groups report defective viral clearance for SARS-CoV-2 in patients with leukemias,<sup>15</sup> suggesting that an antiviral neutrophil response is needed to adequately suppress the virus.

Copresentation of these 2 diseases provides a unique window into the underlying pathology of COVID-19. AML-induced thrombopenia may have prevented worse neurologic outcome by limiting fibrinogen-driven thrombus formation but also contributed to alveolar hemorrhage that placed the patient at significant risk for ventilator-associated pneumonia. Chemotherapy-induced neutropenia may have protected the patient’s lungs from the granulocyte-driven hyperinflammation that characterizes COVID-19 ARDS but also delayed viral sequestration and enabled its ongoing propagation. In summary, this case depicts a precarious equilibrium between AML and COVID-19, and provides a perspective for potential future management strategies. ■■

## DISCLOSURES

**Name:** Lyra B. Olson, AB.

**Contribution:** This author helped conceptualize the study, collect and analyze the data, and write the paper.

**Conflicts of Interest:** None.

**Name:** Ibtehaj A. Naqvi, MD, PhD.

**Contribution:** This author helped conceptualize the study and collect and analyze the data.

**Conflicts of Interest:** None.

**Name:** Daniel J. Turner, MD.

**Contribution:** This author helped collect and analyze the data and write the paper.

**Conflicts of Interest:** None.

**Name:** Sarah A. Morrison, PhD.

**Contribution:** This author helped collect and analyze the data.

**Conflicts of Interest:** None.

**Name:** Bryan D. Kraft, MD.

**Contribution:** This author helped enable sample collection and lead coronavirus disease 2019 intensive care unit biorepository.

**Conflicts of Interest:** None.

**Name:** Lingye Chen, MD.

**Contribution:** This author helped enable sample collection and lead coronavirus disease 2019 intensive care unit biorepository.

**Conflicts of Interest:** None.

**Name:** Bruce A. Sullenger, PhD.

**Contribution:** This author helped enable sample collection and lead coronavirus disease 2019 intensive care unit biorepository.

**Conflicts of Interest:** None.

**Name:** Smita K. Nair, PhD.

**Contribution:** This author helped conceptualize the study, collect and analyze the data, enable sample collection, and lead coronavirus disease 2019 intensive care unit biorepository.

**Conflicts of Interest:** None.

**Name:** Loretta G. Que, MD.

**Contribution:** This author helped conceptualize the study, collect and analyze the data, help write the paper, enable sample collection, and lead coronavirus disease 2019 intensive care unit biorepository.

**Conflicts of Interest:** None.

**Name:** Jerrold H. Levy, MD.

**Contribution:** This author helped conceptualize the study and write the paper.

**Conflicts of Interest:** Dr Levy serves on Steering Committees for Instrumentation Labs, Merck, and Octapharma.

This manuscript was handled by: BobbieJean Sweitzer, MD, FACP.

## REFERENCES

1. Li Q, Chen L, Li Q, et al. Cancer increases risk of in-hospital death from COVID-19 in persons <65 years and those not in complete remission. *Leukemia*. 2020;34:2384–2391.
2. Sanchez-Pina JM, Rodriguez MR, Quismondo NC, et al. Clinical course and risk factors for mortality from COVID-19 in patients with haematological malignancies. *Eur J Haematol*. 2020;105:597–607.
3. Núñez-Torrón C, García-Gutiérrez V, Tenorio-Núñez MC, Moreno-Jiménez G, López-Jiménez FJ, Herrera-Puente P. Poor outcome in patients with acute leukemia on intensive chemotherapy and COVID-19. *Bone Marrow Transplant*. 2021;56:267–269.
4. Liu Y, Du X, Chen J, et al. Neutrophil-to-lymphocyte ratio as an independent risk factor for mortality in hospitalized patients with COVID-19. *J Infect*. 2020;81:e6–e12.
5. Connors JM, Levy JH. COVID-19 and its implications for thrombosis and anticoagulation. *Blood*. 2020;135:2033–2040.
6. Pavoni V, Ganesello L, Pazzi M, Stera C, Meconi T, Frigieri FC. Evaluation of coagulation function by rotation thromboelastometry in critically ill patients with severe COVID-19 pneumonia. *J Thromb Thrombolysis*. 2020;50:281–286.
7. Walton BL, Byrnes JR, Wolberg AS. Fibrinogen, red blood cells, and factor XIII in venous thrombosis. *J Thromb Haemost*. 2015;13(suppl 1):S208–S215.
8. De Stefano V, Sorà F, Rossi E, et al. The risk of thrombosis in patients with acute leukemia: occurrence of thrombosis at diagnosis and during treatment. *J Thromb Haemost*. 2005;3:1985–1992.
9. Narasaraju T, Tang BM, Herrmann M, Muller S, Chow VTK, Radic M. Neutrophilia and NETopathy as key pathologic drivers of progressive lung impairment in patients with COVID-19. *Front Pharmacol*. 2020;11:870.
10. Zuo Y, Yalavarthi S, Shi H, et al. Neutrophil extracellular traps in COVID-19. *JCI Insight*. 2020;5:e128999.
11. Liao M, Liu Y, Yuan J, et al. Single-cell landscape of bronchoalveolar immune cells in patients with COVID-19. *Nat Med*. 2020;26:842–844.
12. Raza A, Assal A, Ali AM, Jurcic JG. Rewriting the rules for care of MDS and AML patients in the time of COVID-19. *Leuk Res Rep*. 2020;13:100201.
13. Paul S, Rausch CR, Jain N, et al. Treating leukemia in the time of COVID-19. *Acta Haematologica*. 2020;11:1–13.
14. Sieni E, Pegoraro F, Casini T, et al. Favourable outcome of coronavirus disease 2019 in a 1-year-old girl with acute myeloid leukaemia and severe treatment-induced immunosuppression. *Br J Haematol*. 2020;189:e222–e224.
15. Zhou X, Wang G, Chen L, et al. Clinical characteristics of hematological patients concomitant with COVID-19. *Cancer Sci*. 2020;111:3379–3385.